

# **Anatomy of the Eye and Ear: Lesson Plan**

## **Resources**

Required resources for students:

- Visible Body Suite
- Lab activity worksheet

Additional resources for students and teachers:

- This lesson assumes that students have a basic understanding of the eye and the ear. They can read the first two articles on this page for an introduction to the main functions:  
<https://www.visiblebody.com/learn/nervous/five-senses>

## **Objectives**

At the end of this lesson, students should be able to:

1. Describe the key structures present in each of the three layers of the eye.
2. Describe the key structures in the outer ear, middle ear, and inner ear.
3. Discuss the main functions of these structures.

In their answers, students will name the following structures of the eye: Sclera, cornea, choroid, ciliary body, iris, lens, retina, photoreceptors, rod cells, cone cells, optic nerve, eyelid, lacrimal gland, lacrimal sac, lateral rectus, superior rectus, inferior oblique, inferior rectus, and medial rectus.

In their answers, students will name the following structures of the ear: Outer ear, auricle, external acoustic meatus, tympanic membrane, middle ear, malleus, incus, stapes, oval window, inner ear, semicircular canals, vestibule, and cochlea.

## **Introduction**

10 minutes: Use Visible Body Suite, as well as the articles referenced in the additional resources above, to give students a brief introduction to the basic structures of the eye and the ear. Distinguish between the three different layers of the eye and explain how light is translated into nerve impulses in the retina with the help of photoreceptors (rod and cone cells). Review the key structures and functions of the outer ear, middle ear, and inner ear.

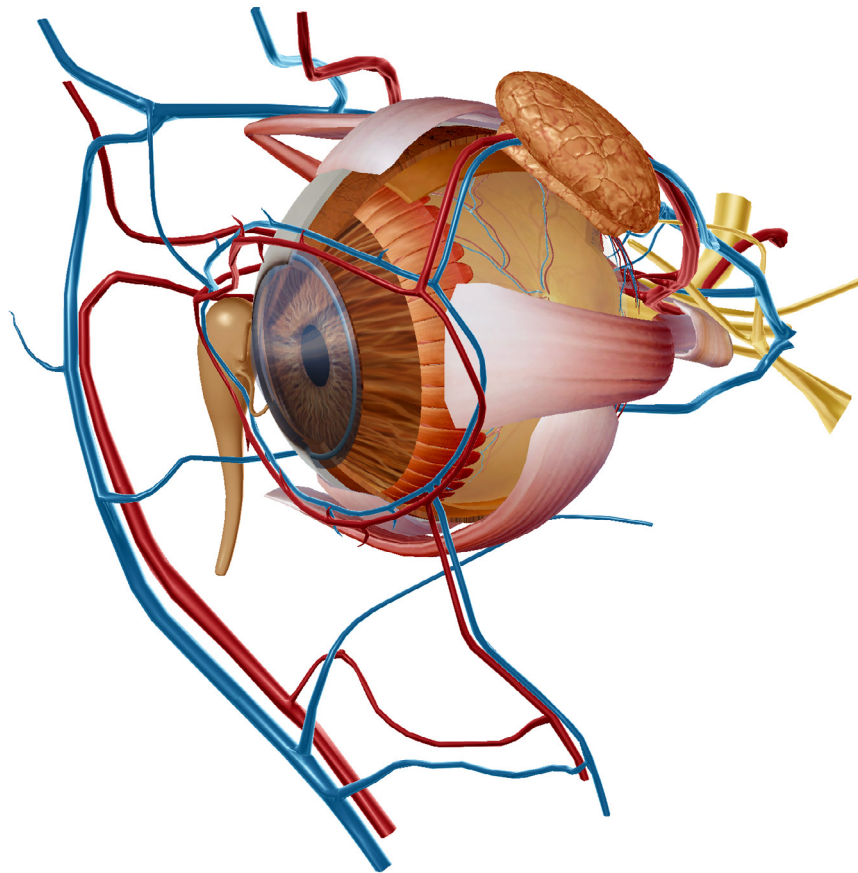
## **Student Activities**

30 minutes: Have your students complete the four activity worksheets in this lesson. Check their work using the answer key.

If you're doing this activity in class, you can use these four images to create stations.

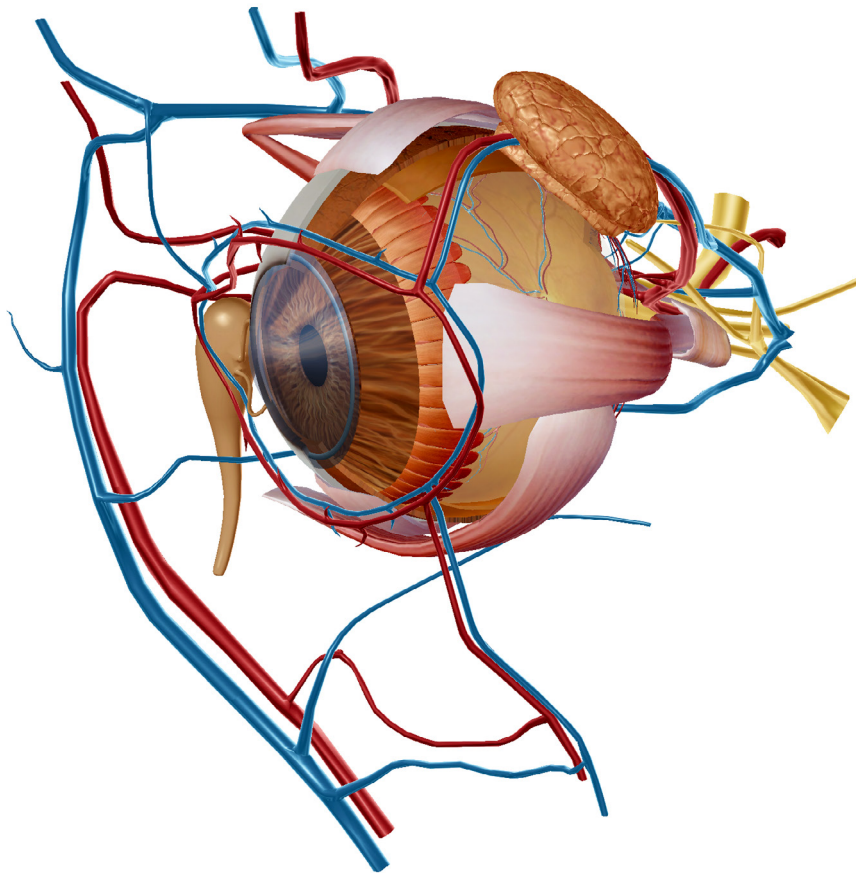


**Activity 1: Anatomy of the Eye and Ear Lab**





**Activity 2: Anatomy of the Eye and Ear Lab**





**Activity 3: Anatomy of the Eye and Ear Lab**





**Activity 4: Anatomy of the Eye and Ear Lab**

