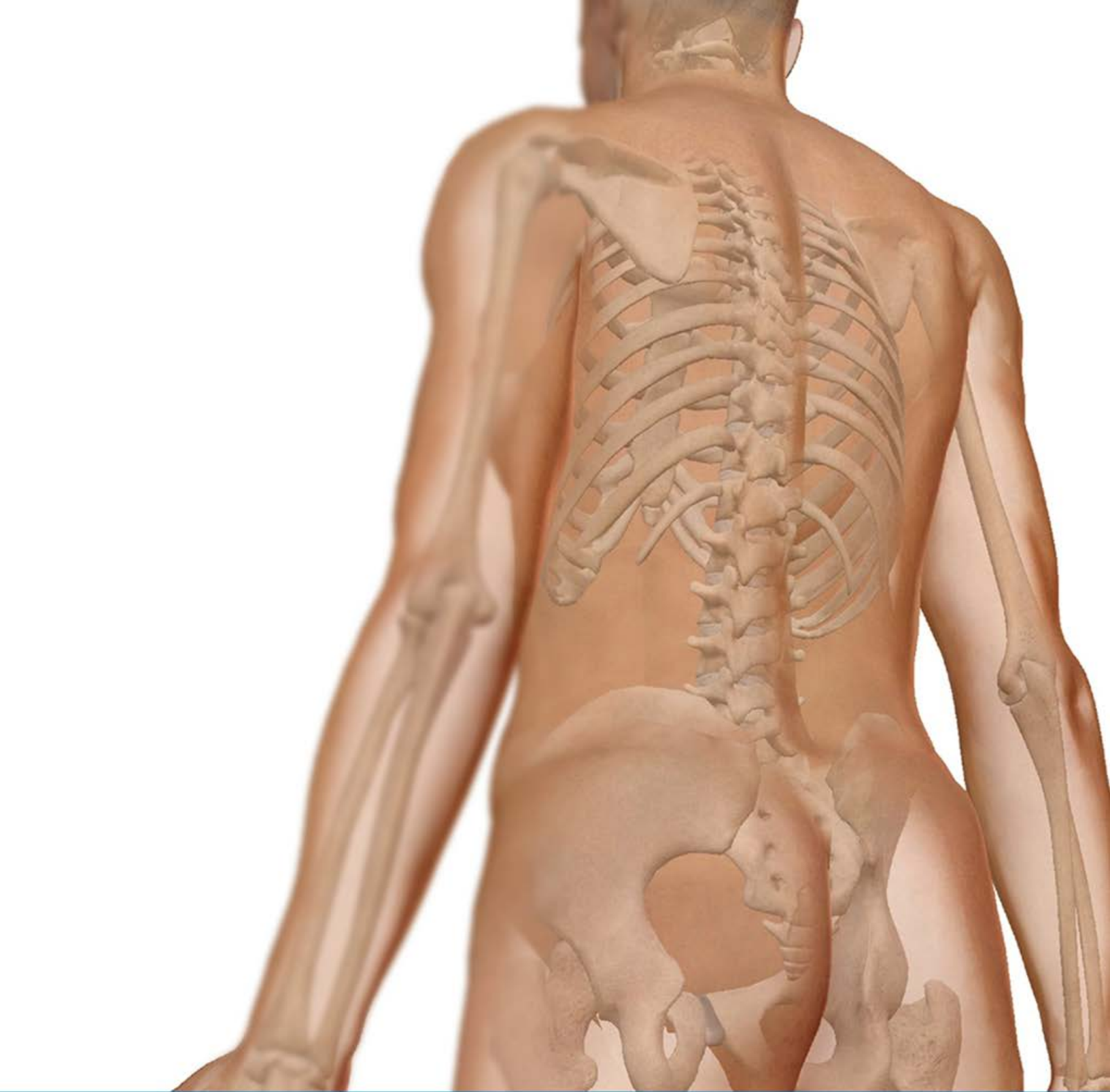

VISIBLE  BODY®

The Appendicular Skeleton

A skeletal system lab activity using Visible Body Suite

Stephanie Wallace, Instructor of Biology, TCU

PRE-LAB EXERCISES

When studying the skeletal system, the bones are often sorted into two broad categories: the axial skeleton and the appendicular skeleton. This lab focuses on the appendicular skeleton, which is formed from the pectoral and pelvic girdles and the upper and lower limbs.

In addition to learning about all the bones of the appendicular skeleton, it is also important to identify some significant bone markings. Bone markings can have many shapes, including holes, round or sharp projections, and shallow or deep valleys, among others. These markings on the bones serve many purposes, including forming attachments to other bones or muscles and allowing passage of a blood vessel or nerve. It is helpful to understand the meanings of some of the more common bone marking terms.

Before we get started, look up the definitions of these common bone marking terms:

Canal:

Condyle:

Facet:

Fissure:

Foramen:

Fossa:

Margin:

Process:

Proximal:

Trochanter:

Tubercle:

Tuberosity:

Throughout this exercise, you will notice bold terms. This is meant to focus your attention on these important words. Make sure you pay attention to any bold words and know how to explain their definitions and/or where they are located.

Use the following modules to guide your exploration of the appendicular skeleton. As you explore these bones in Visible Body's app, also locate the bones and bone markings on any available charts, models, or specimens. You may also find it helpful to palpate bones on yourself or make drawings of the bones with the bone markings labeled. The drawings don't have to be perfect; just make sure the different bone markings are in the correct locations, relative to each other.

If you have trouble finding a bone or bone marking, you can always type its name into the search bar to get a list of 3D anatomical views where that bone or bone marking is highlighted for you.

To access disarticulated bones with color-coded bone markings, select a bone, and then, in the content box, choose the landmark icon, which shows a bone with pink, yellow, and blue ends.

IN-LAB EXERCISES

Open Visible Body Suite. Search for and select each of the Skeletal System Views noted in the exercises below.

You are responsible for the identification of **all bold terms**.

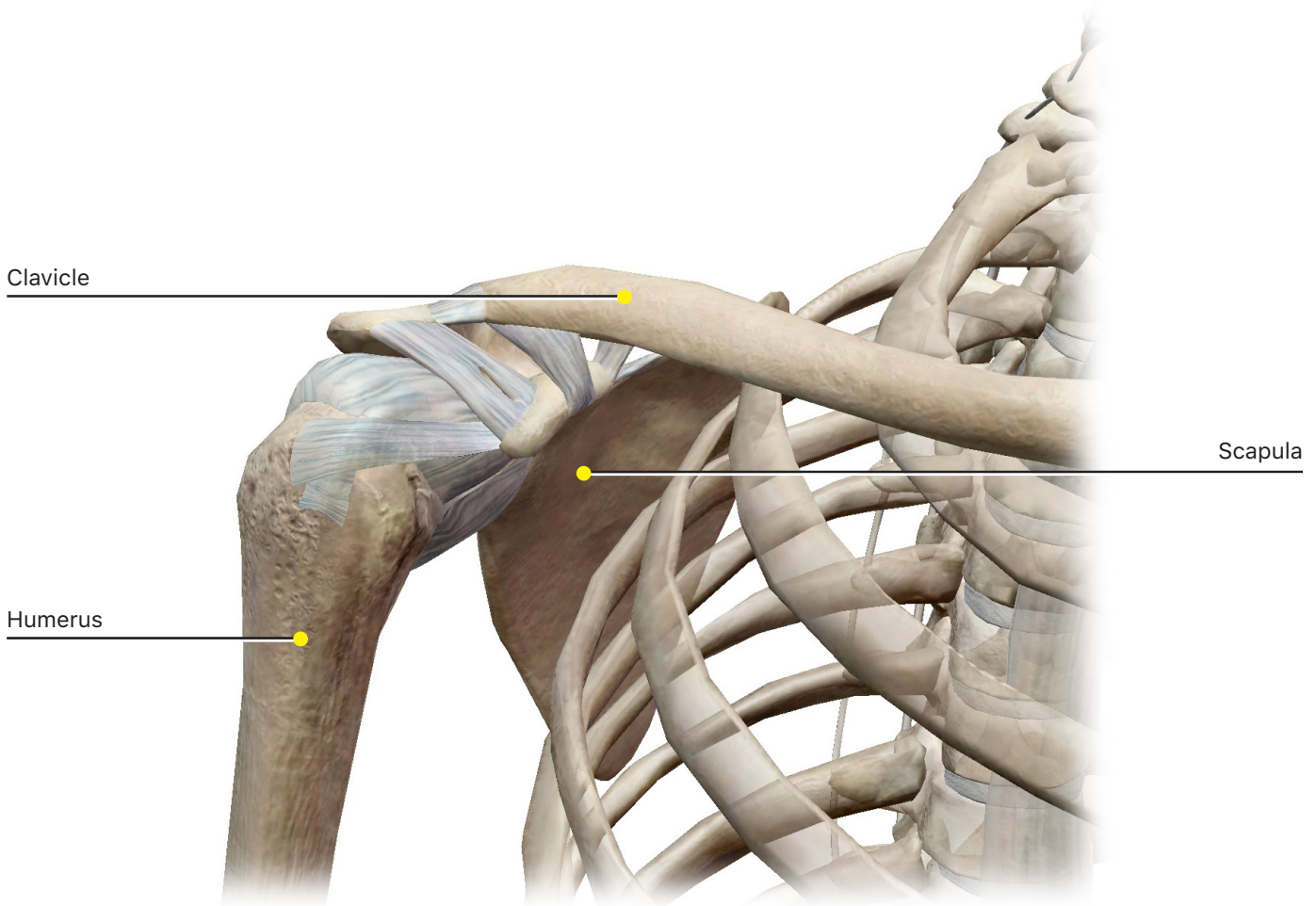
A. Pectoral Girdle

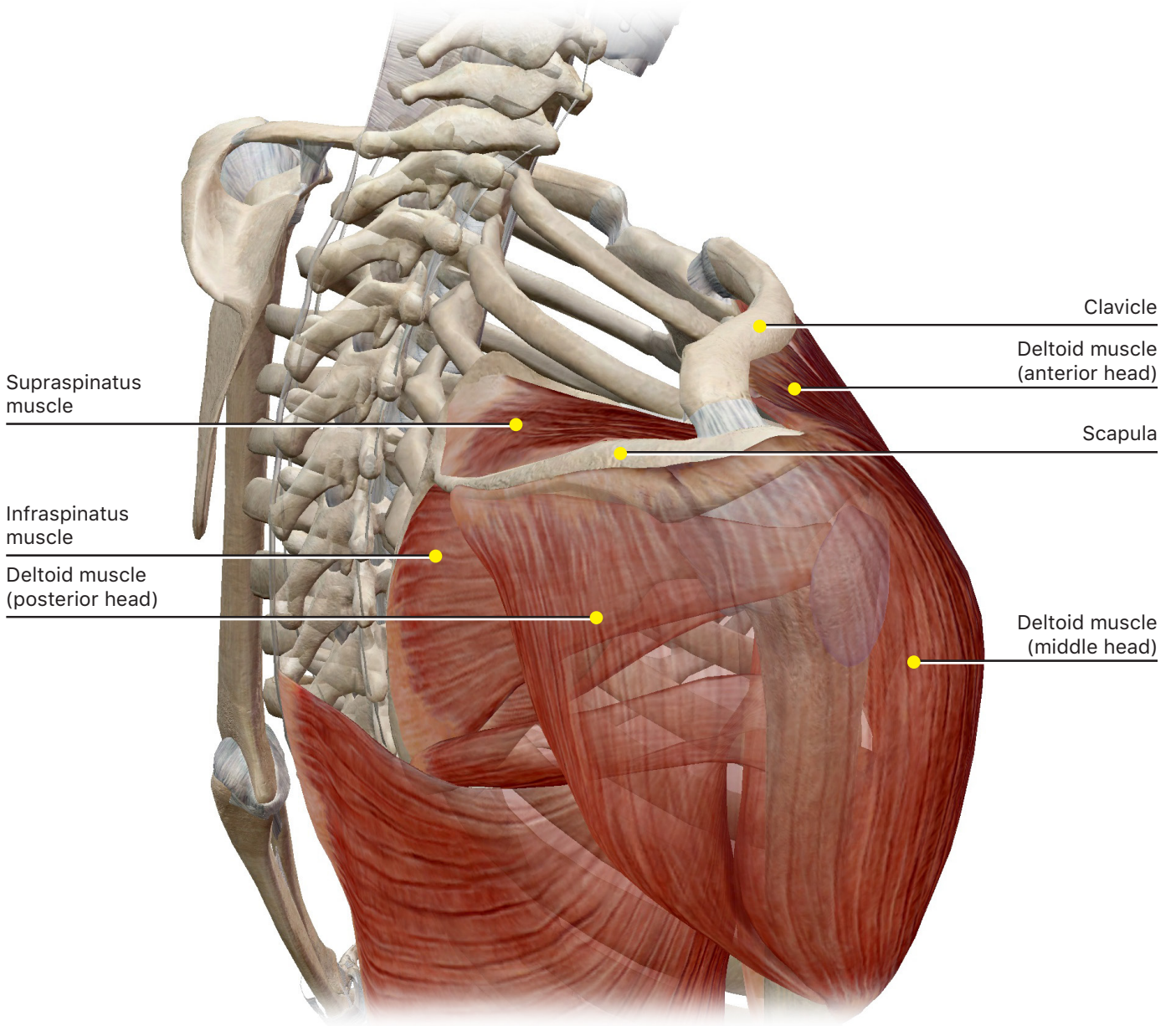
Open the Skeletal System View "Shoulder Girdle" to identify the clavicles and scapulae.

The **clavicles** and **scapulae** make up the pectoral girdle and are responsible for attaching the upper limbs to the skeleton as well as providing attachment points for the shoulder muscles.

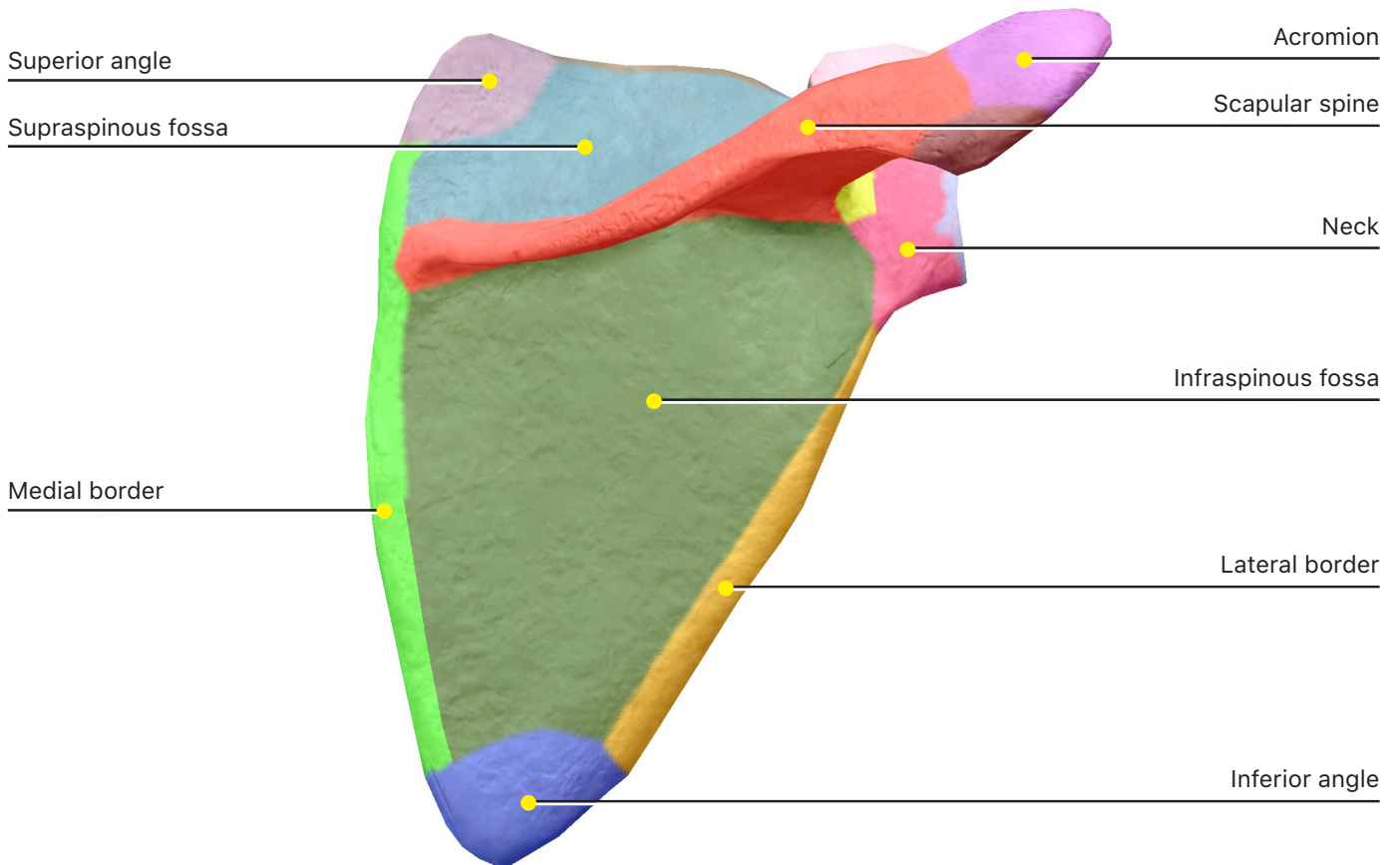
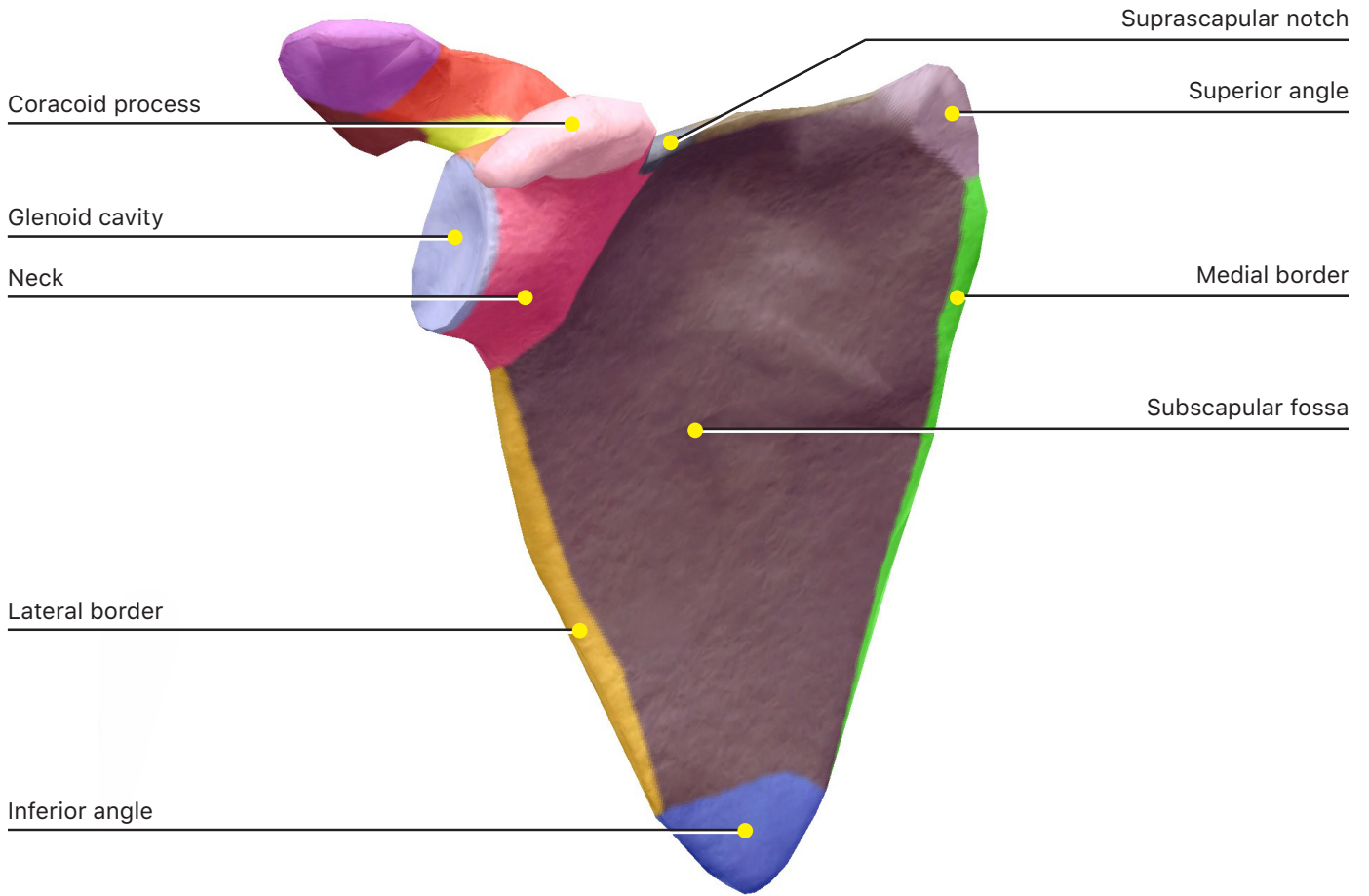
Open the Skeletal System View "Axillary Region" to observe how muscles attach to the clavicles and scapulae.

You can select the systems icons on the left side of the screen to hide blood vessels, lymphatic vessels, and nerves. The shoulder has the largest range of motion of any joint in the body, and the many muscles that attach here stabilize the pectoral girdle to allow for that movement. After identifying the bones and how they function in muscle stabilization, find their bone markings and answer the questions.





1. Scapula



a. Identify the following bone markings:

i. **Glenoid cavity**

ii. **Spine**

iii. **Acromion**

iv. **Coracoid process**

v. **Infraspinous fossa**

vi. **Supraspinous fossa**

vii. **Subscapular fossa**

viii. **Inferior angle**

ix. **Superior angle**

x. **Lateral border**

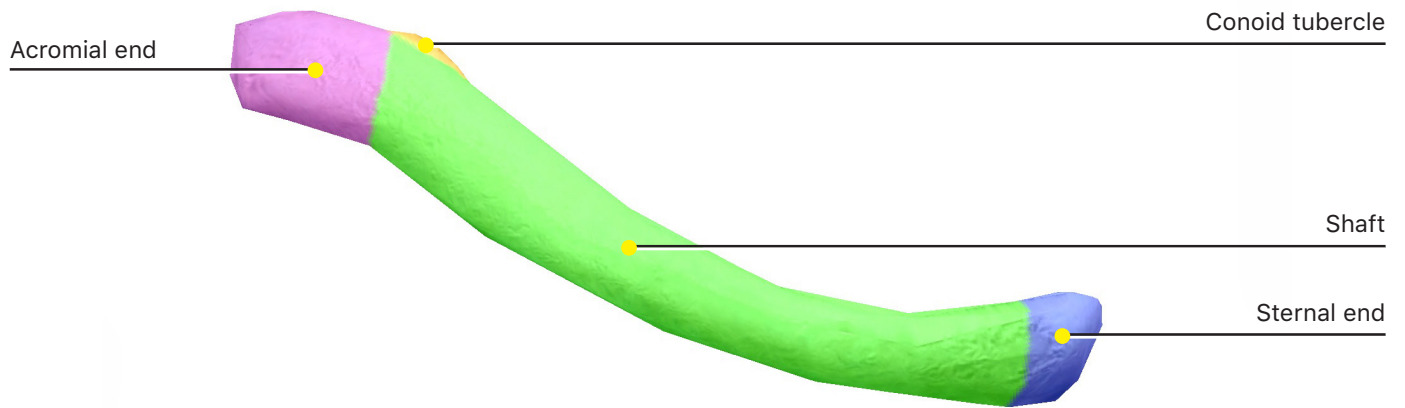
xi. **Medial border**

xii. **Neck**

xiii. **Acromial angle**

b. Describe how to determine a right scapula from a left scapula.

2. Clavicle



a. Identify the following bone markings:

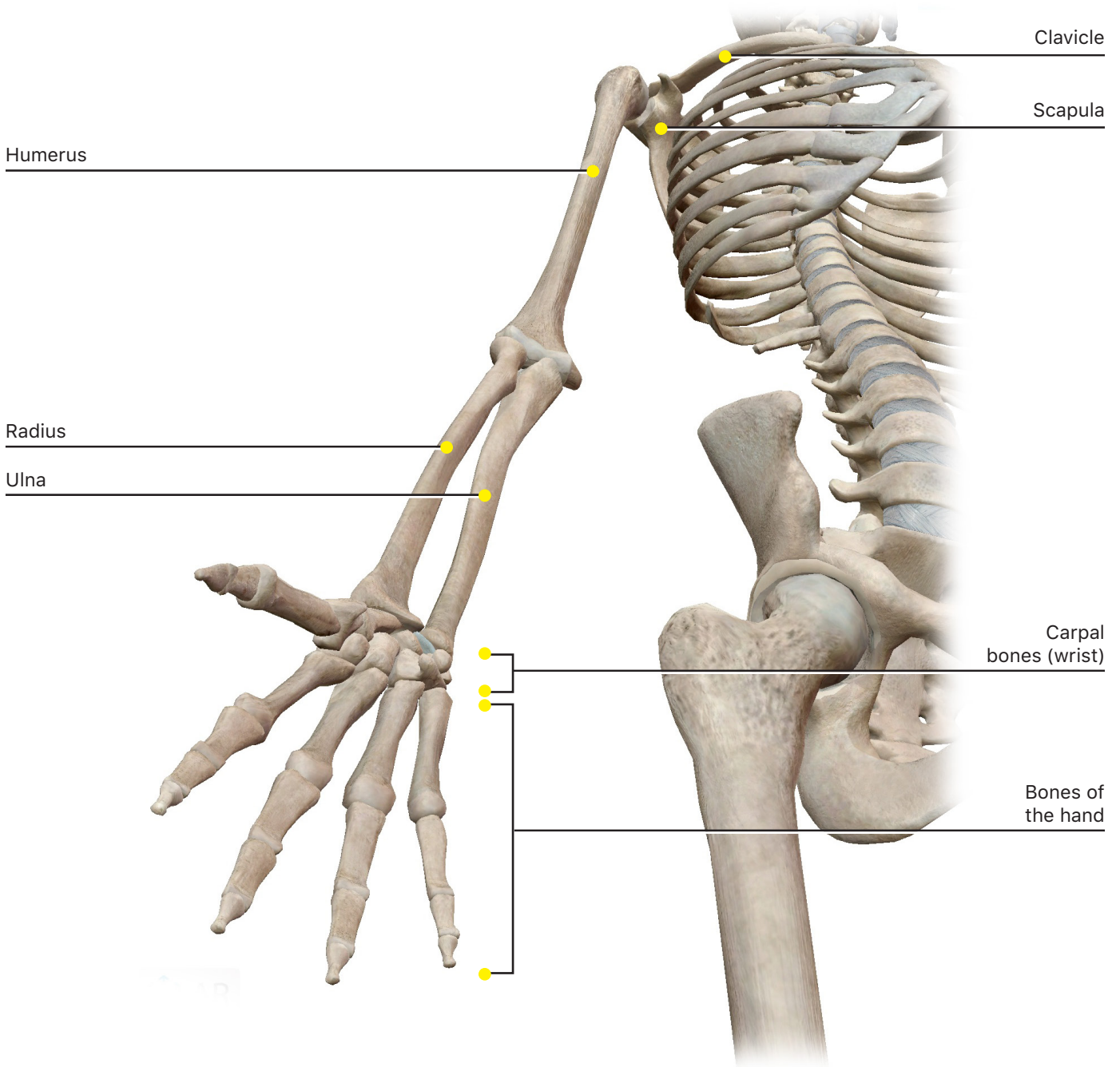
- i. **Acromial end**
- ii. **Sternal end**
- iii. **Shaft**
- iv. **Conoid tubercle**

b. Describe how the clavicle curves and articulates with other bones.

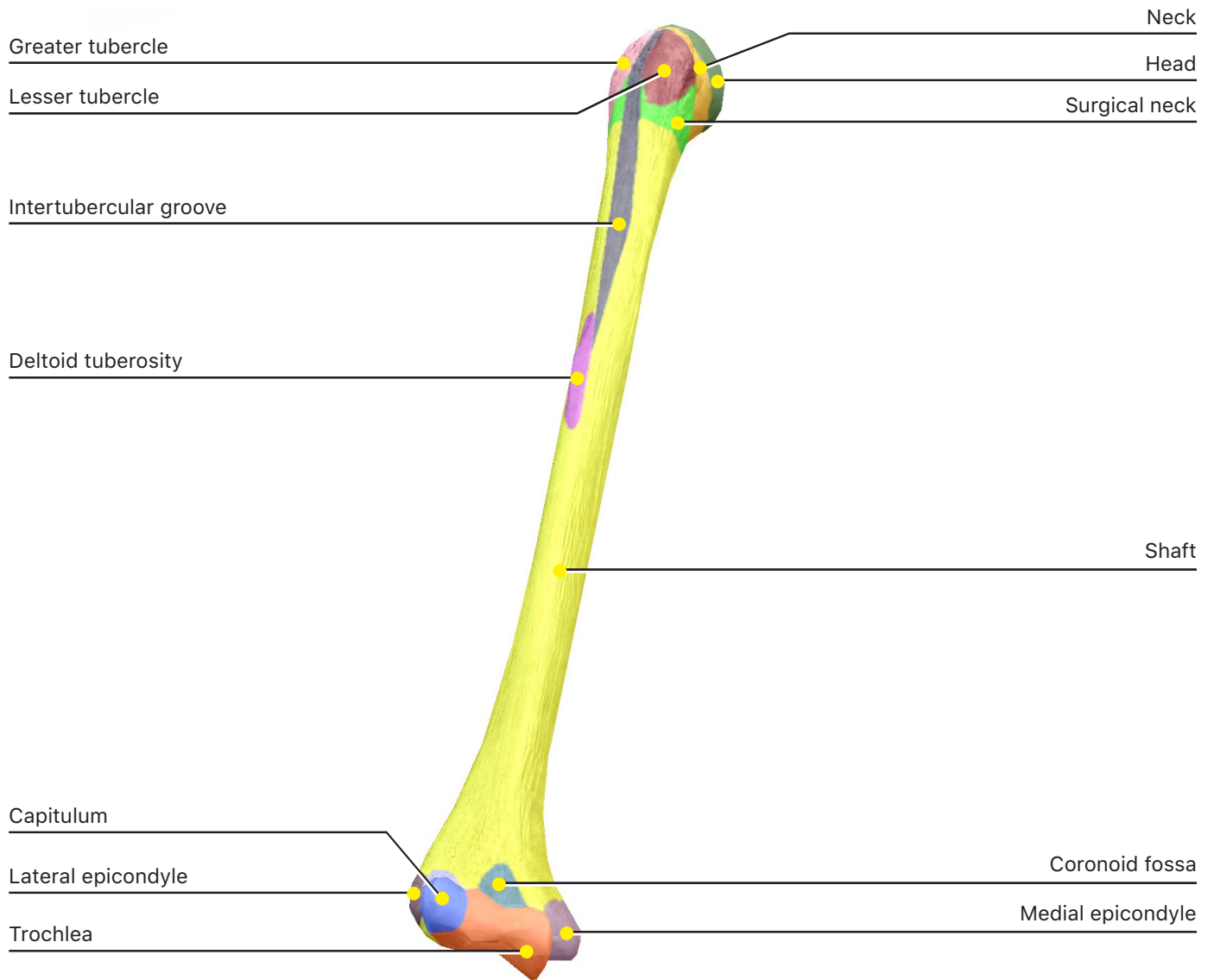
B. Upper Limb

Open the Skeletal System View "Full Skeleton" to identify the bones of the upper limb.

The upper limb consists of the bones of the arm, forearm, wrist, and hand. Zoom in on the arm and identify the following bones and bone markings, and then zoom out again to look at the full arm and observe how the individual bones fit together. Note how processes often fit into the fossae of the same name.



1. Humerus



a. Identify the following bone markings:

- i. **Head**
- ii. **Anatomical neck**
- iii. **Surgical neck**
- iv. **Shaft**
- v. **Greater tubercle**
- vi. **Lesser tubercle**

vii. **Intertubercular groove**

viii. **Radial groove**

ix. **Deltoid tuberosity**

x. **Trochlea**

xi. **Capitulum**

xii. **Coronoid fossa**

xiii. **Olecranon fossa**

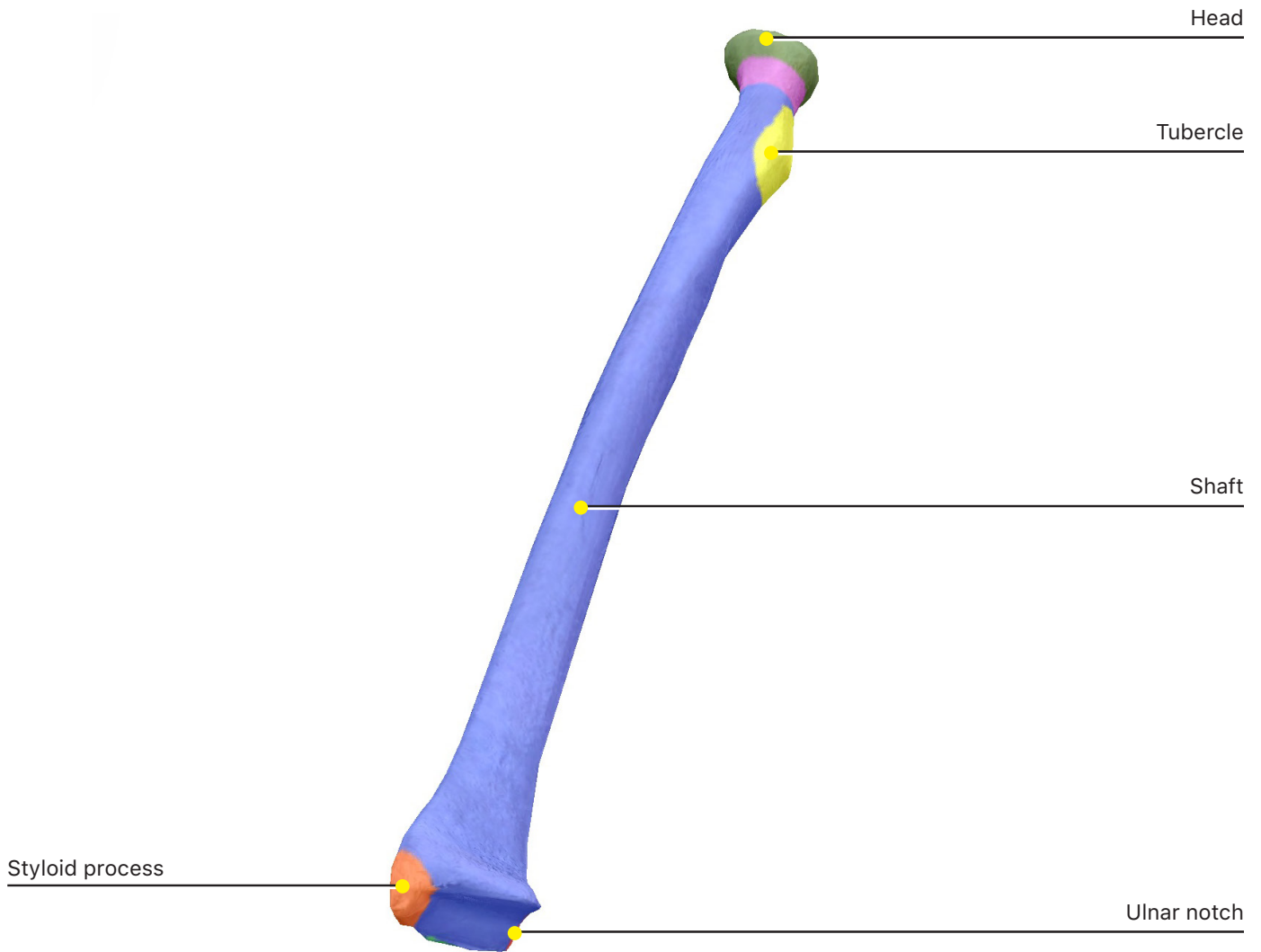
xiv. **Medial epicondyle**

xv. **Lateral epicondyle**

xvi. **Radial fossa**

b. Describe the difference in position of the anatomical neck and the surgical neck.

2. Radius



a. Identify the following bone markings:

i. **Head**

ii. **Neck**

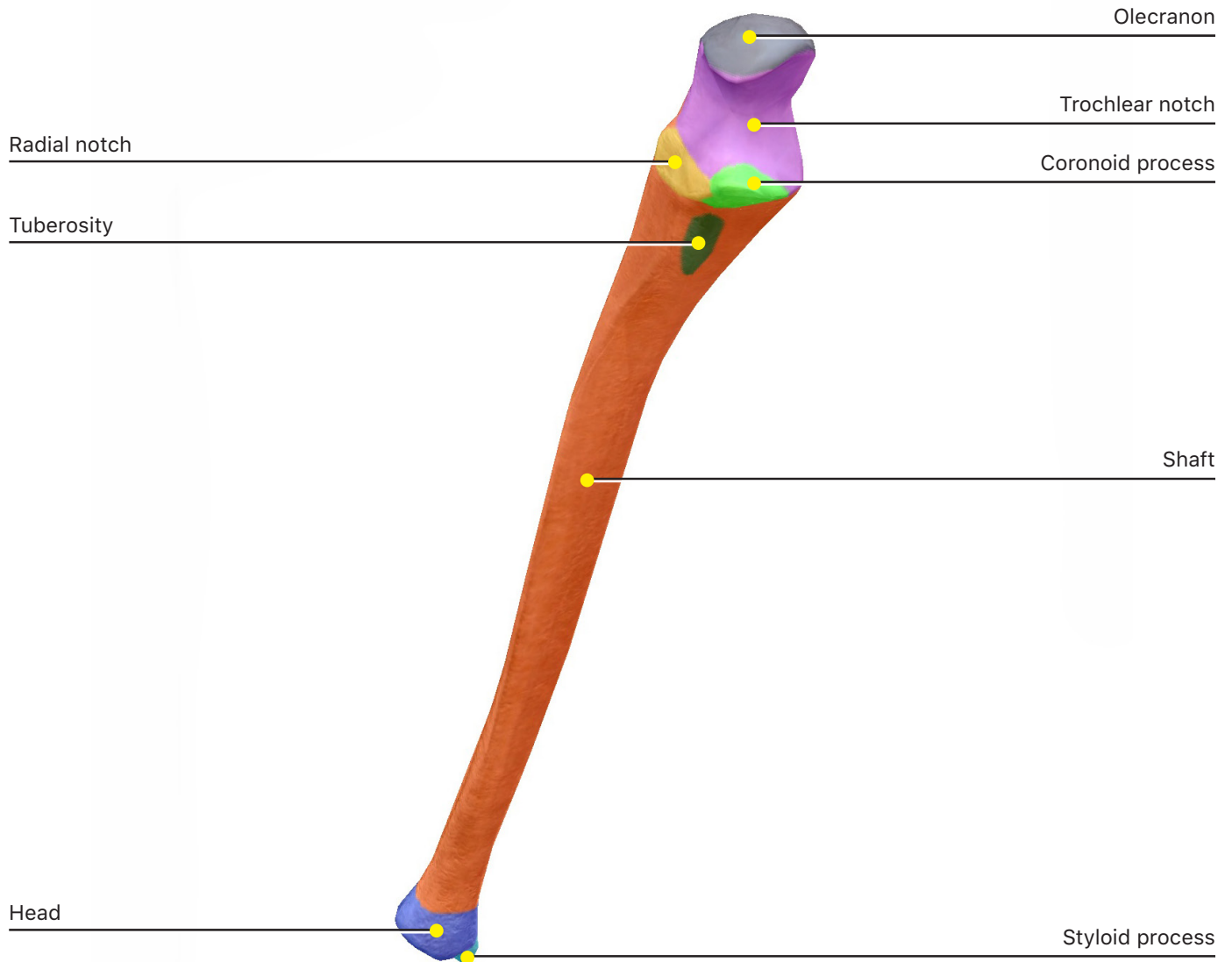
iii. **Shaft**

iv. **Tubercle**

v. **Styloid process**

vi. **Ulnar notch**

3. Ulna



a. Identify the following bone markings:

i. **Coronoid process**

ii. **Olecranon**

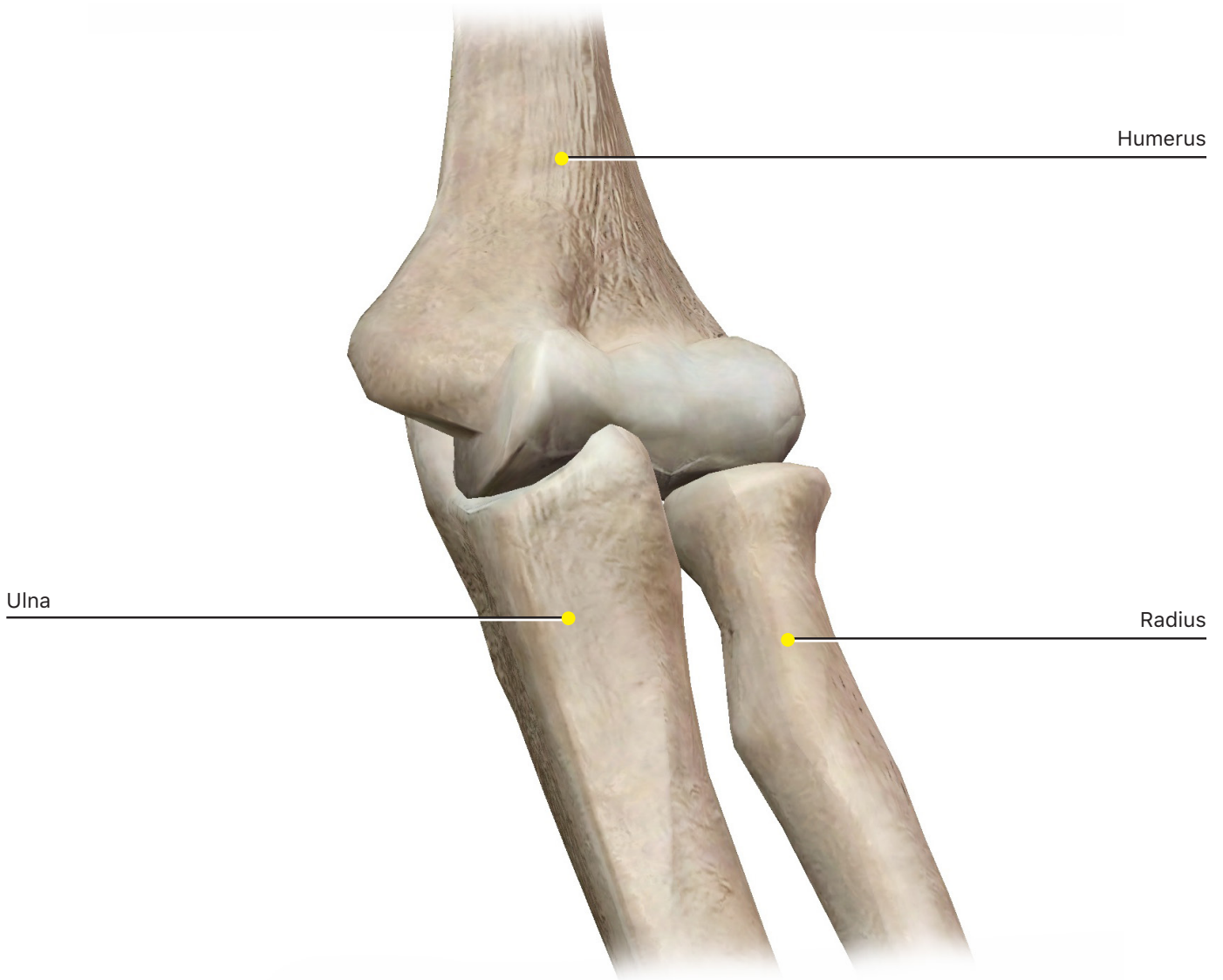
iii. **Radial notch**

iv. **Trochlear notch**

v. **Styloid process**

vi. **Head**

vii. **Shaft**



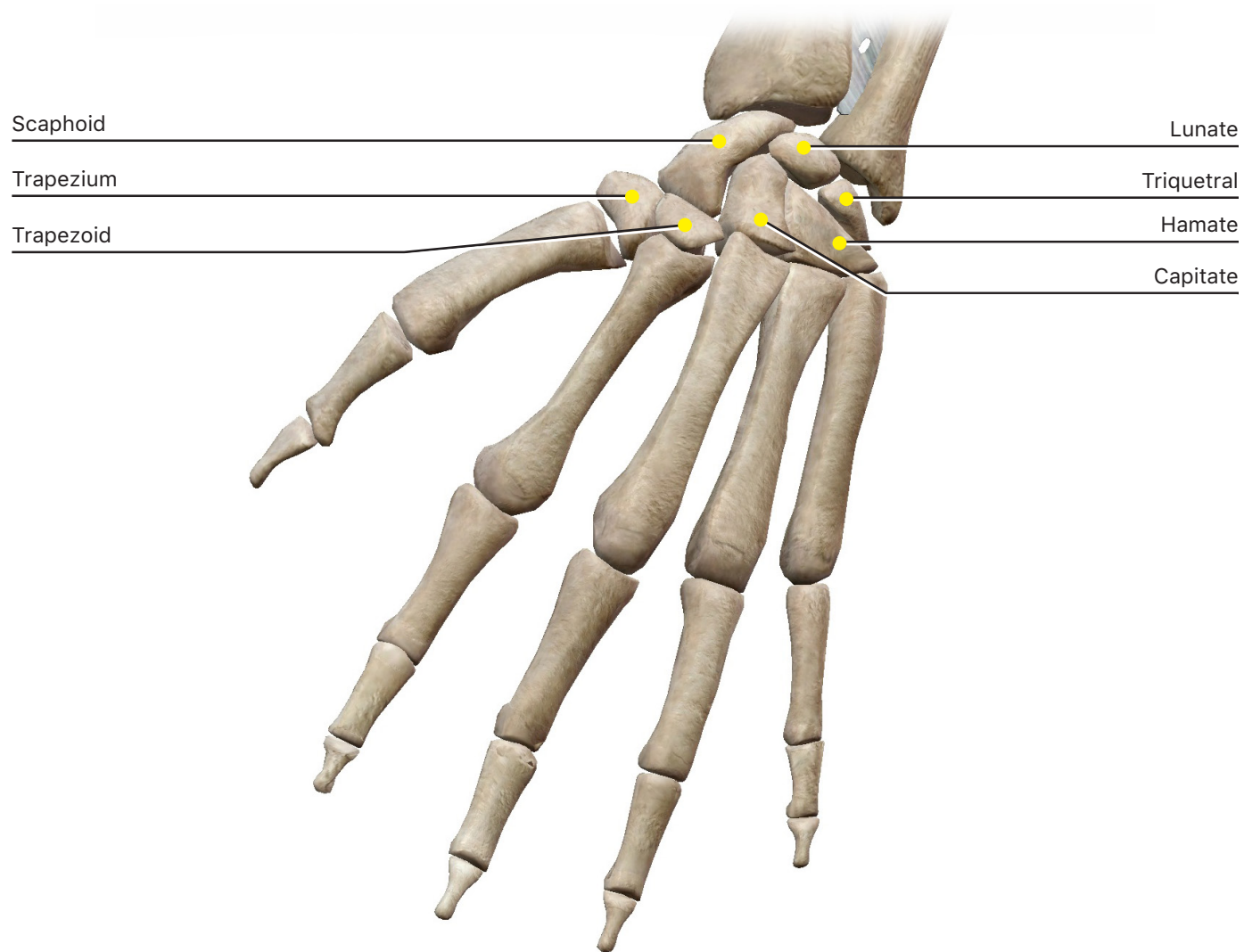
b. How do the bones of the radius and ulna attach to each other?

c. Describe how the radius and ulna attach to and rotate around the humerus when the elbow flexes.

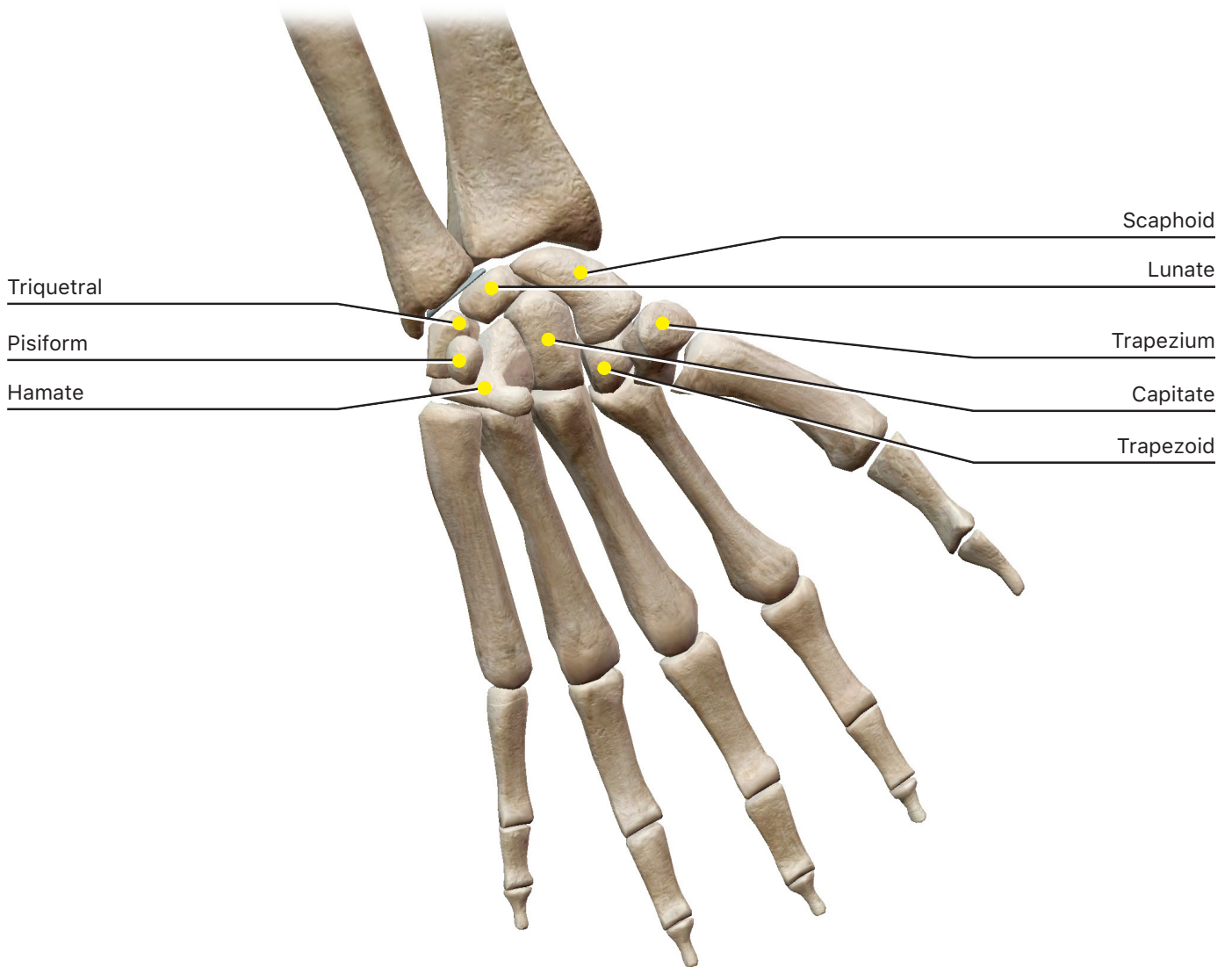
4. Carpus

To see the carpals more clearly, hide some or all of the ligaments on the wrist after you zoom in.

Carpus (Posterior)



Carpus (Anterior)

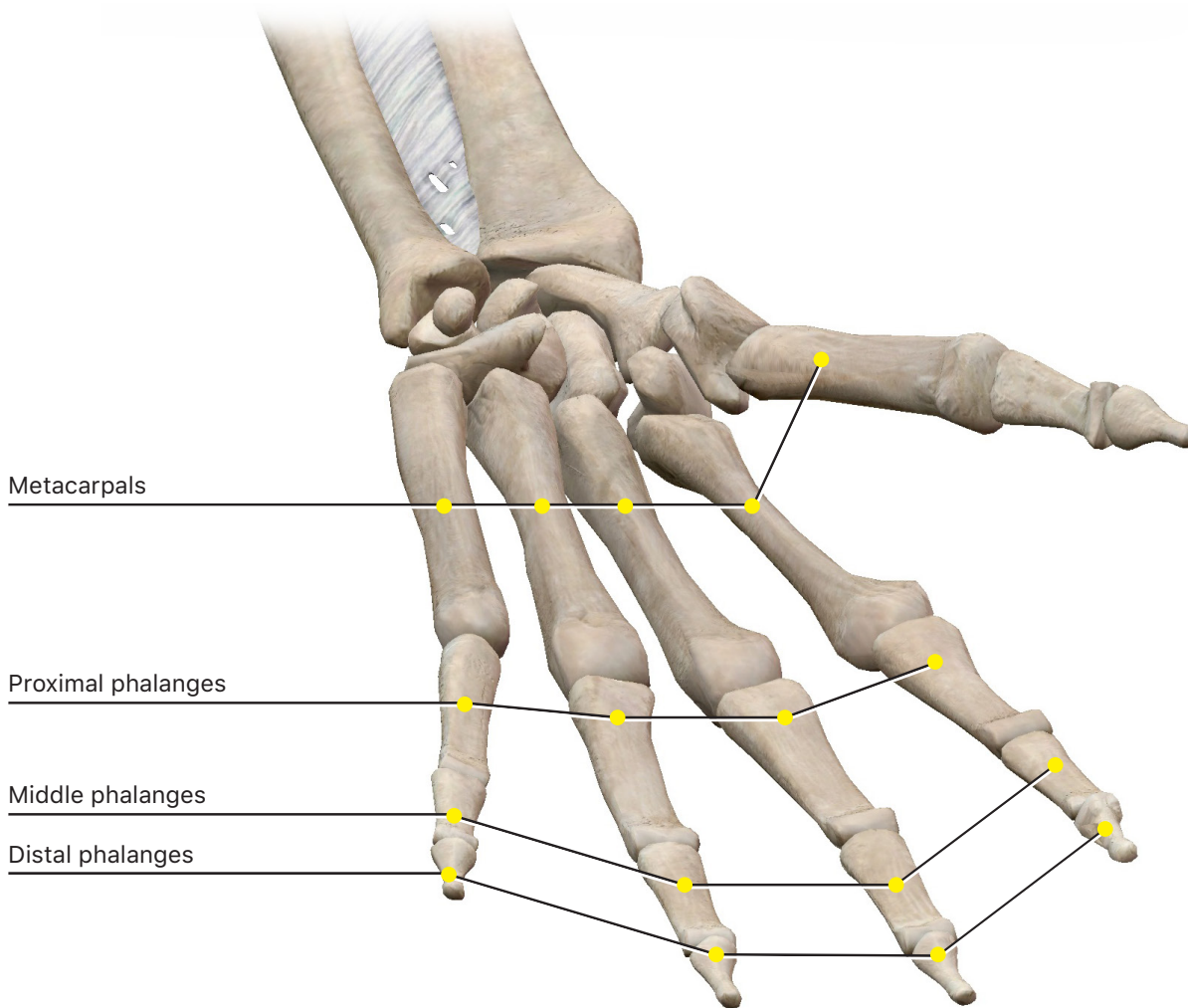


a. Identify the following carpal bones:

- i. **Lunate**
- ii. **Scaphoid**
- iii. **Trapezium**
- iv. **Trapezoid**
- v. **Capitate**
- vi. **Hamate**
- vii. **Triquetral**
- viii. **Pisiform**

5. Hand

Note the nomenclature for the bones of the hand. The thumb is considered digit I, while the pinky finger is digit V. The metacarpals and phalanges are numbered accordingly.



a. Identify the following hand bones:

i. **Metacarpals**

ii. **Proximal phalanges**

iii. **Middle phalanges**

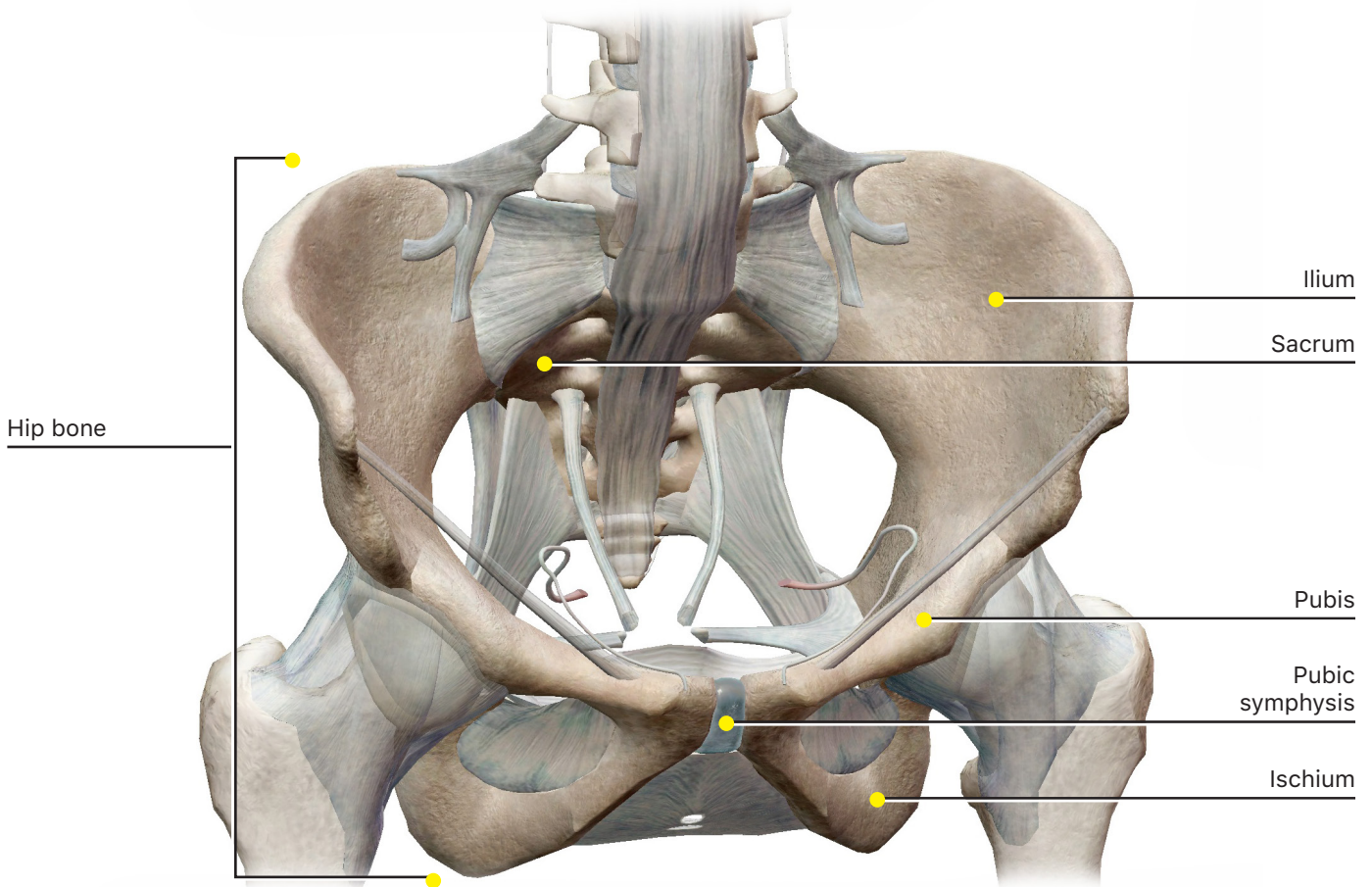
iv. **Distal phalanges**

b. List all the bones on your thumb from proximal to distal. Do the same for your pinky finger. What is the difference?

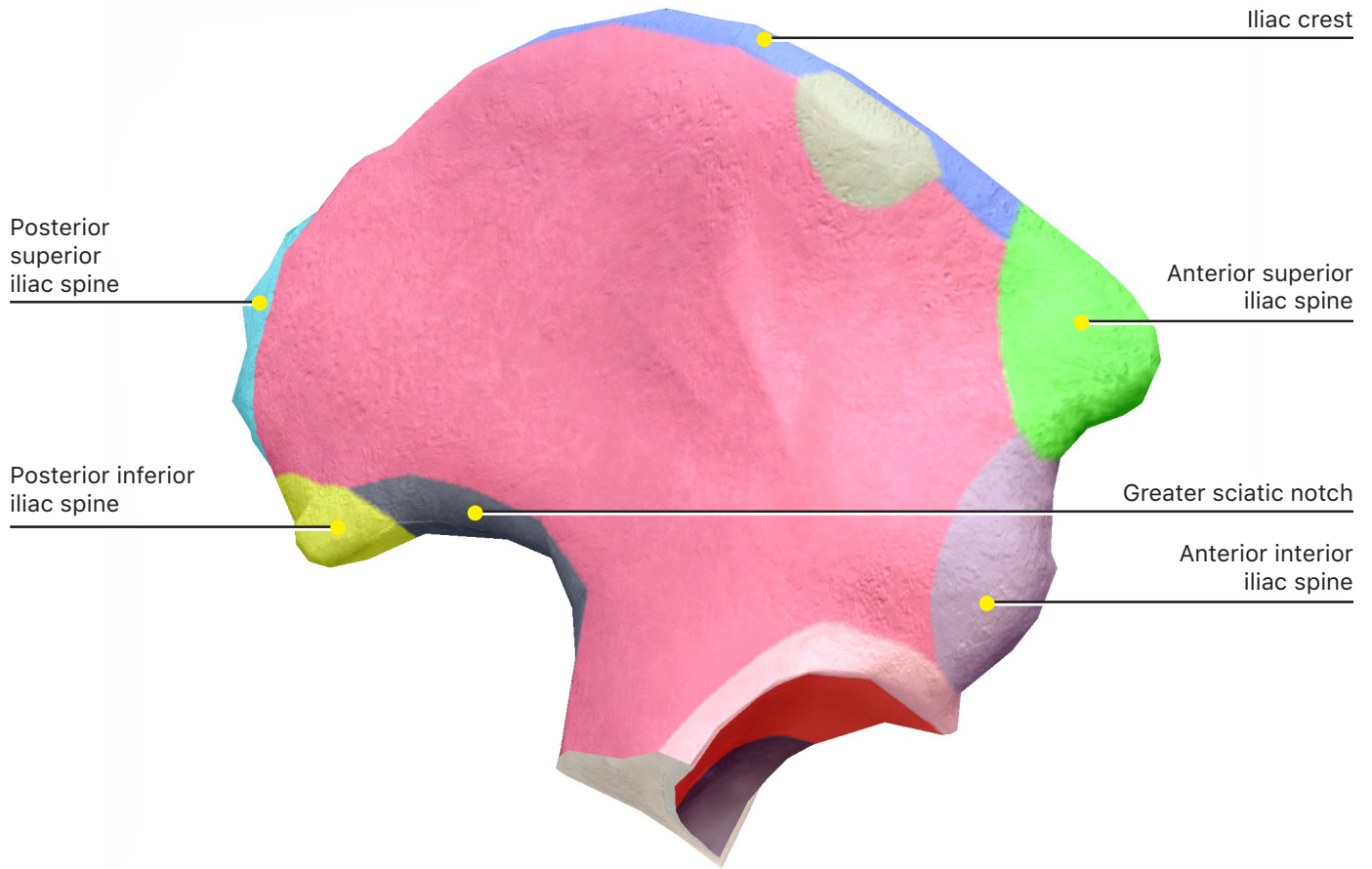
C. Pelvic Girdle

Open the Skeletal System View "Pelvic Girdle" to identify the ilium, ischium, and pubis.

Just like the pectoral girdle attaches the upper limbs to the skeleton, the pelvic girdle attaches the lower limbs to the skeleton. The pelvic girdle consists of the right and left **hip bones** and the **sacrum** that connects the hip bones on the posterior side. You may remember the sacrum from studying the axial skeleton, because it is part of the vertebral column. Each of the hip bones begins as three separate bones: the **ilium**, **ischium**, and **pubis**. These bones eventually fuse together, but bone markings are still considered to belong to one of these three distinct regions. Observe the following bone markings on the ilium, ischium, and pubis, and then try to find the same bone markings on the entire hip bone.



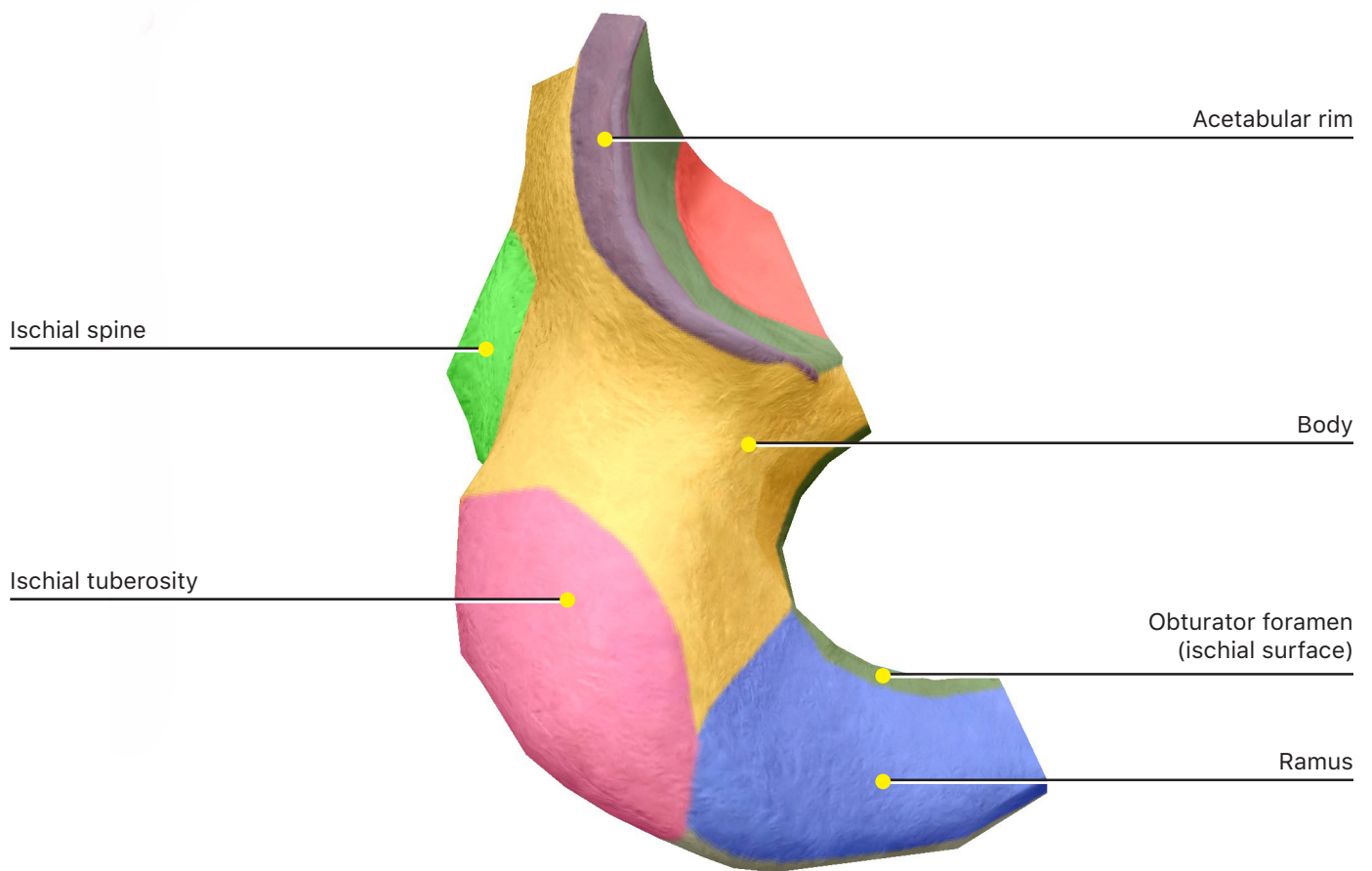
1. Ilium



a. Identify the following bone markings:

- i. **Body**
- ii. **Iliac crest**
- iii. **Iliac fossa**
- iv. **Acetabulum**
- v. **Anterior inferior iliac spine**
- vi. **Anterior superior iliac spine**
- vii. **Posterior inferior iliac spine**
- viii. **Posterior superior iliac spine**
- ix. **Auricular surface**
- x. **Greater sciatic notch**

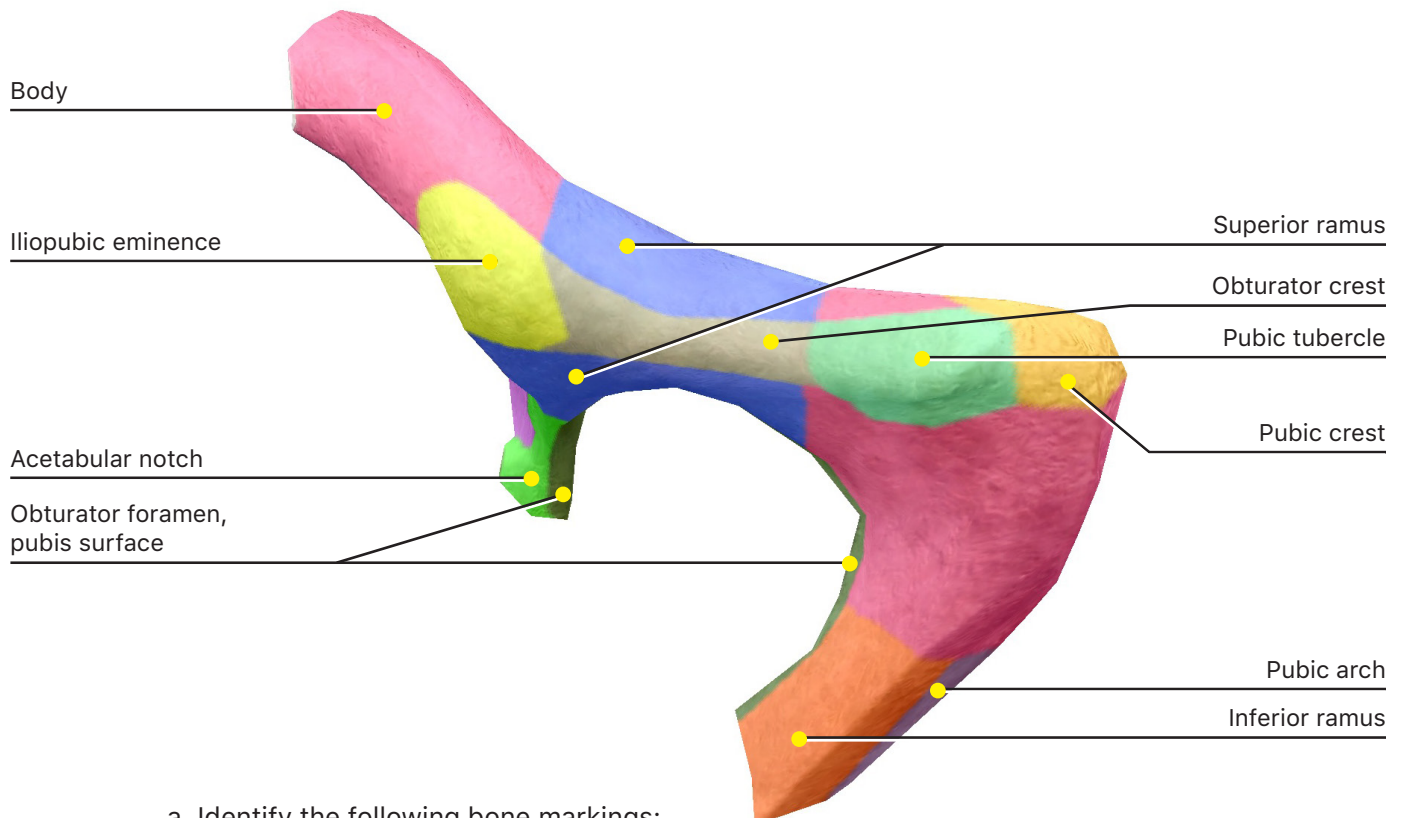
2. Ischium



a. Identify the following bone markings:

- i. **Body**
- ii. **Ramus**
- iii. **Acetabulum**
- iv. **Lesser sciatic notch**
- v. **Ischial tuberosity**
- vi. **Ischial spine**
- vii. **Pubic arch**
- viii. **Obturator foramen (ischial surface)**

3. Pubis



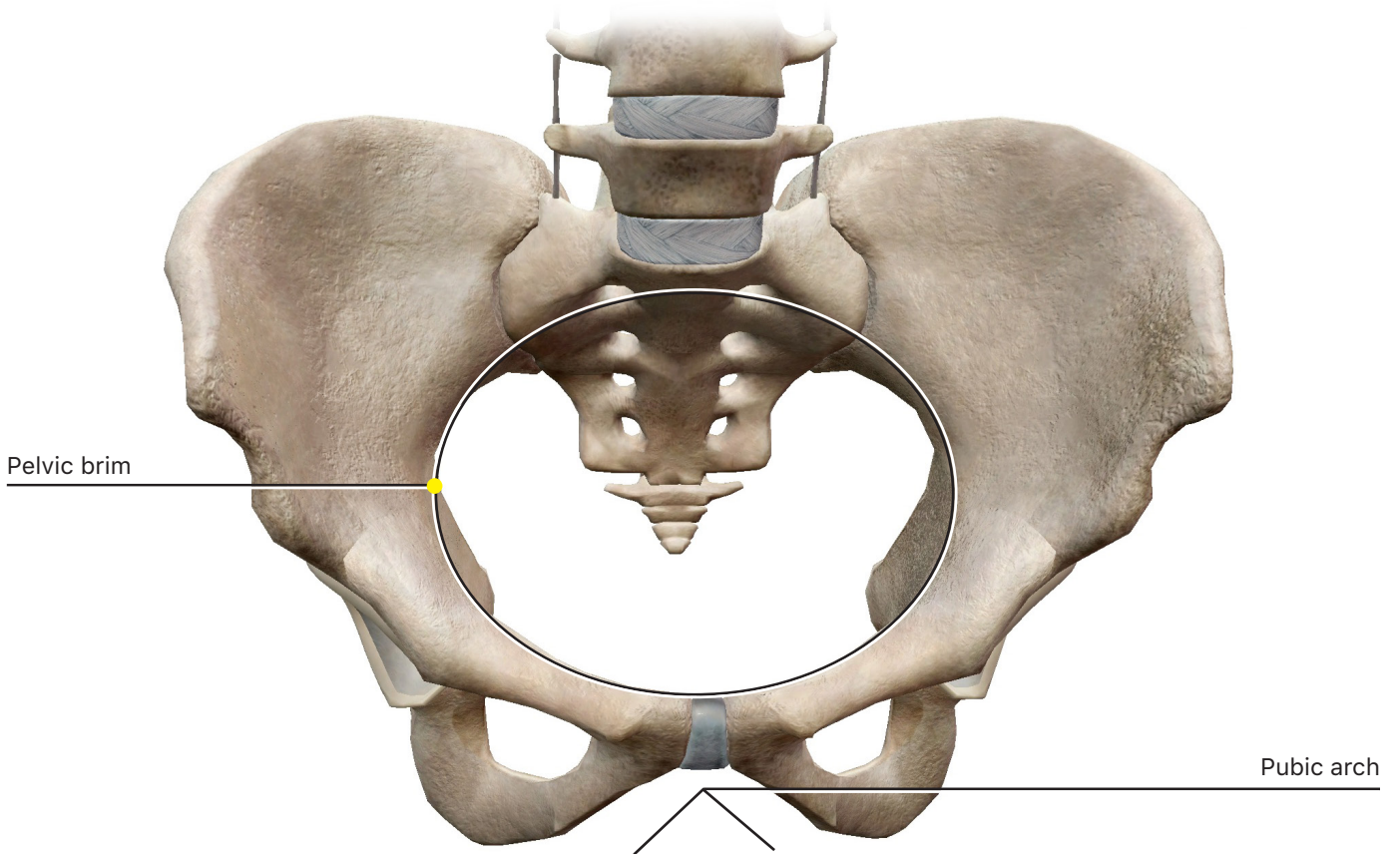
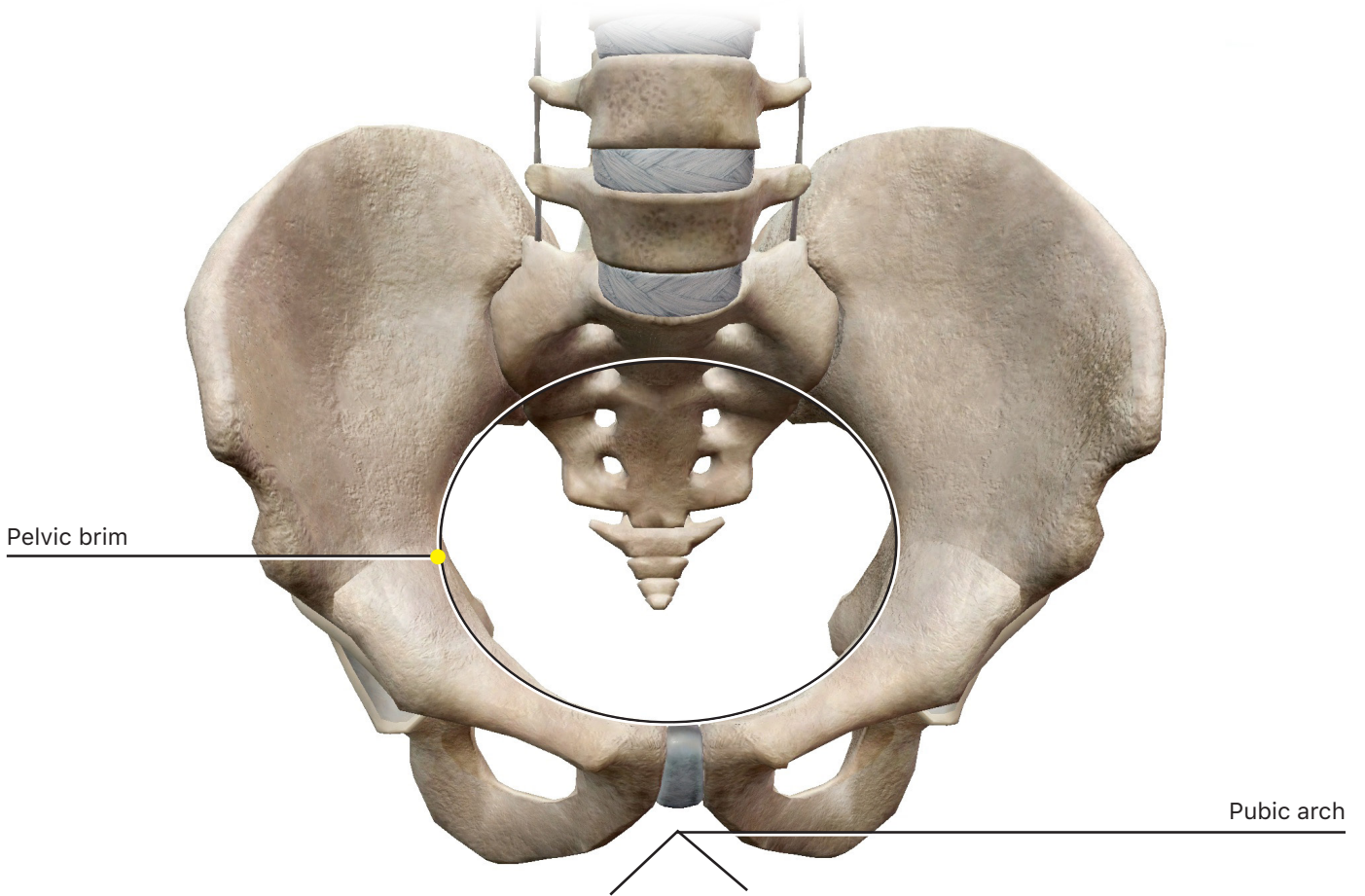
a. Identify the following bone markings:

- i. **Body**
- ii. **Acetabulum**
- iii. **Superior ramus**
- iv. **Inferior ramus**
- v. **Pubic arch**
- vi. **Pubic crest**
- vii. **Pubic tubercle**
- viii. **Obturator crest**
- ix. **Obturator foramen (pubis surface)**

4. Where does the lower limb attach to the hip bone? Which part of the hip bone is this?

5. The male and female pelvises have a few differences due to childbearing adaptations. Observe the pelvises by selecting the Tour "Pelvis Comparison" and answer the following questions. If the tour is not already in your app, add it now using the following sharelink:

https://apps.visiblebody.com/share/?p=vbhaa&t=4_28238_637528914355439910_1009619



a. Does the male or female pelvis have more space inside?

b. Describe what the pelvic brim is.

c. How is the pelvic brim different in males vs. females?

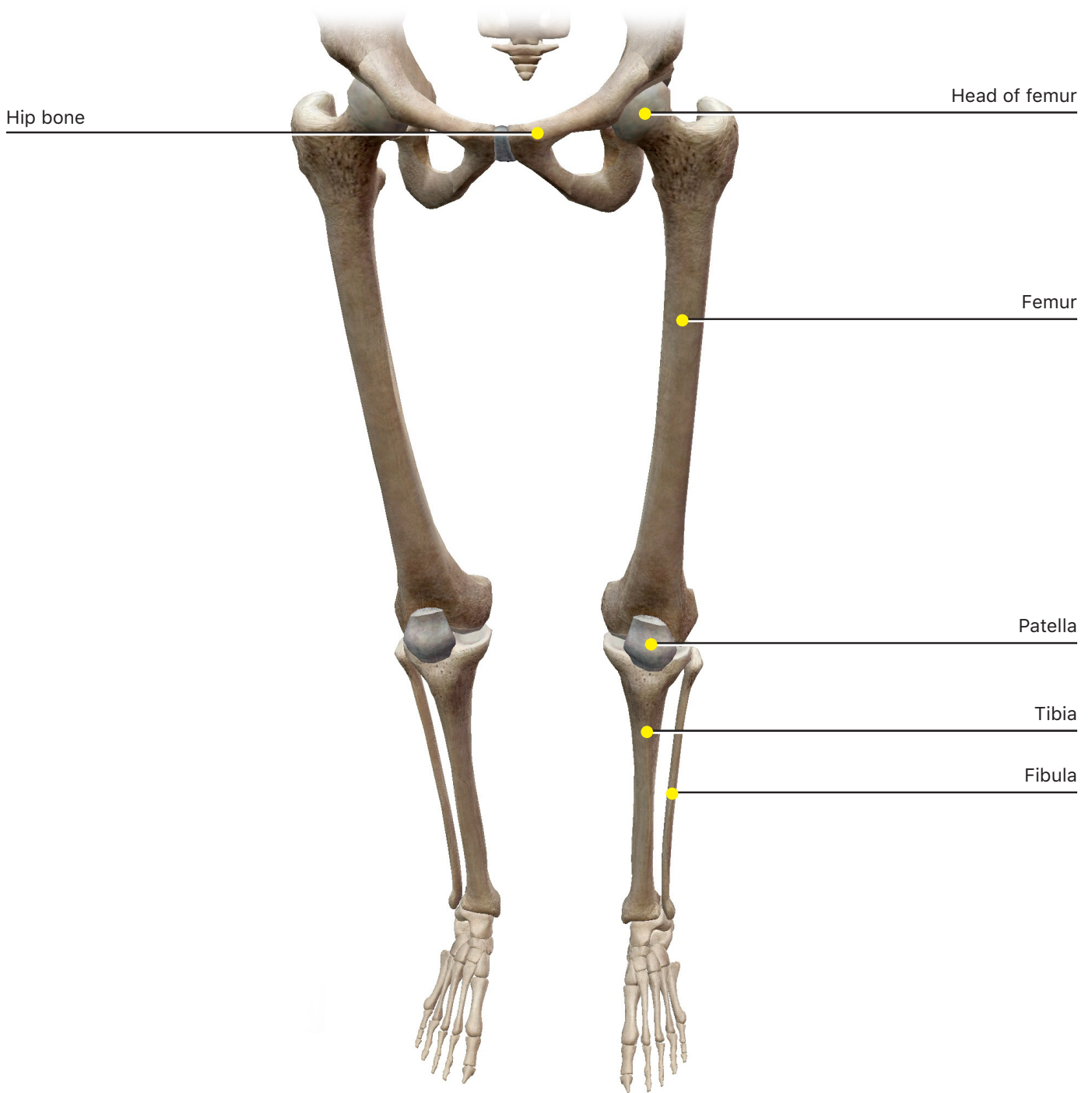
d. Describe what the pubic arch is.

e. How is the pubic arch different in males vs. females?

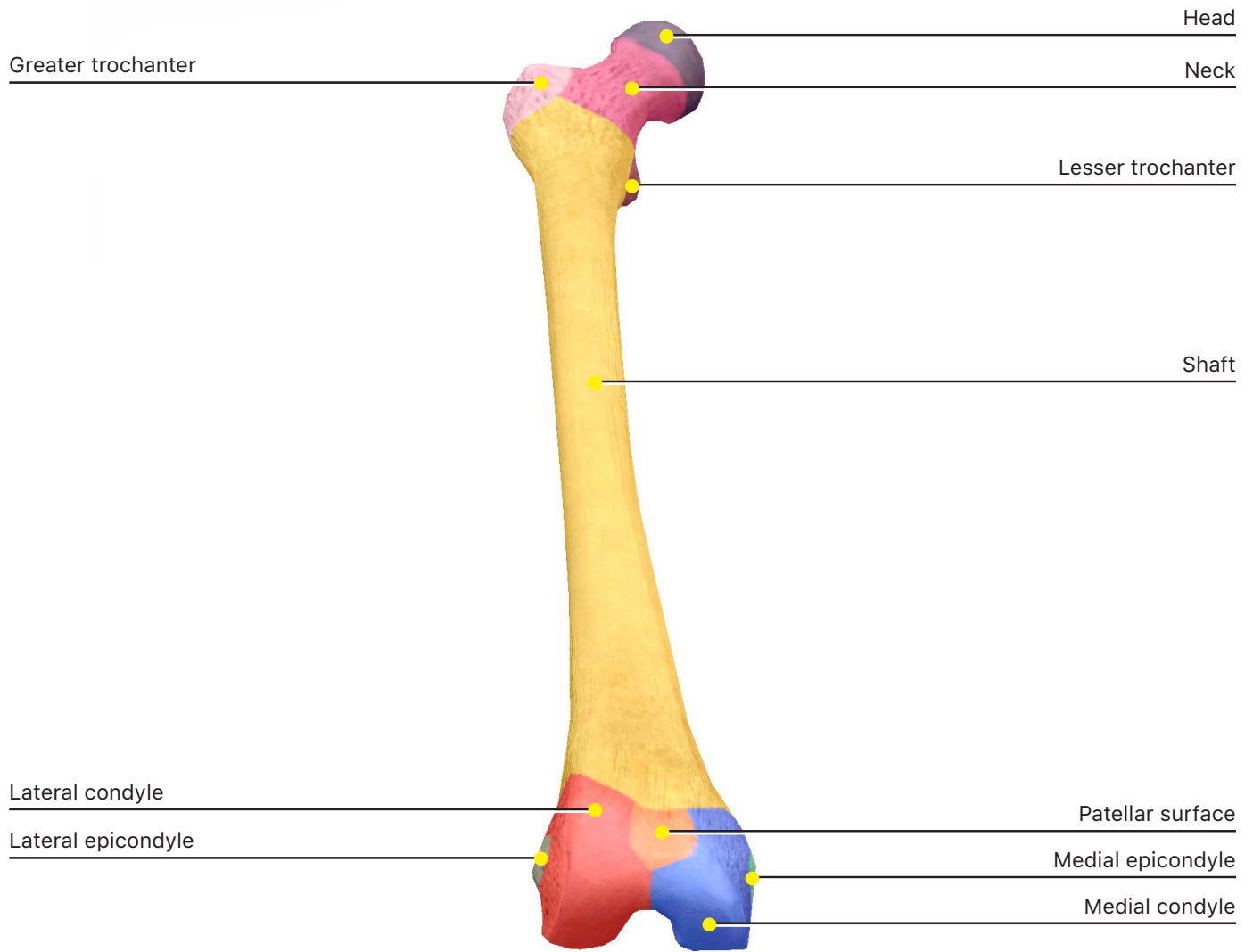
D. Lower Limb

Open the Skeletal System View "Full Skeleton" to identify the bones of the lower limb.

In addition to their importance in movement, the lower limb bones support the weight of the rest of the body. As a result, they are generally larger and heavier than the bones of the upper limb.



1. Femur



a. Identify the following bone markings:

- i. **Head**
- ii. **Shaft**
- iii. **Greater trochanter**
- iv. **Lesser trochanter**
- v. **Neck**
- vi. **Lateral condyle**
- vii. **Lateral epicondyle**
- viii. **Medial condyle**

ix. **Medial epicondyle**

x. **Intercondylar fossa**

xi. **Gluteal tuberosity**

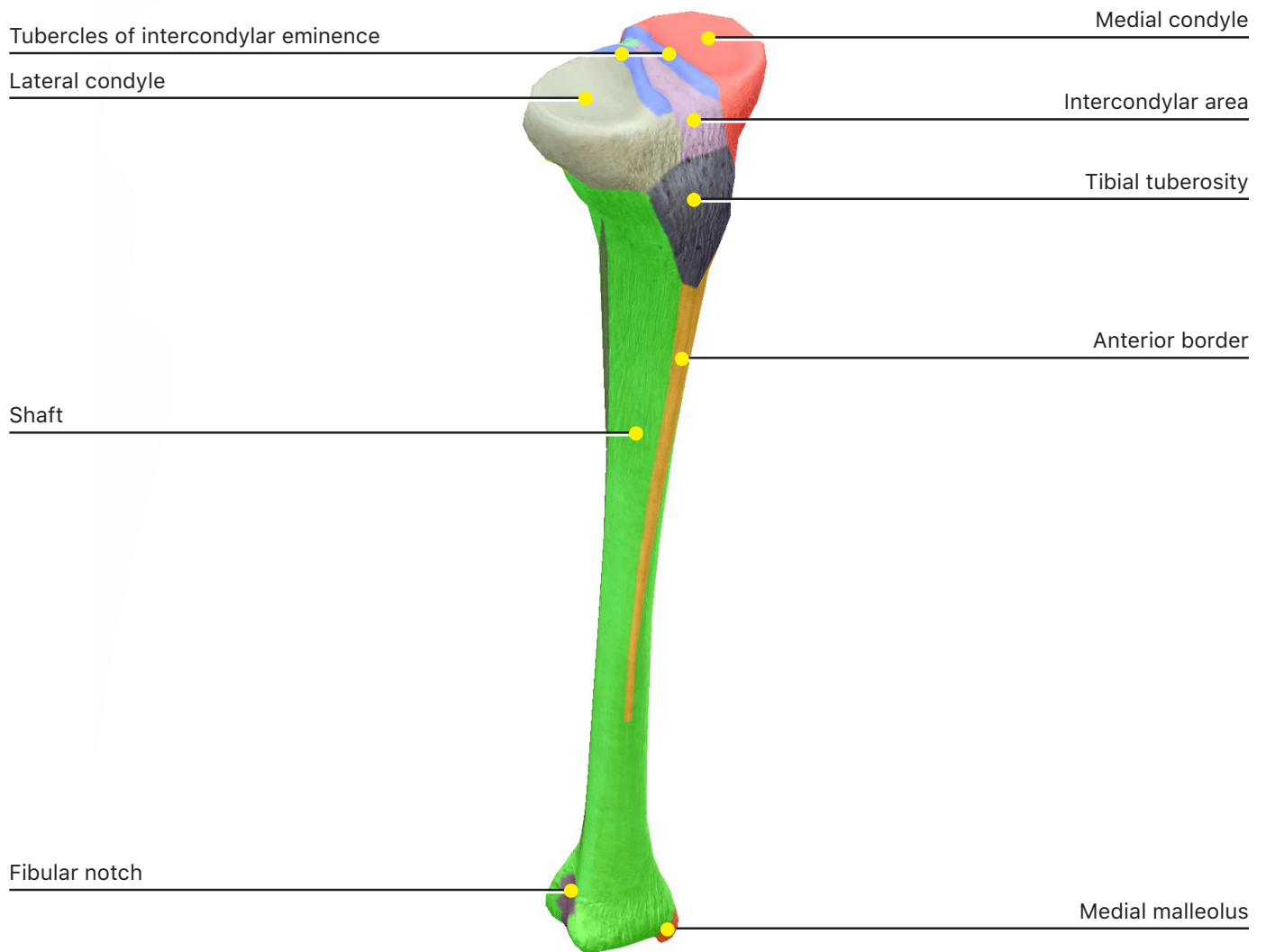
xii. **Linea aspera**

xiii. **Patellar surface**

xiv. **Popliteal surface**

b. Describe how you would differentiate between a right femur and a left femur.

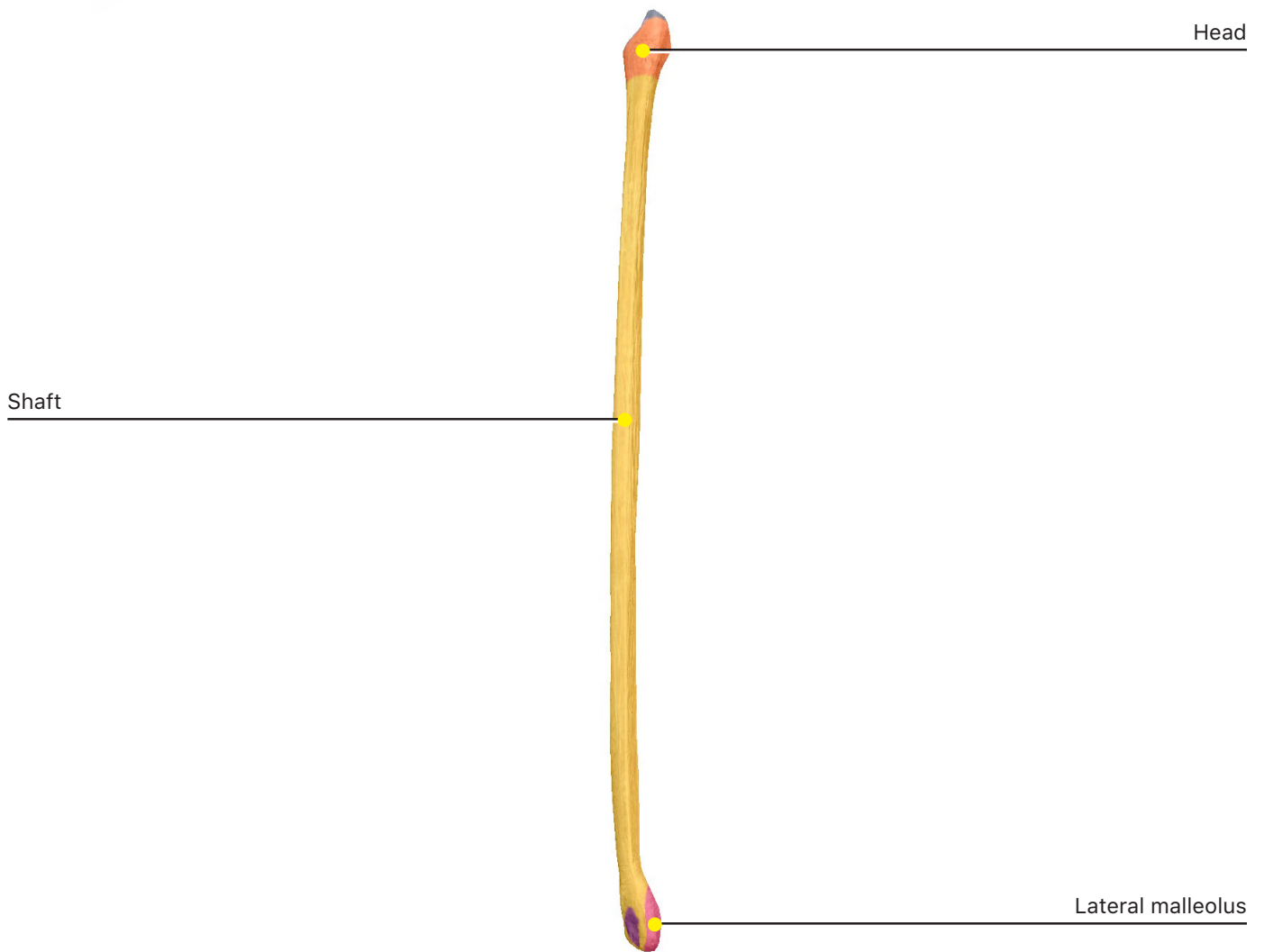
2. Tibia



a. Identify the following bone markings:

- i. **Shaft**
- ii. **Medial condyle**
- iii. **Lateral condyle**
- iv. **Intercondylar area**
- v. **Tibial tuberosity**
- vi. **Anterior border**
- vii. **Medial malleolus**

3. Fibula



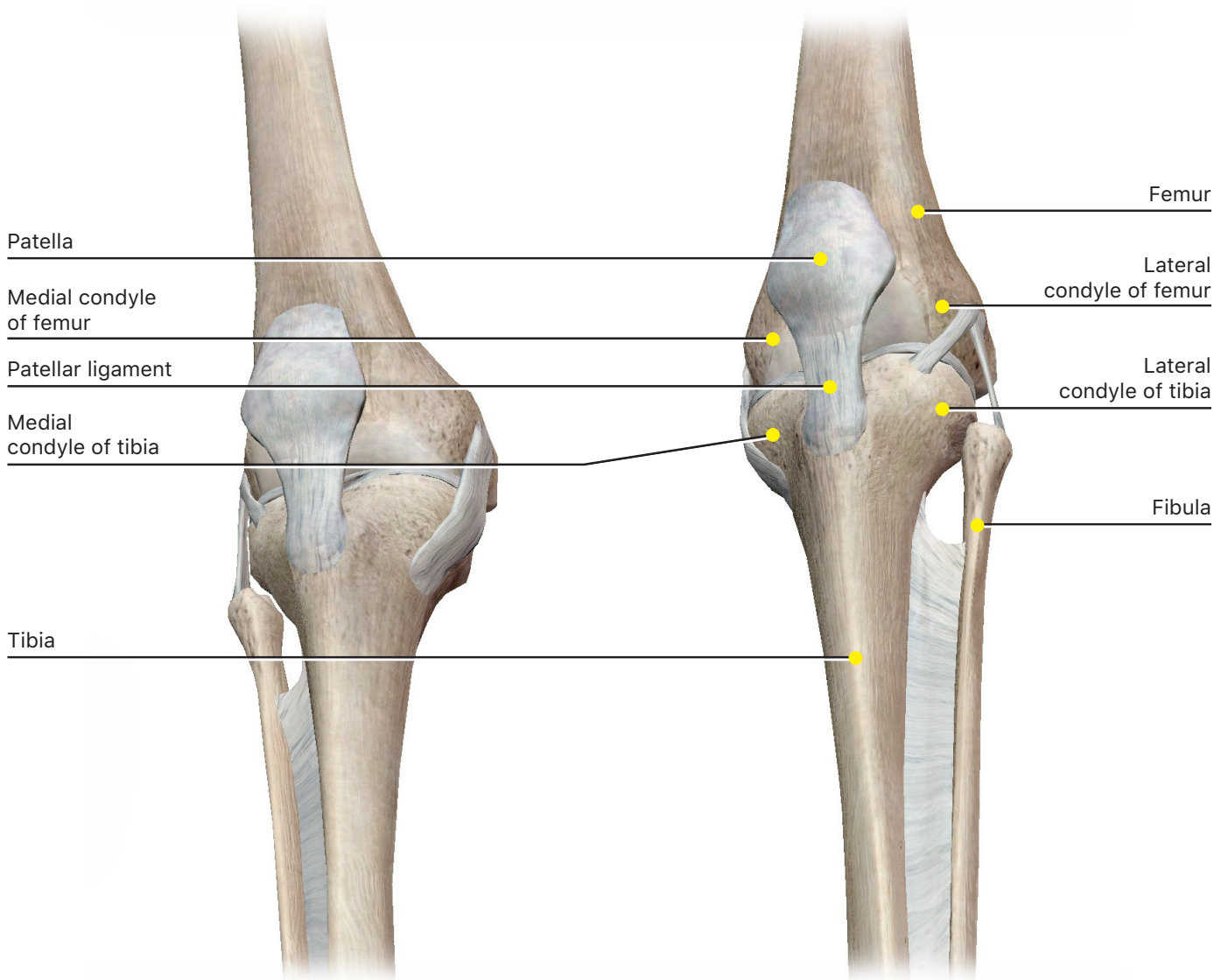
a. Identify the following bone markings:

i. **Head**

ii. **Shaft**

iii. **Lateral malleolus**

4. Patella

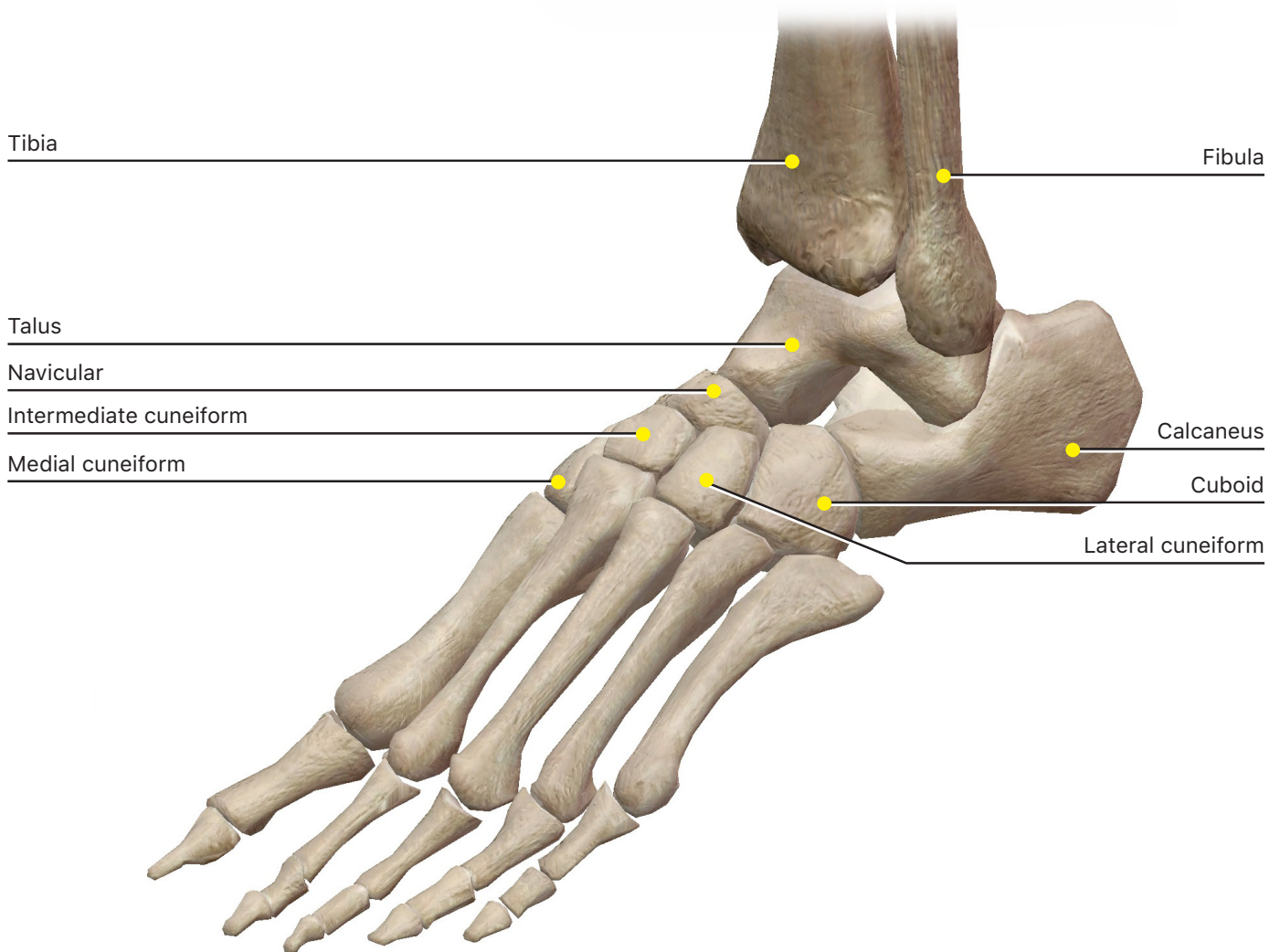


a. Which bones compose the knee joint?

b. Where do the different bones attach to each other?

5. Tarsus

To see the tarsals more clearly, hide some or all of the ligaments on the wrist after you zoom in.



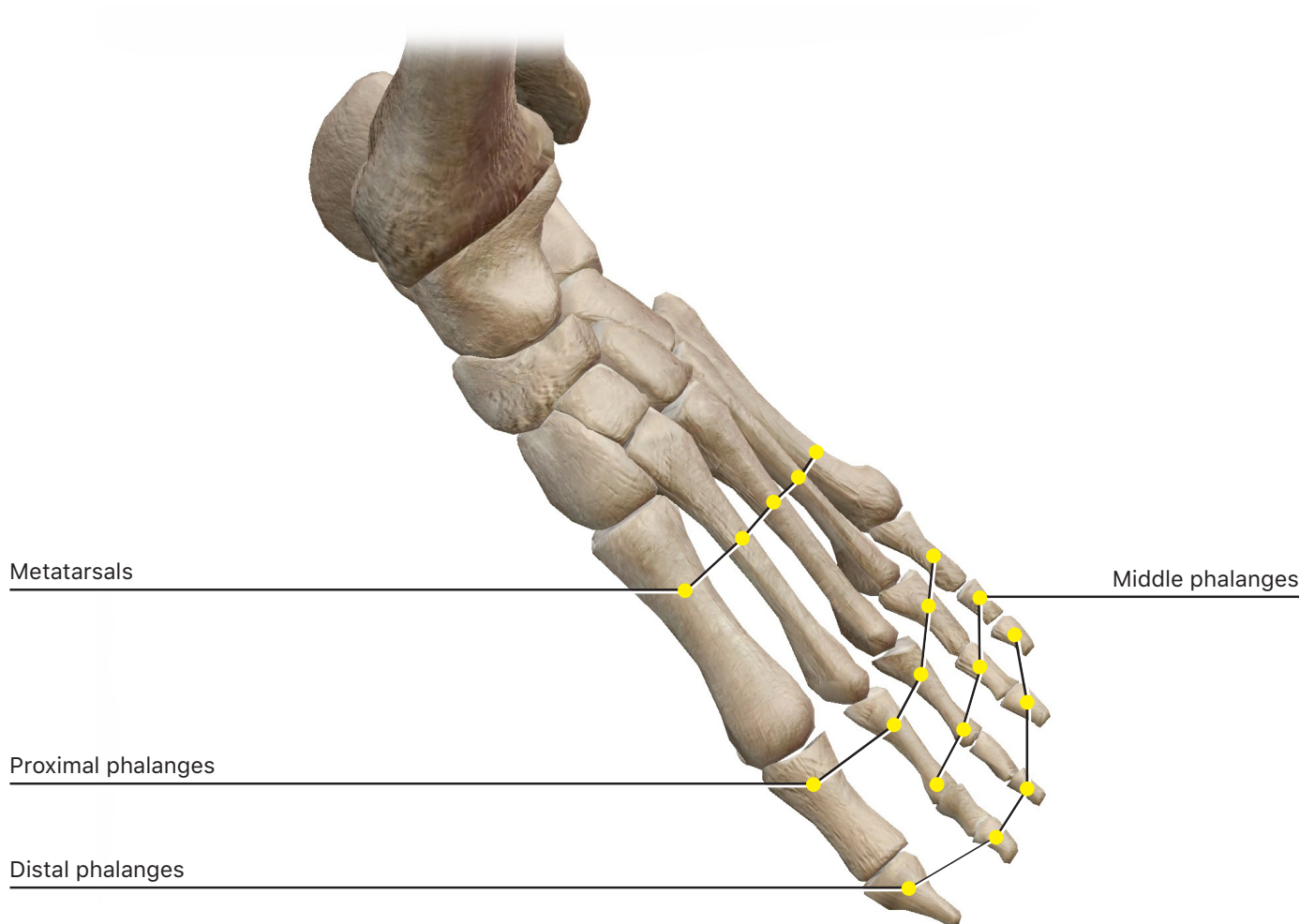
a. Identify the following tarsal bones:

- i. **Calcaneus**
- ii. **Talus**
- iii. **Medial cuneiform**
- iv. **Intermediate cuneiform**
- v. **Lateral cuneiform**
- vi. **Cuboid**
- vii. **Navicular**

b. Which bone forms the heel of the foot?

6. Foot

Note that the nomenclature for the toes is the same as for the hand. The big toe is considered digit I, and the pinky toe is digit V.



a. Identify the following foot bones:

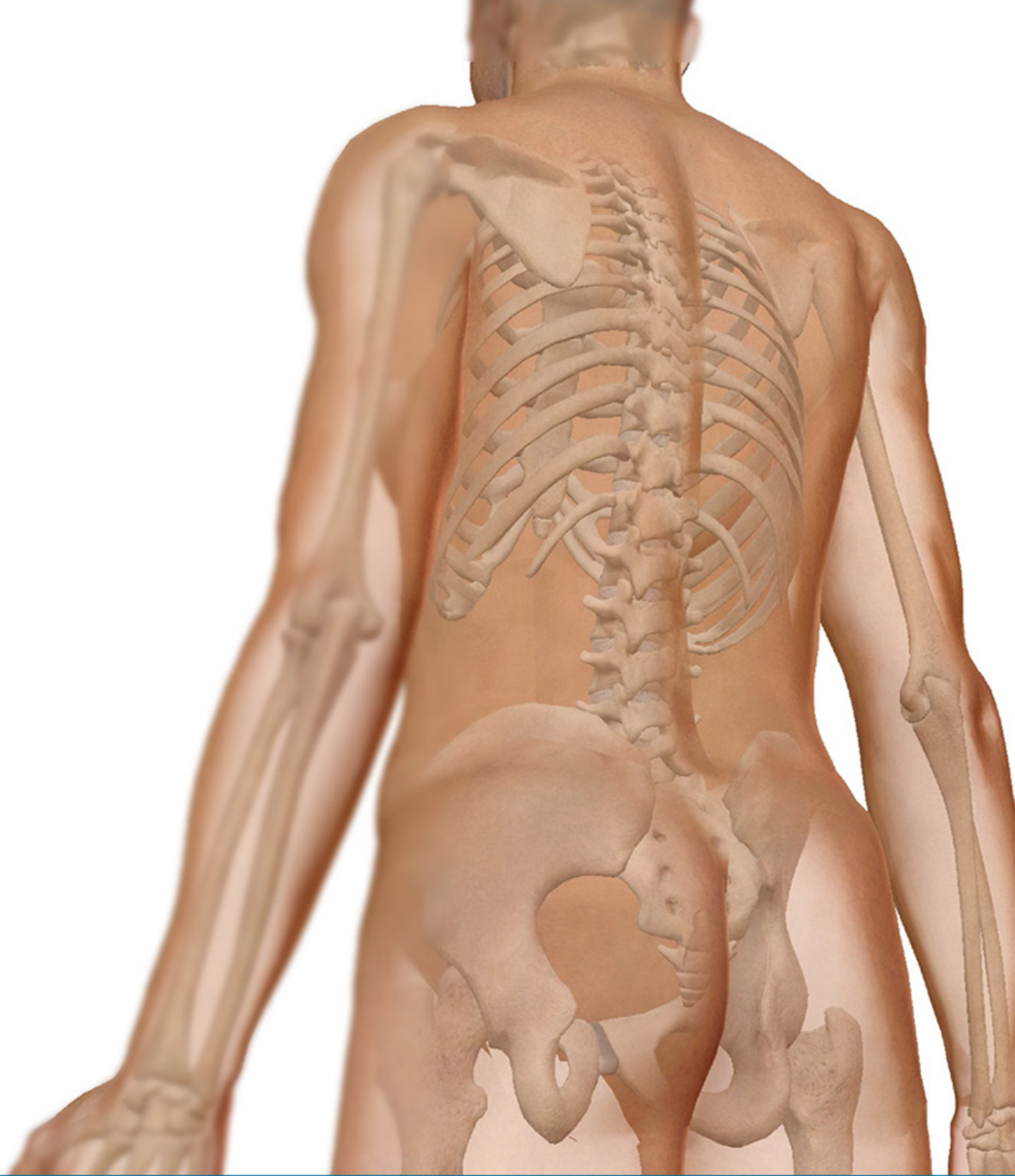- i. **Metatarsals**
- ii. **Proximal Phalanges**
- iii. **Middle Phalanges**
- iv. **Distal Phalanges**

PUTTING IT ALL TOGETHER

1. How is the shape of the glenoid cavity of the scapula different from that of the acetabulum in the hip bone? How do the shapes of these bone markings affect the range of motion at their respective joints?
2. How do the distinct characteristics of the female pelvis make childbirth easier?
3. Which bone markings are responsible for making the protrusions of the ankles, just above the feet?
4. When someone falls with an outstretched arm, a broken clavicle often results. Physically, how would that person appear afterward? What is the function of the clavicle?

TIME TO PRACTICE!

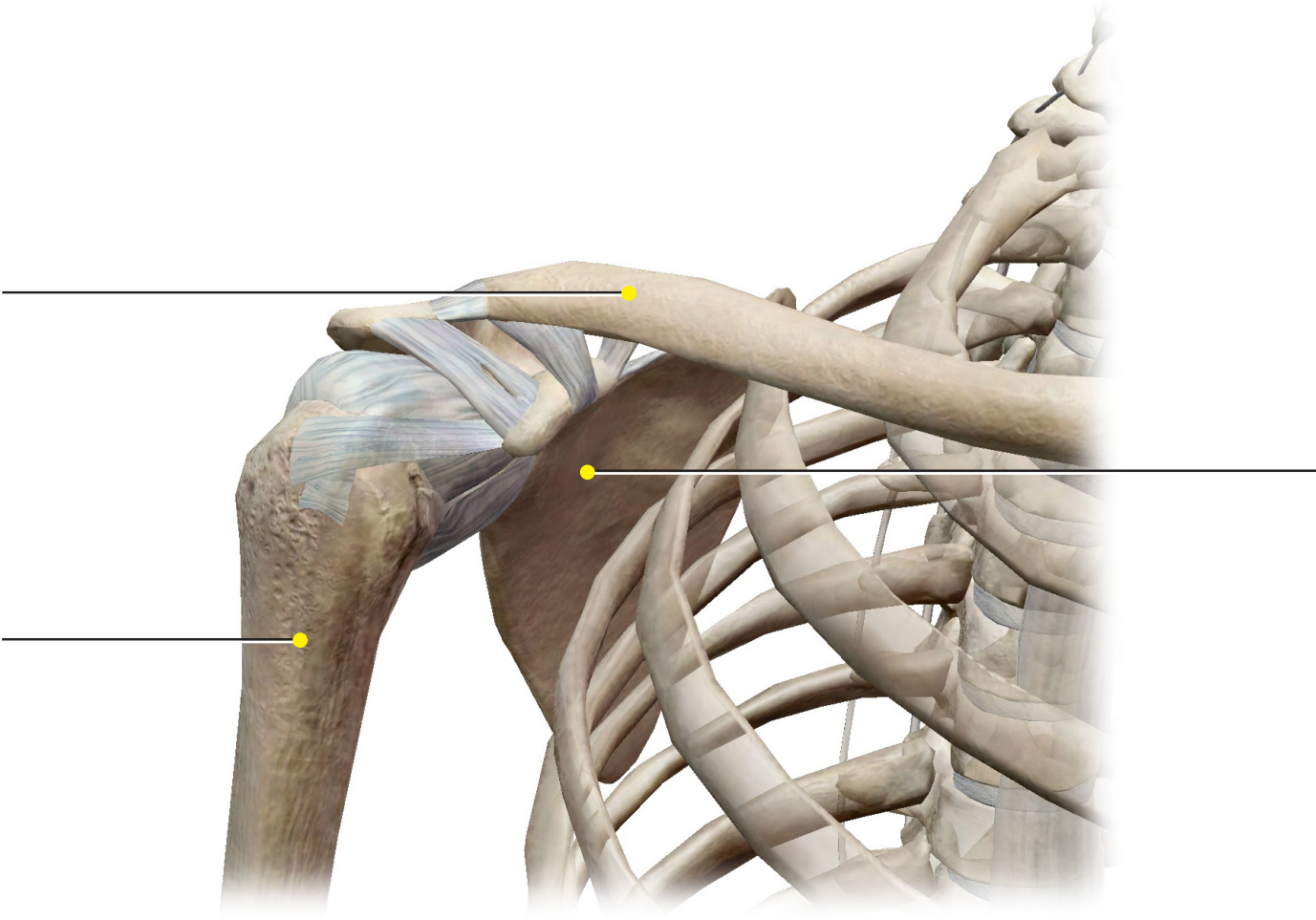
**SEARCH FOR AND TAKE THE FOLLOWING SKELETAL SYSTEM QUIZZES:
GIRDLES, UPPER LIMB, HAND, LOWER LIMB, AND FOOT**



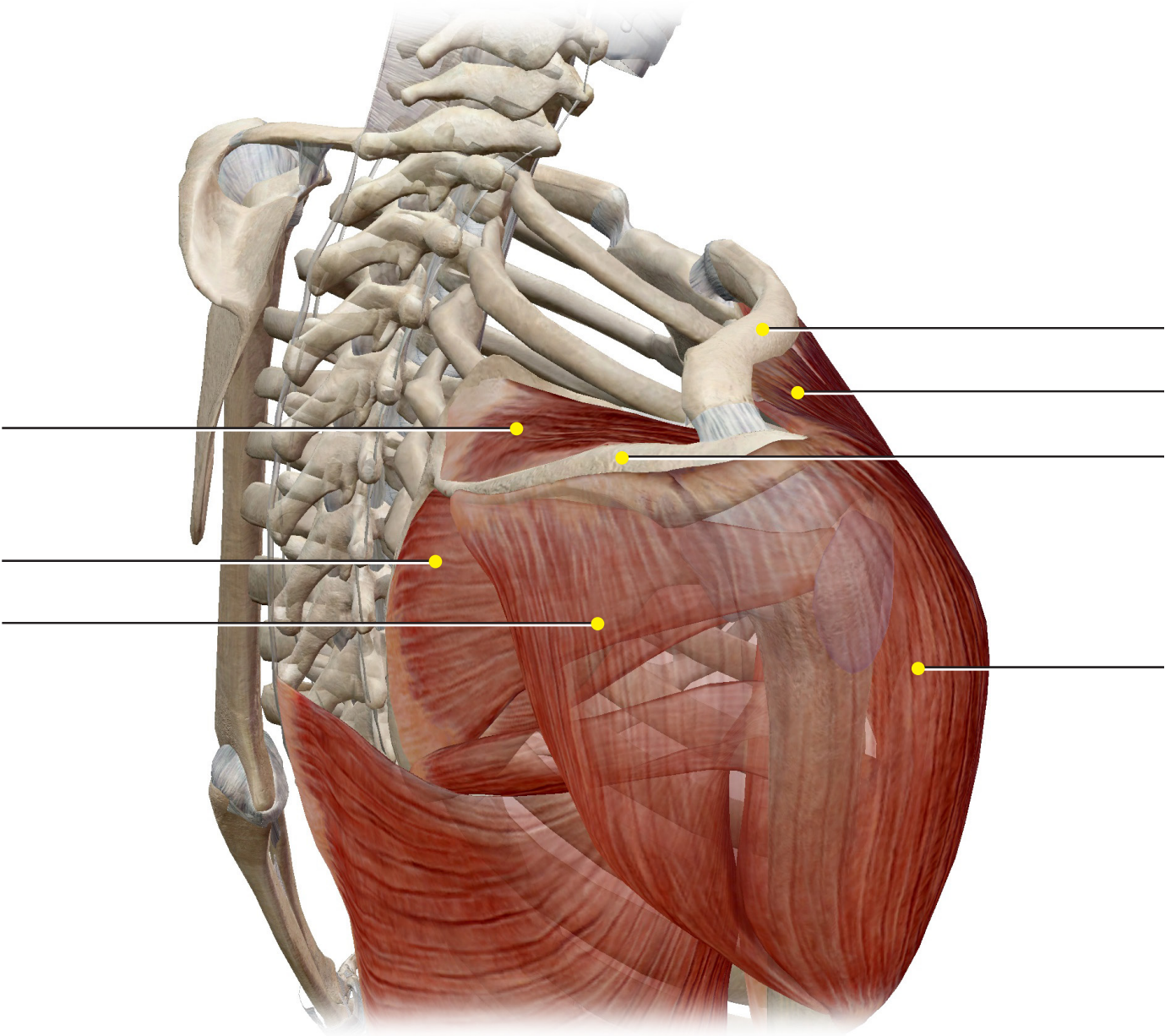
Student Practice

Label the structures in the following figures.

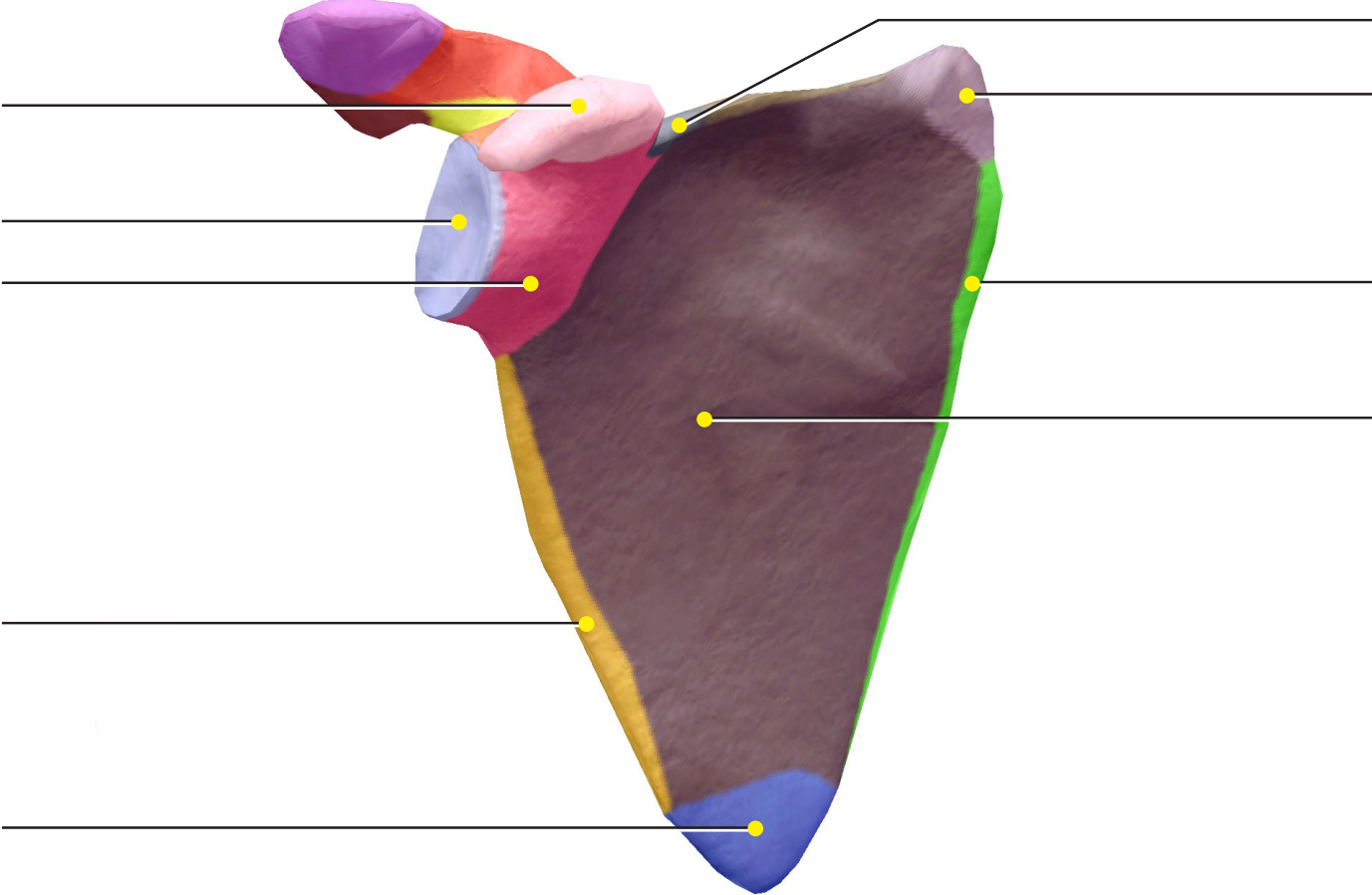
Source: Skeletal System View "Shoulder Girdle"



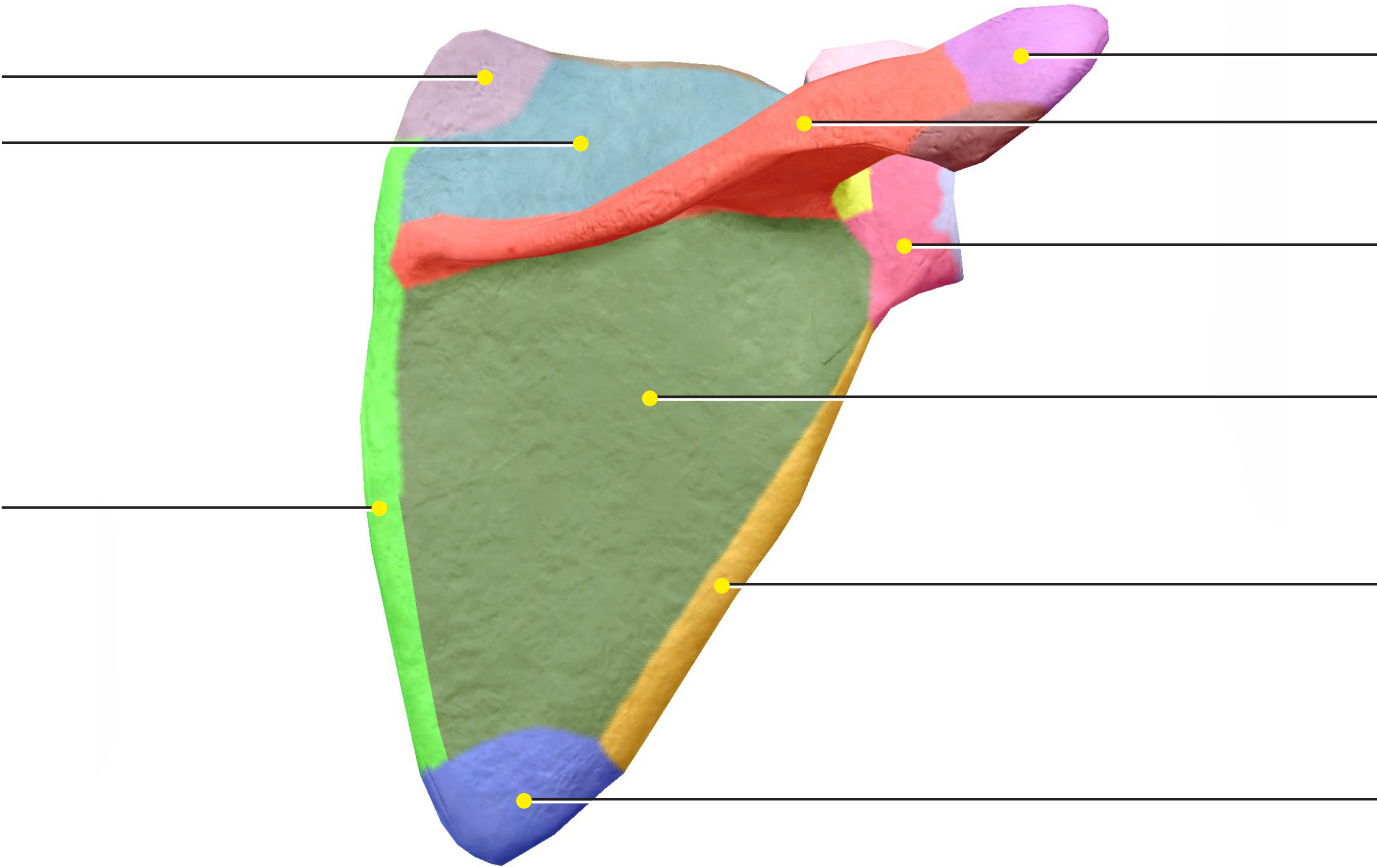
Source: Skeletal System View "Axillary Region"



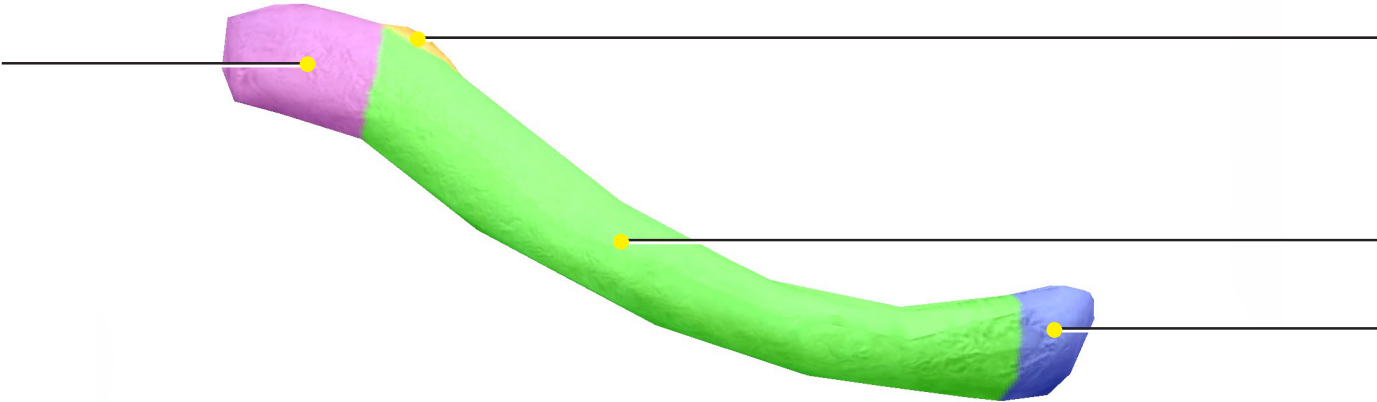
Scapula (Anterior) Source: Skeletal System View "Axillary Region"



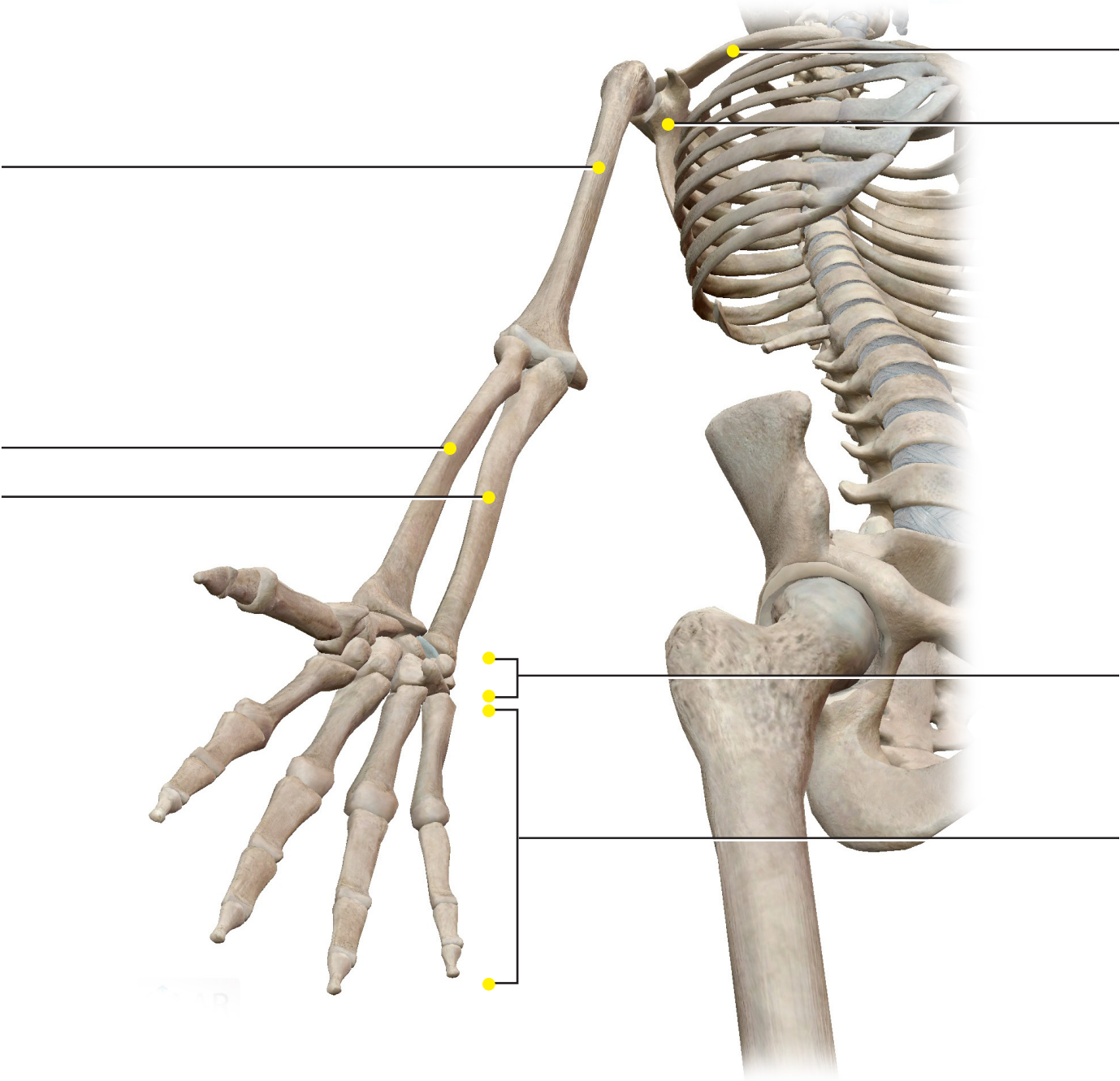
Scapula (Posterior) Source: Skeletal System View "Axillary Region"



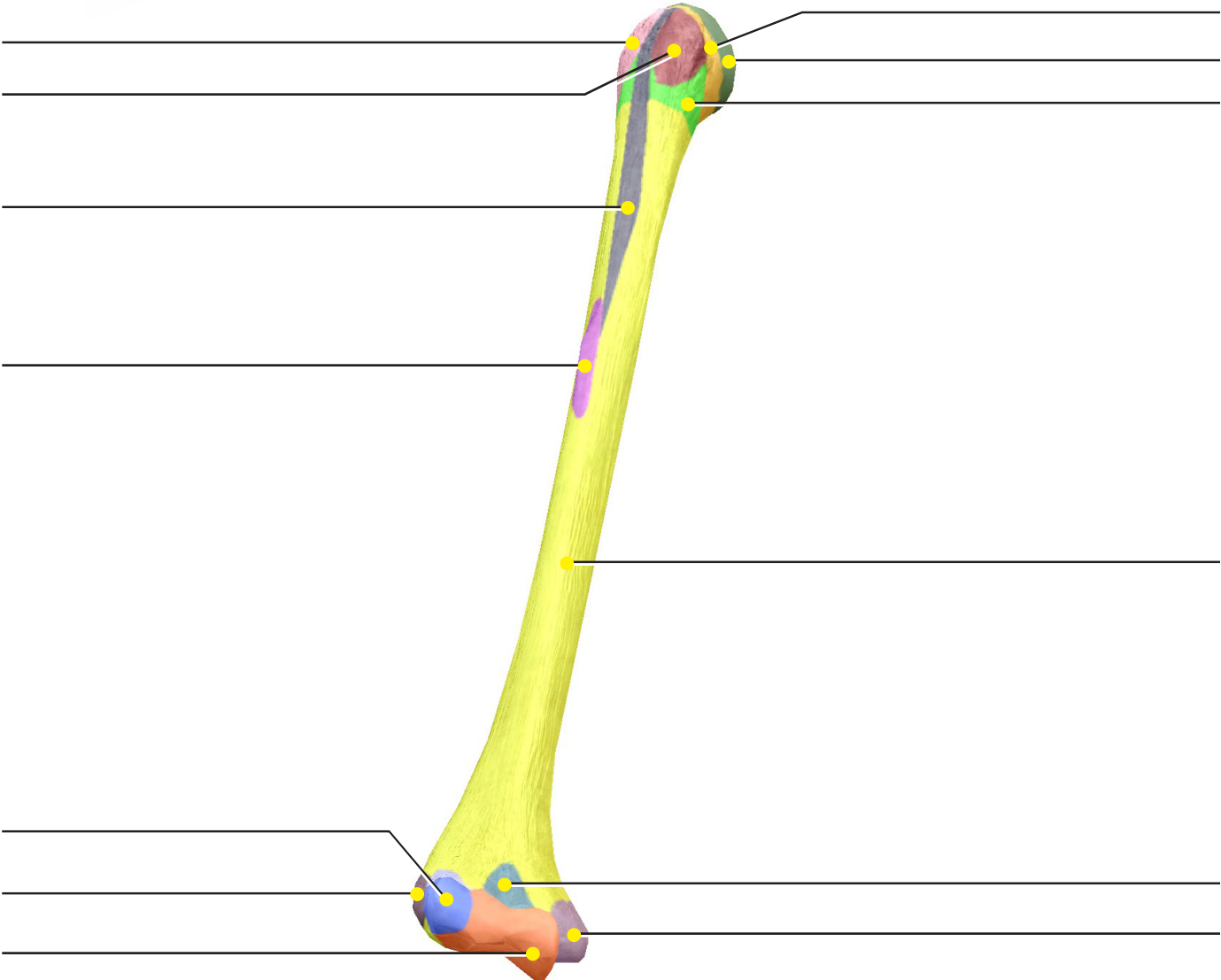
Clavicle



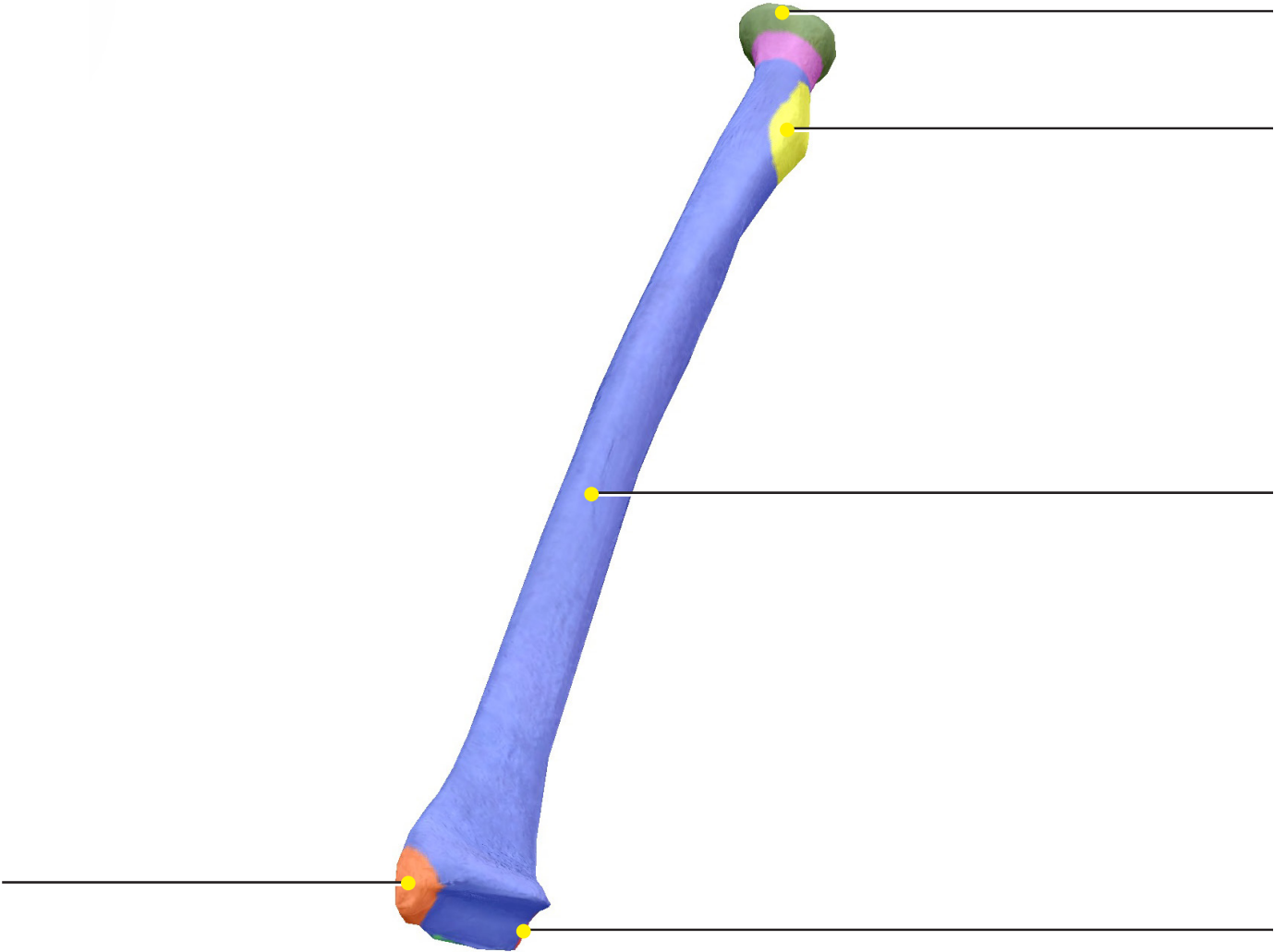
Source: Skeletal System View "Full Skeleton"



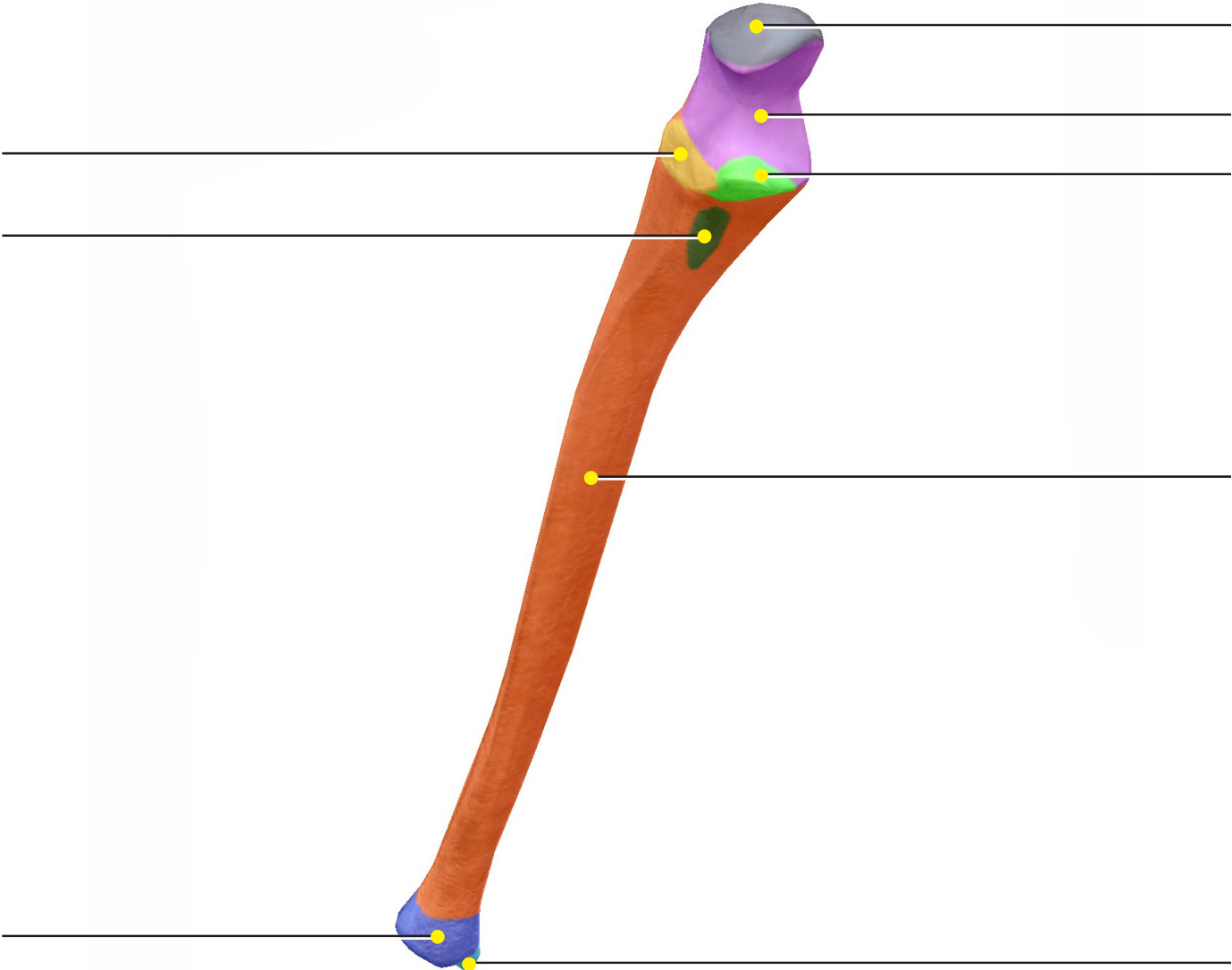
Humerus



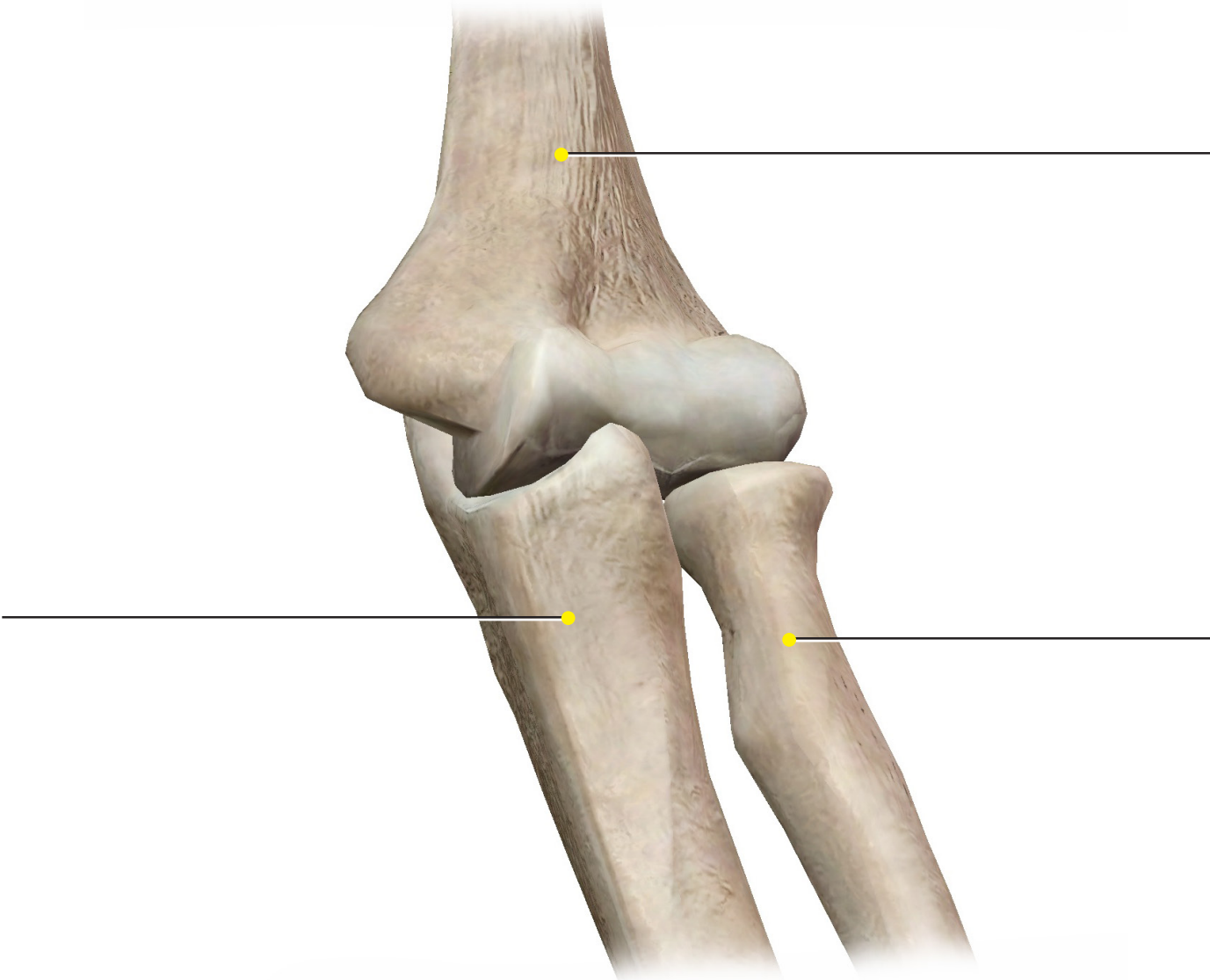
Radius



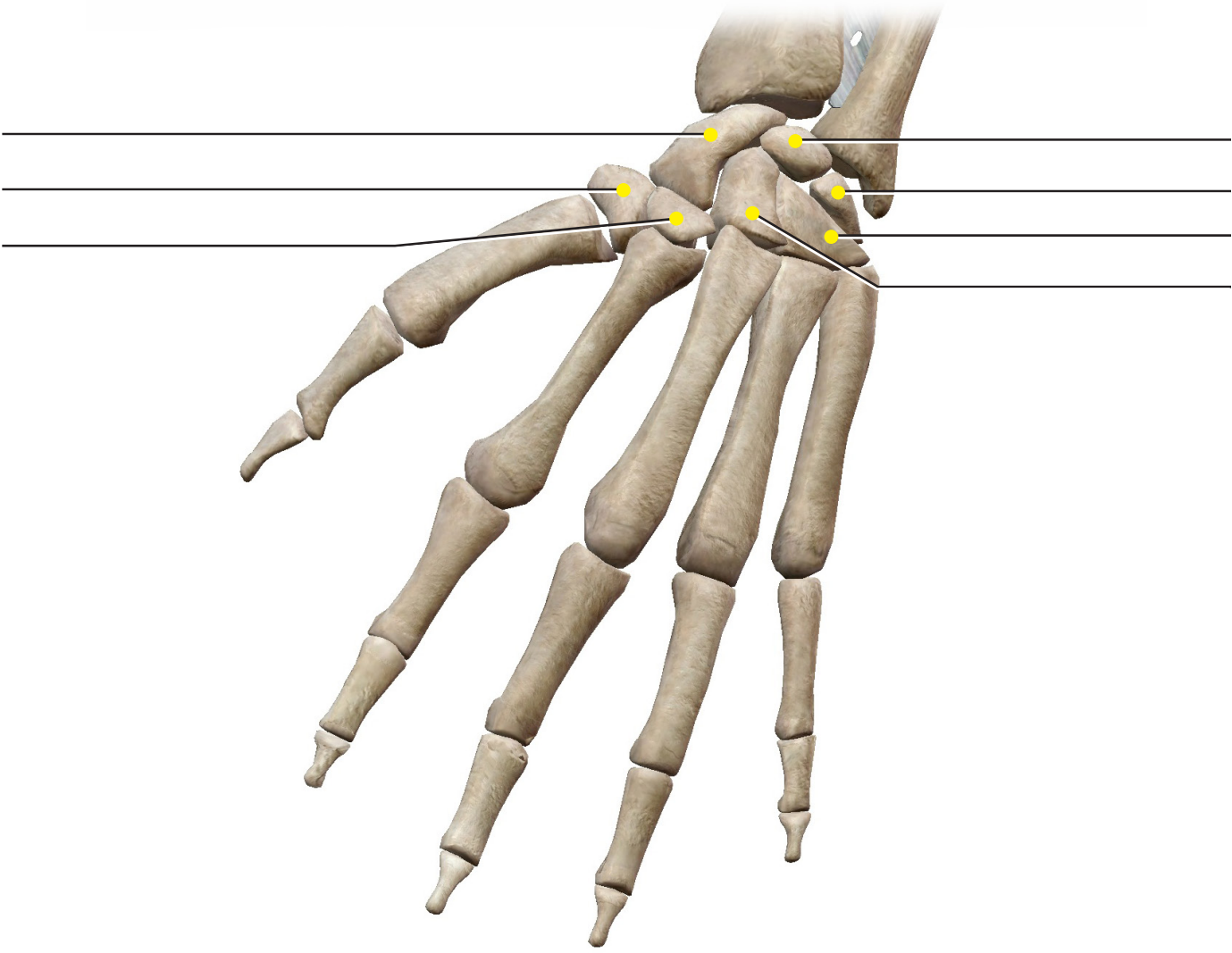
Ulna



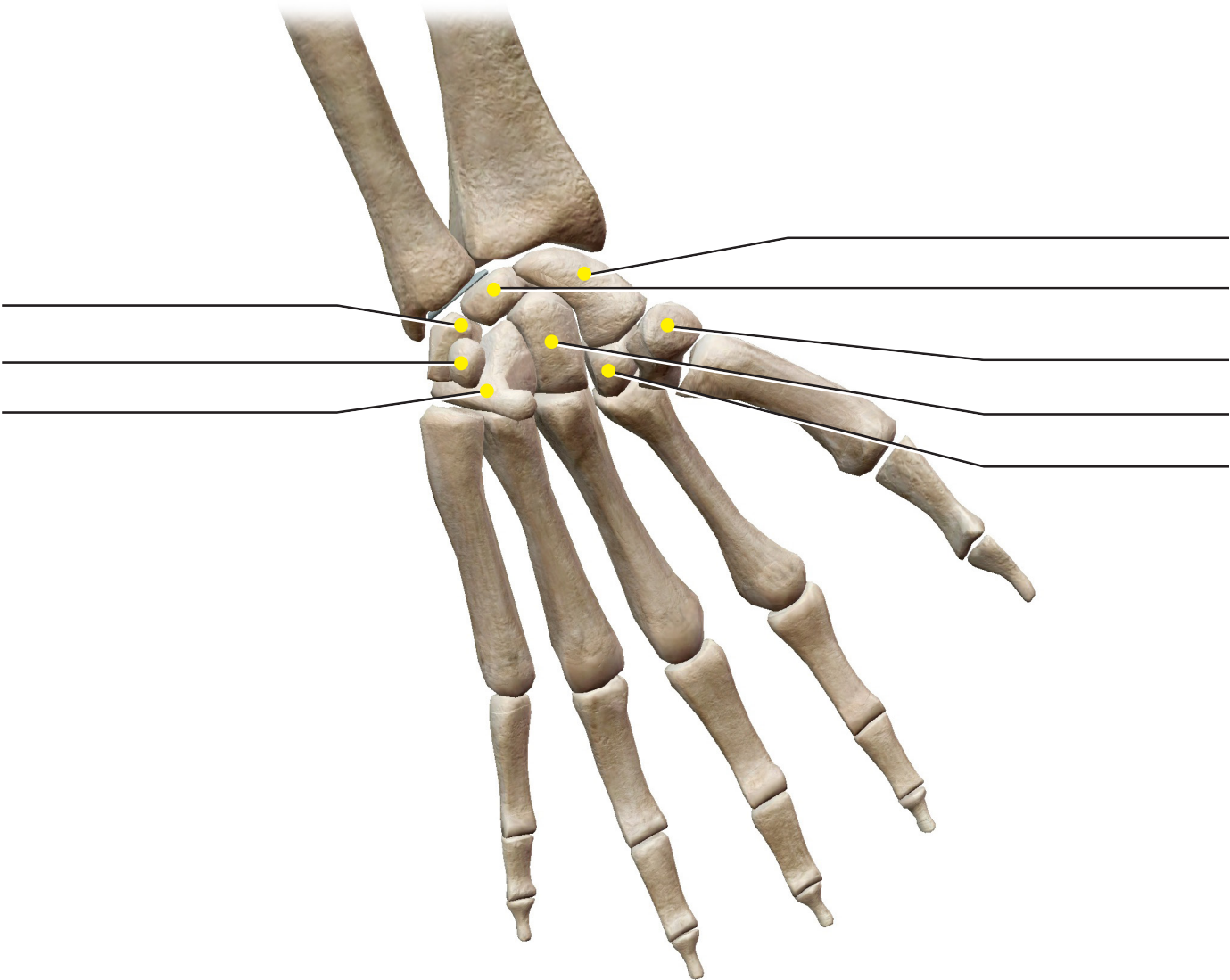
Radius and Ulna



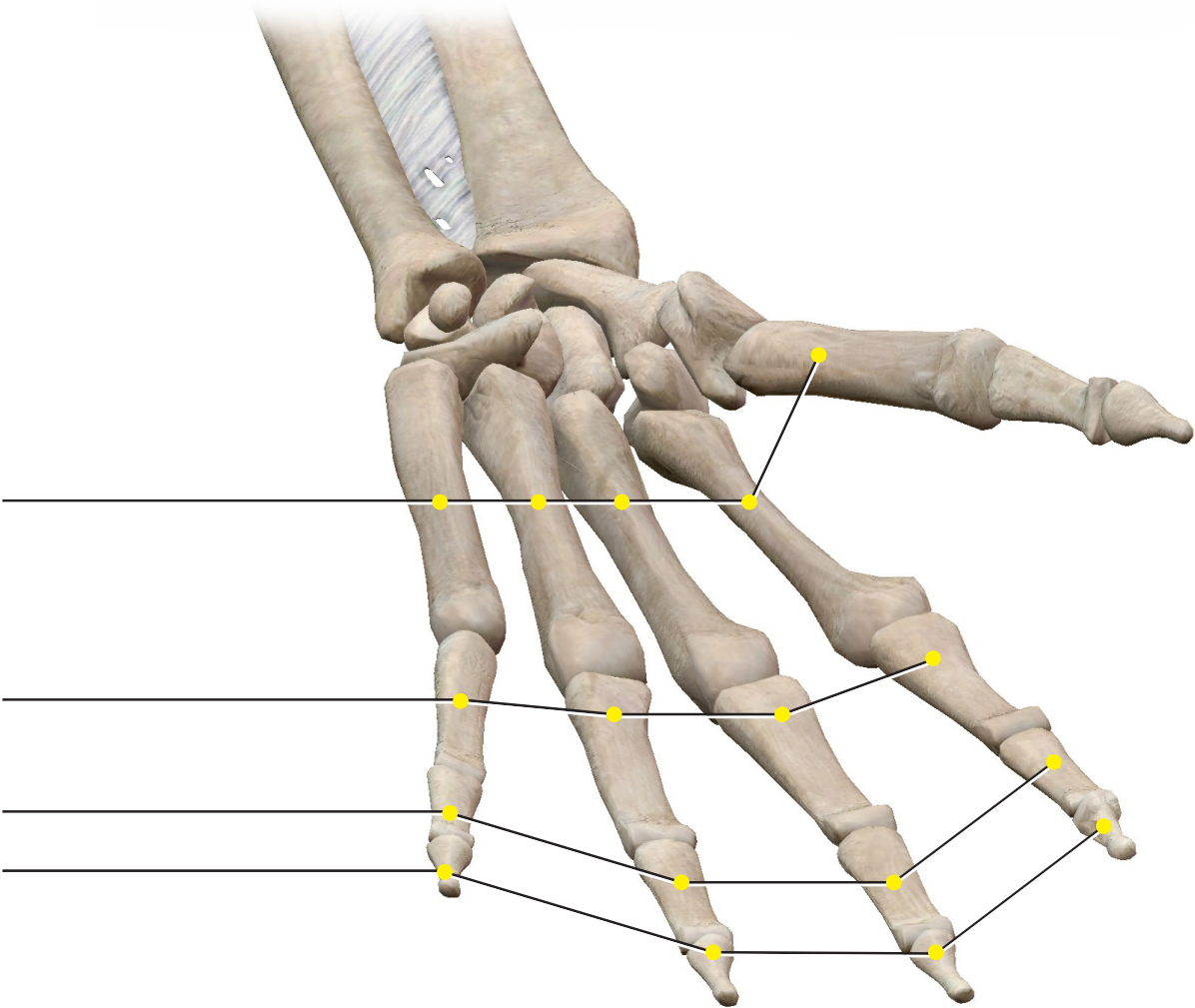
Carpus (Posterior)



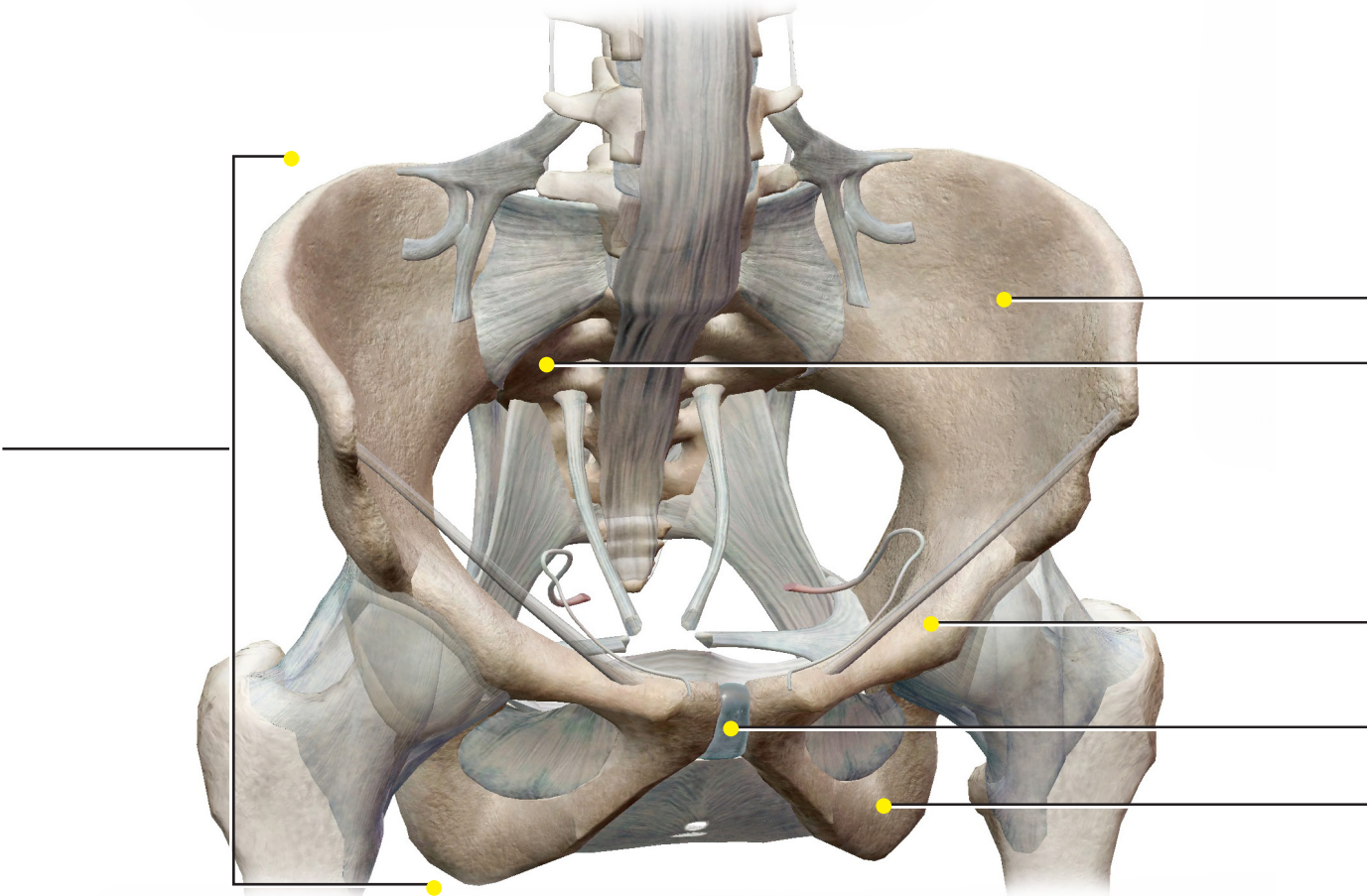
Carpus (Anterior)



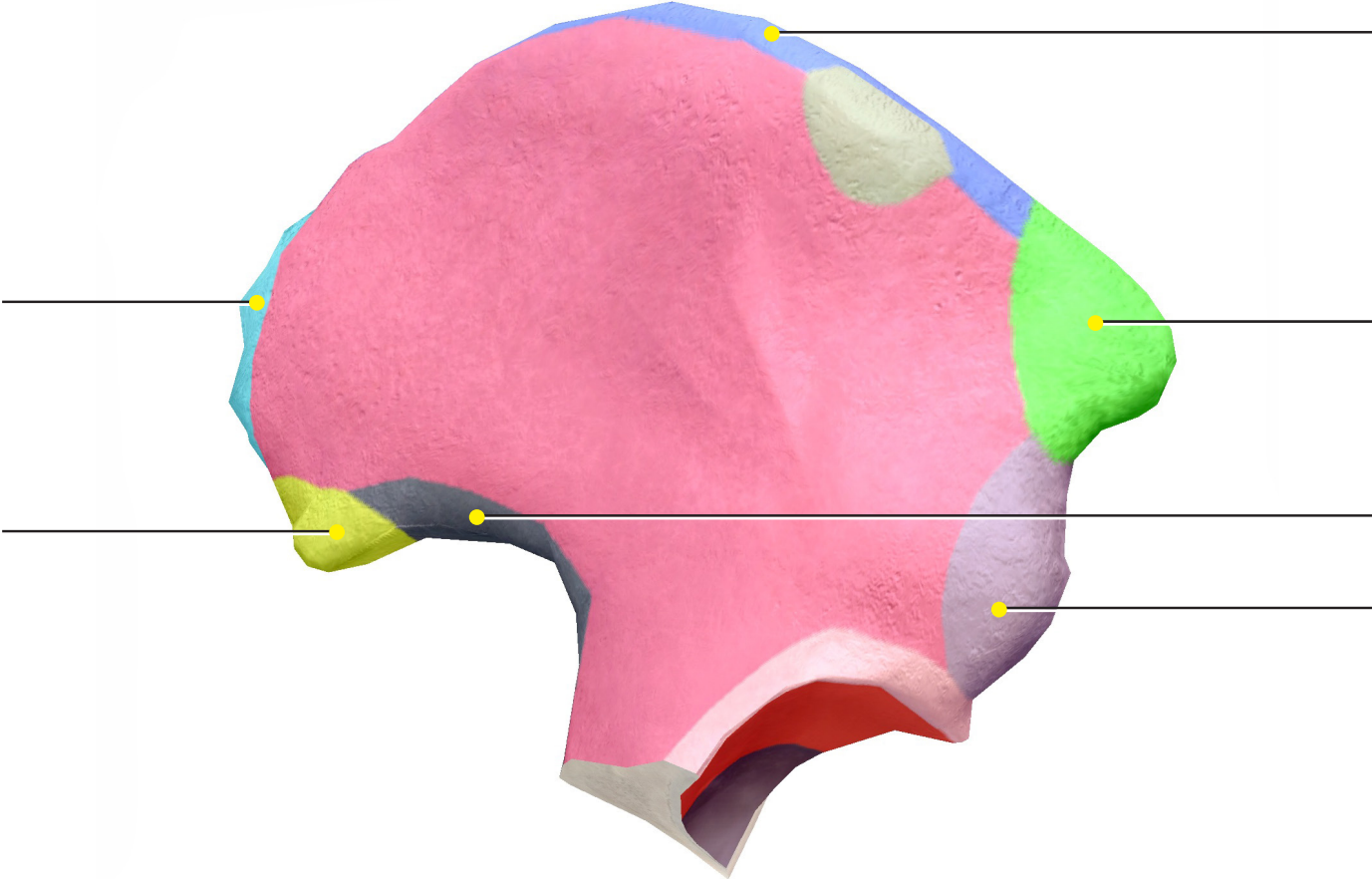
Hand



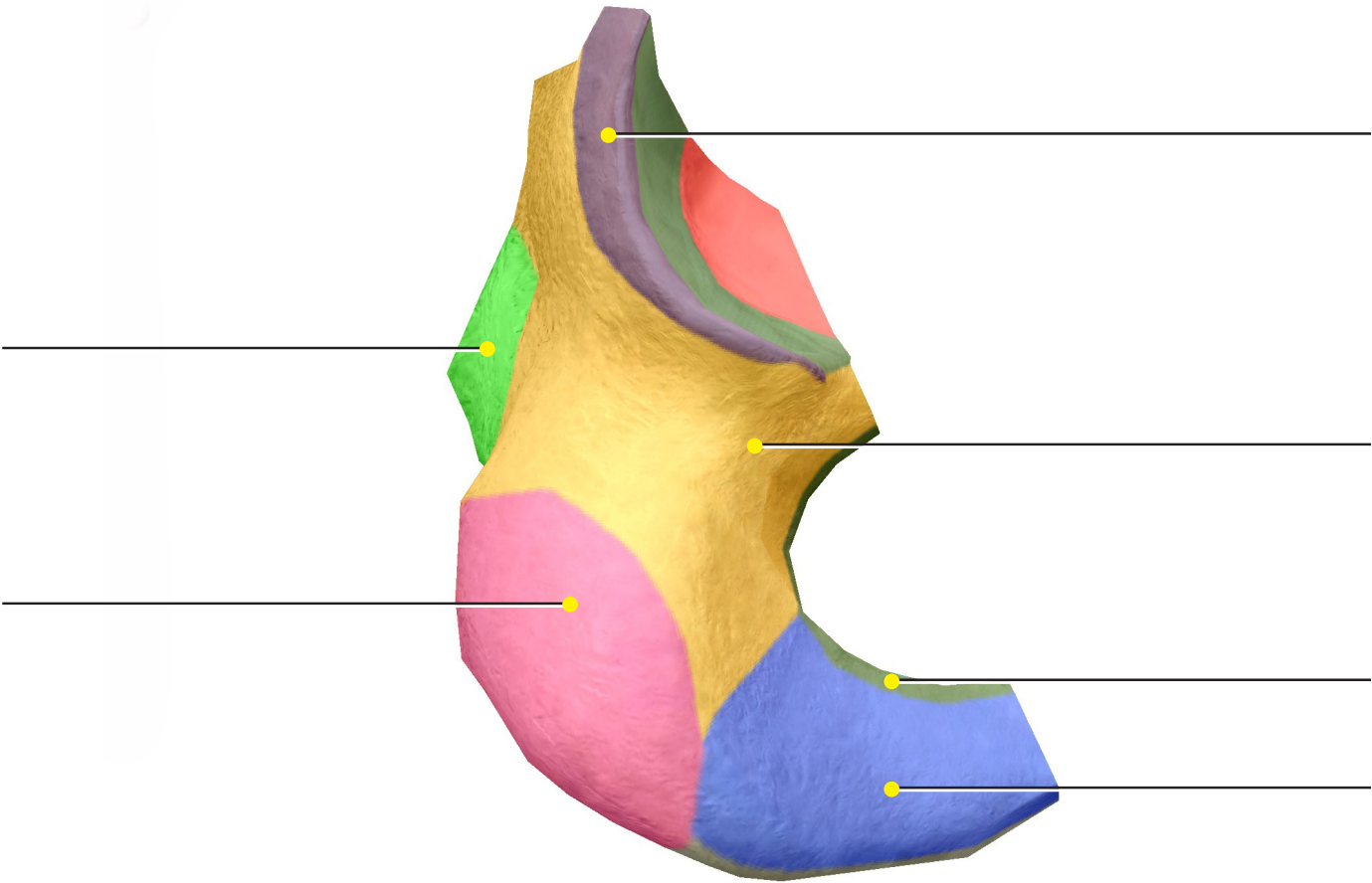
Source: Skeletal System View "Pelvic Girdle"



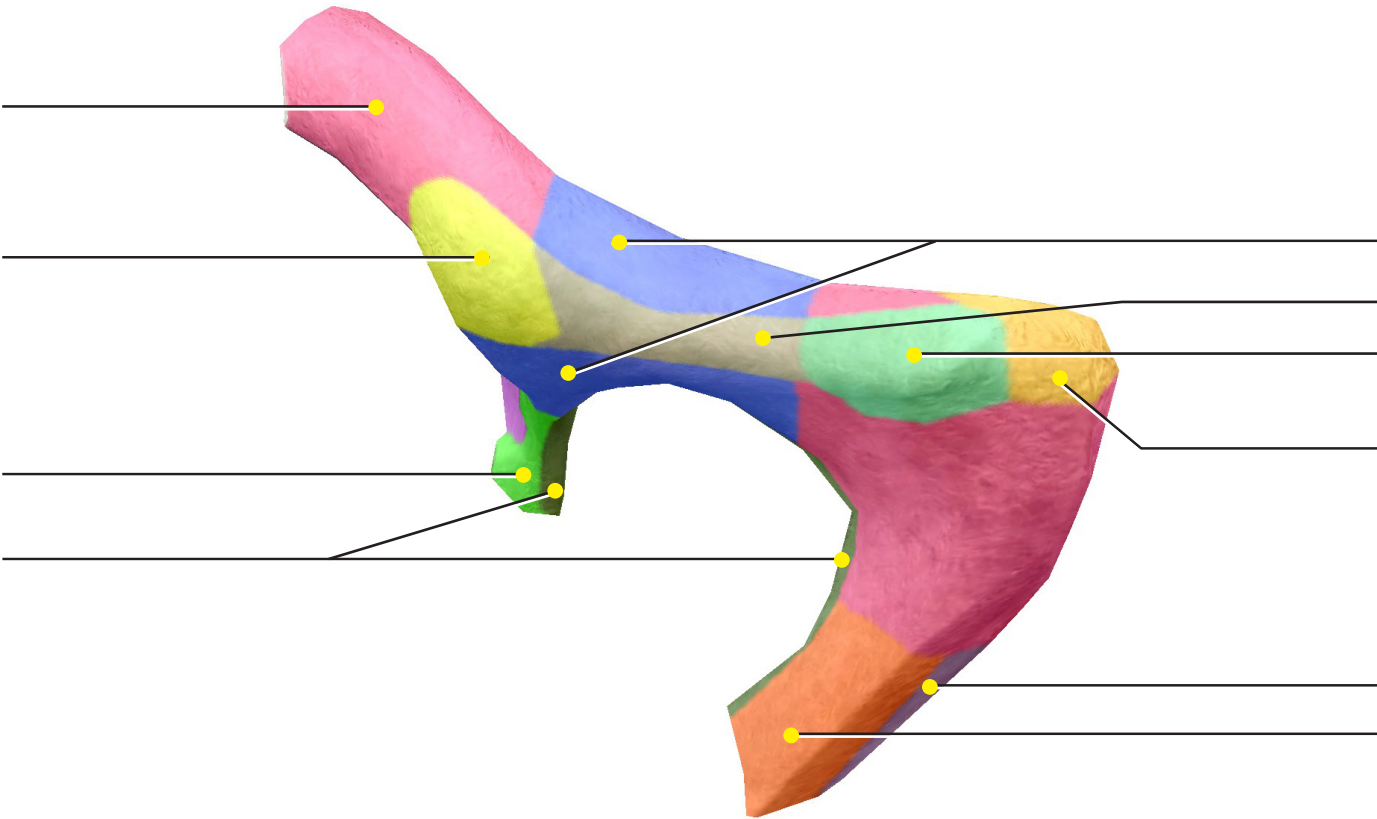
Ilium



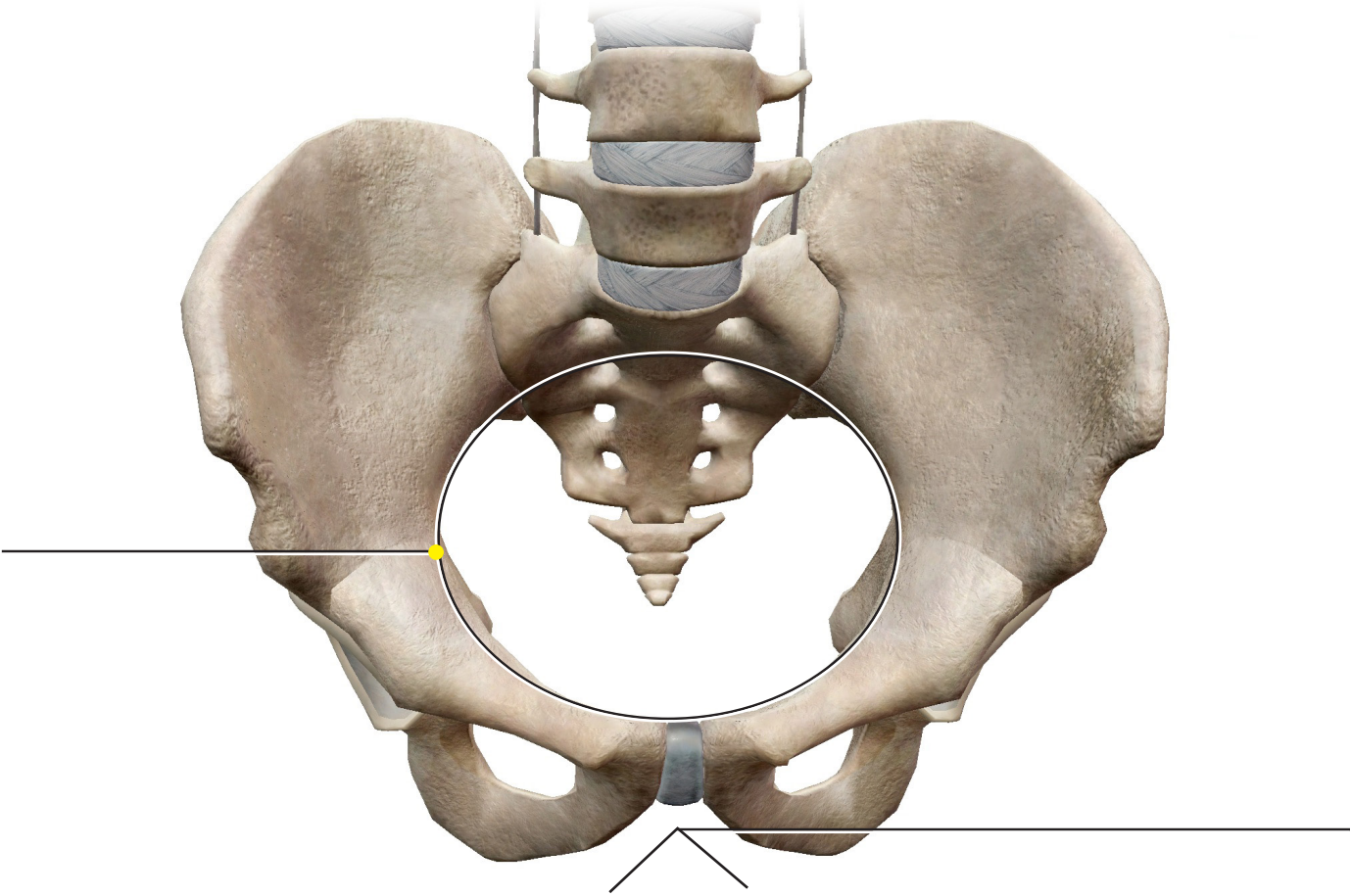
Ischium



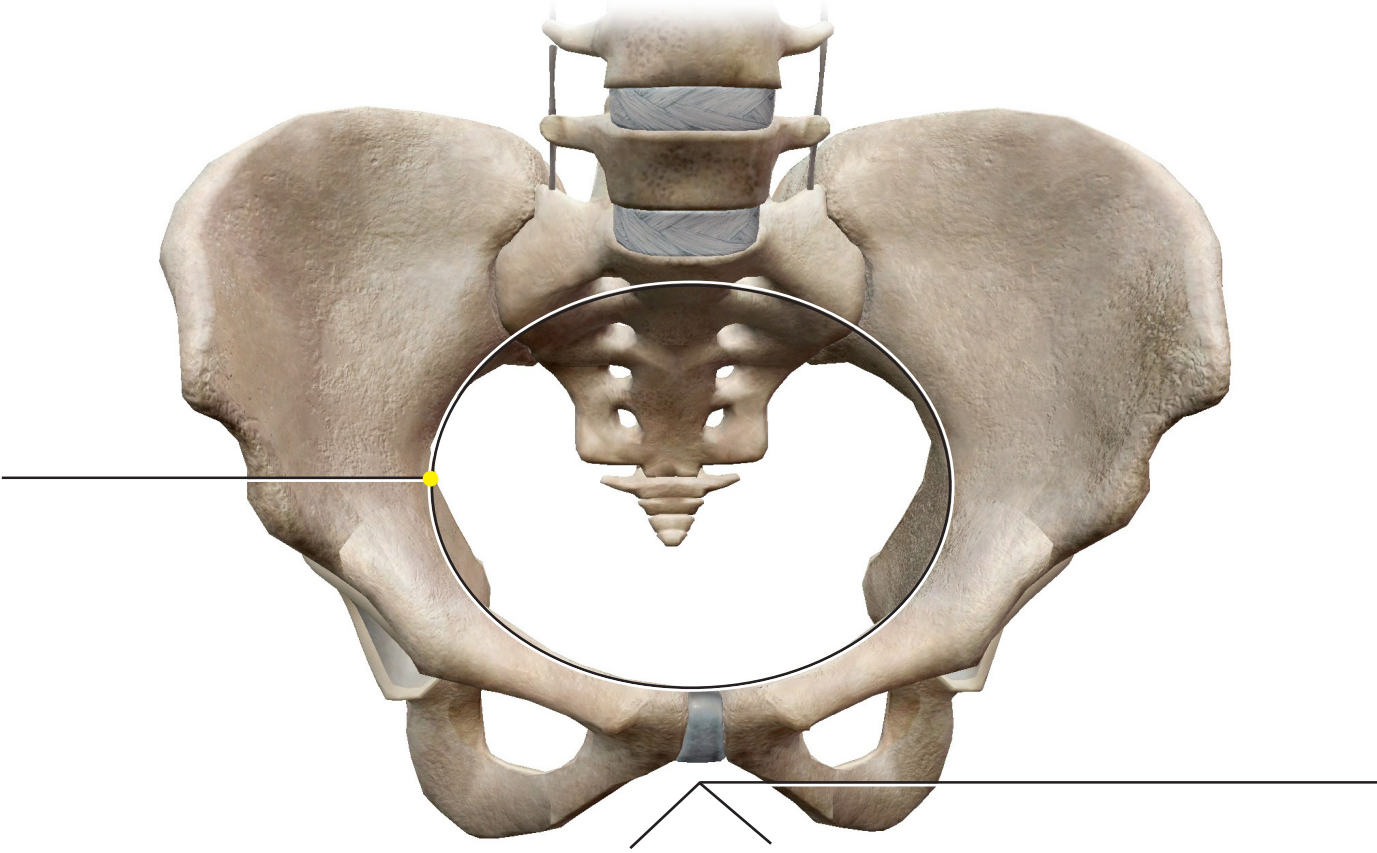
Pubis



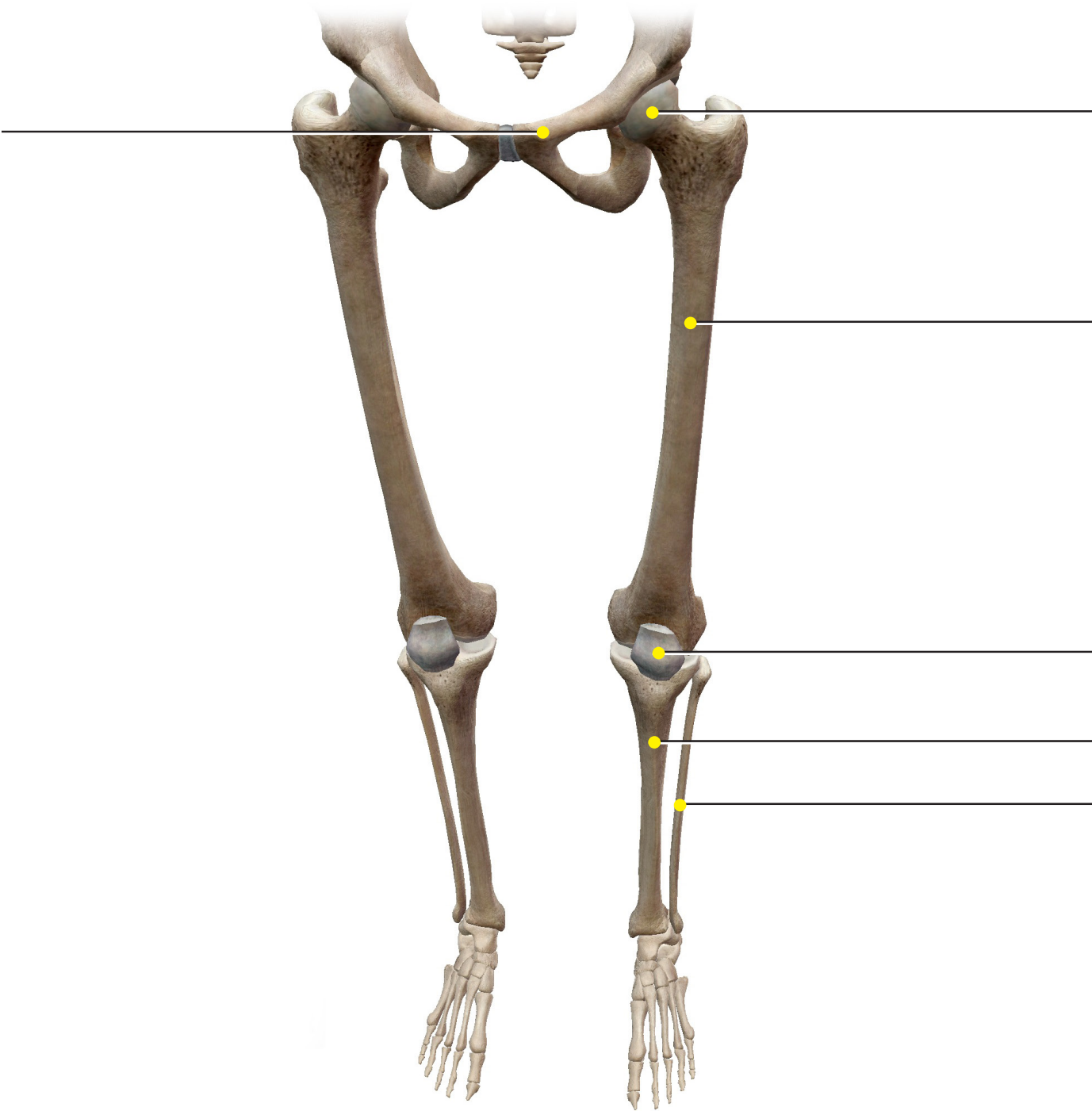
Source: Tour "Pelvis Comparison"



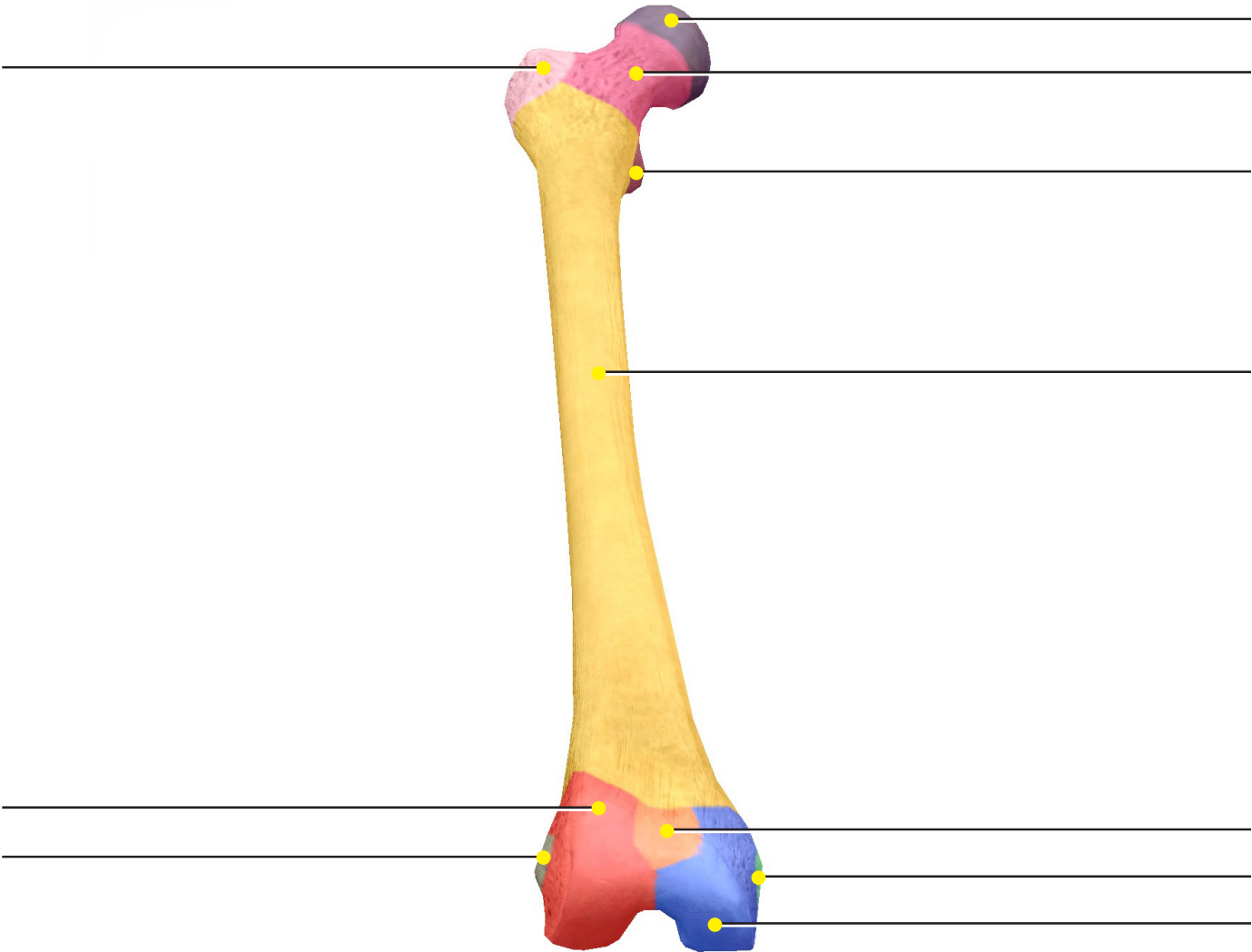
Source: Tour "Pelvis Comparison"



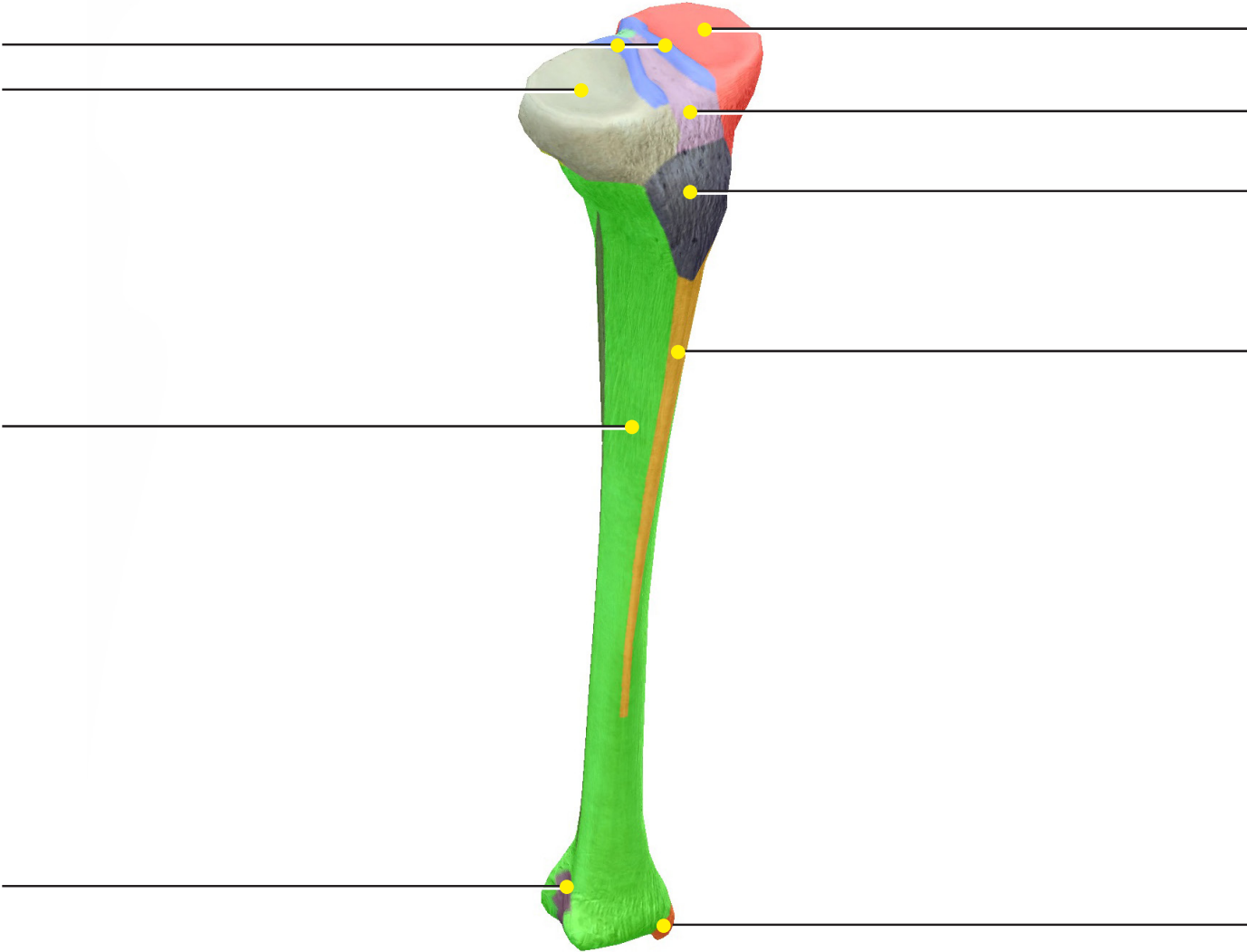
Source: Skeletal System View "Lower Limb"



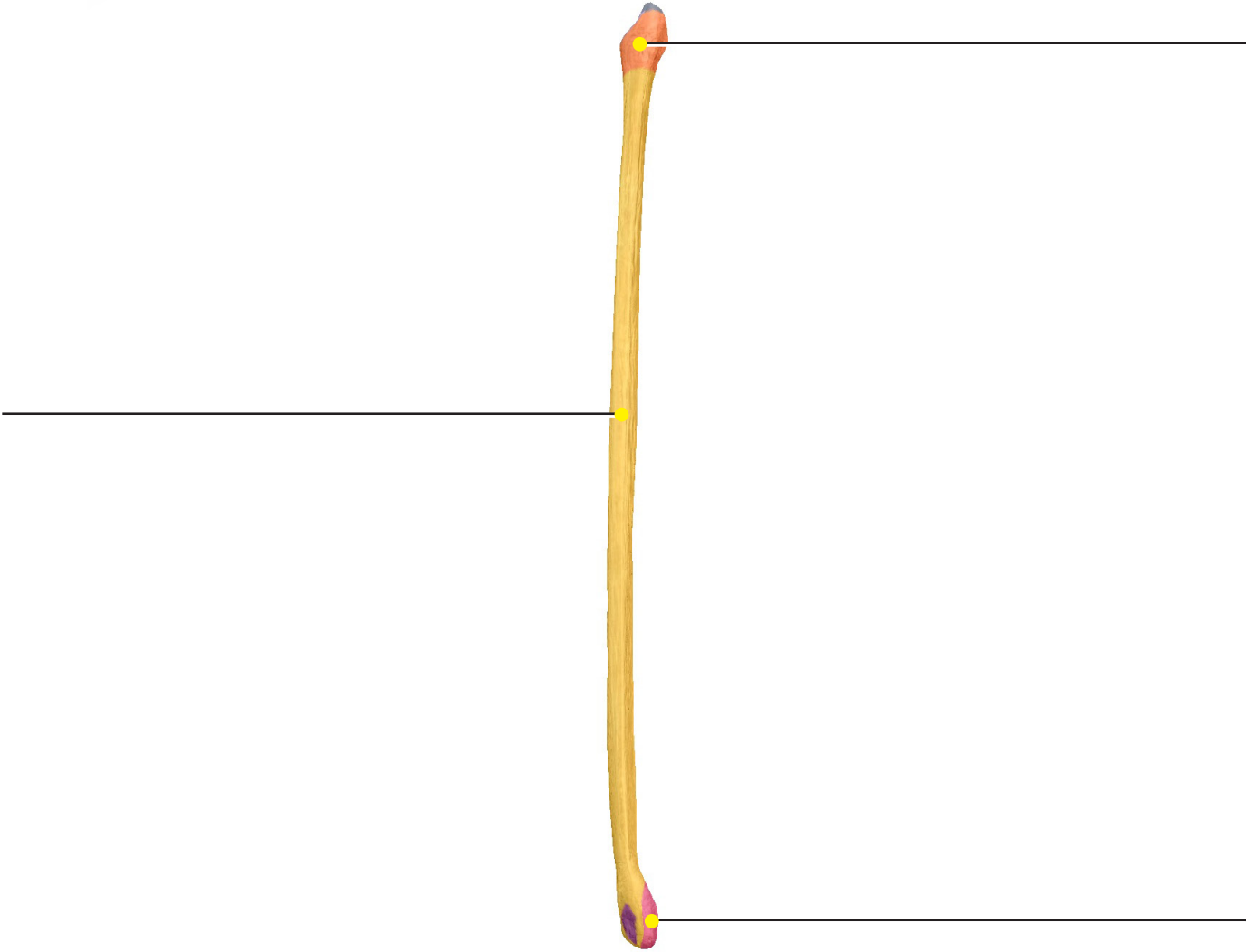
Femur



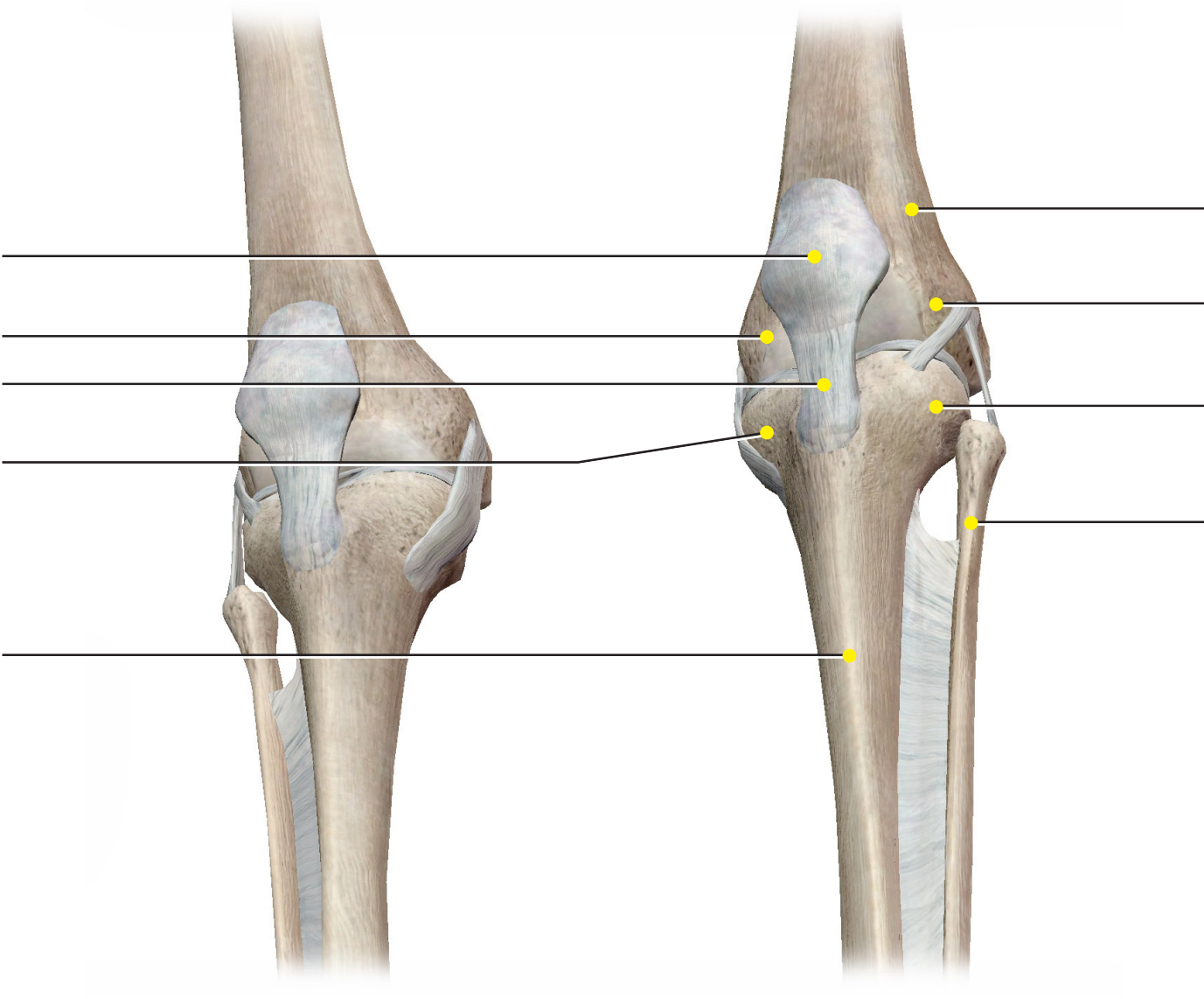
Tibia



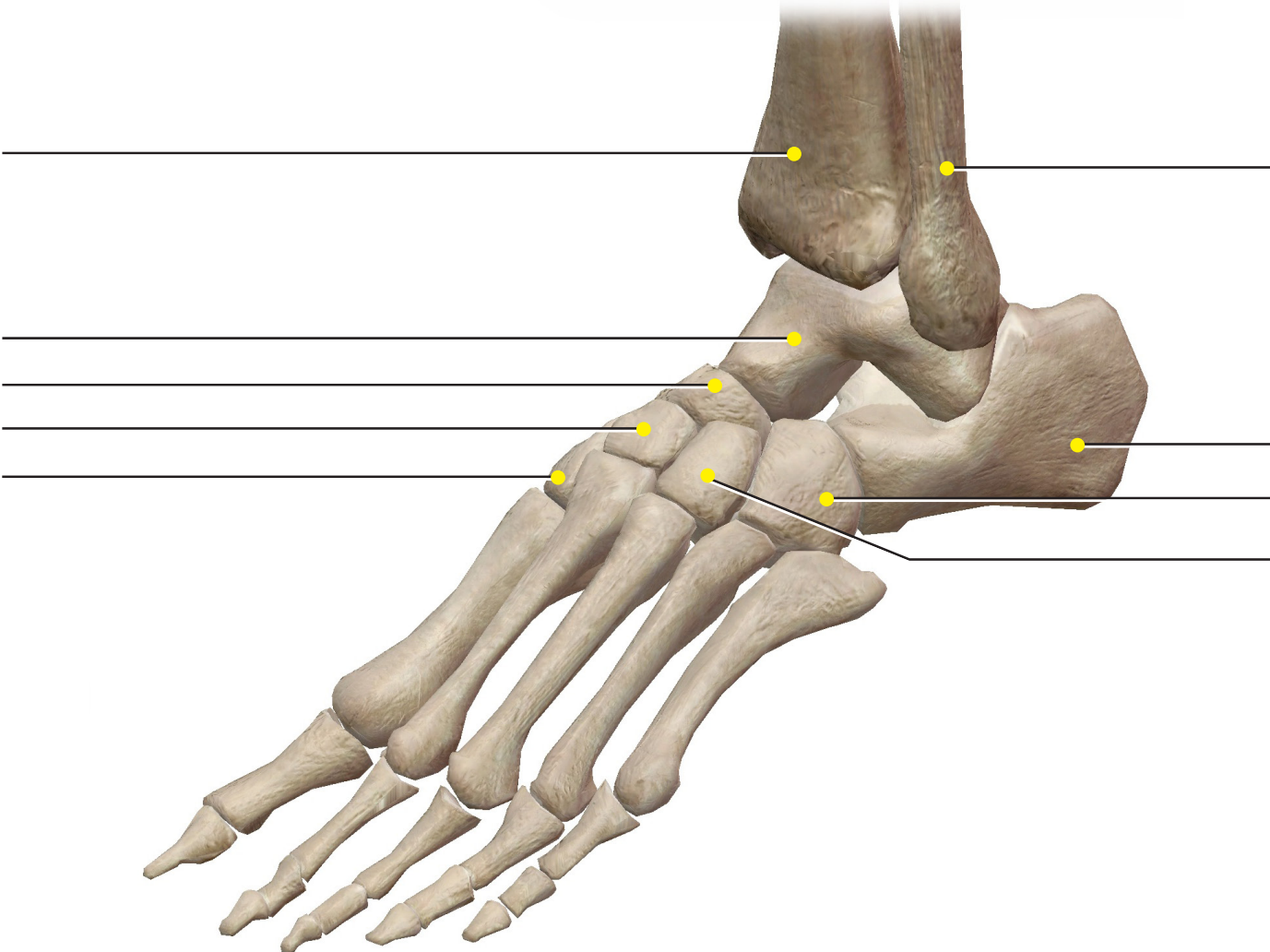
Fibula



Patella



Tarsus



Foot

