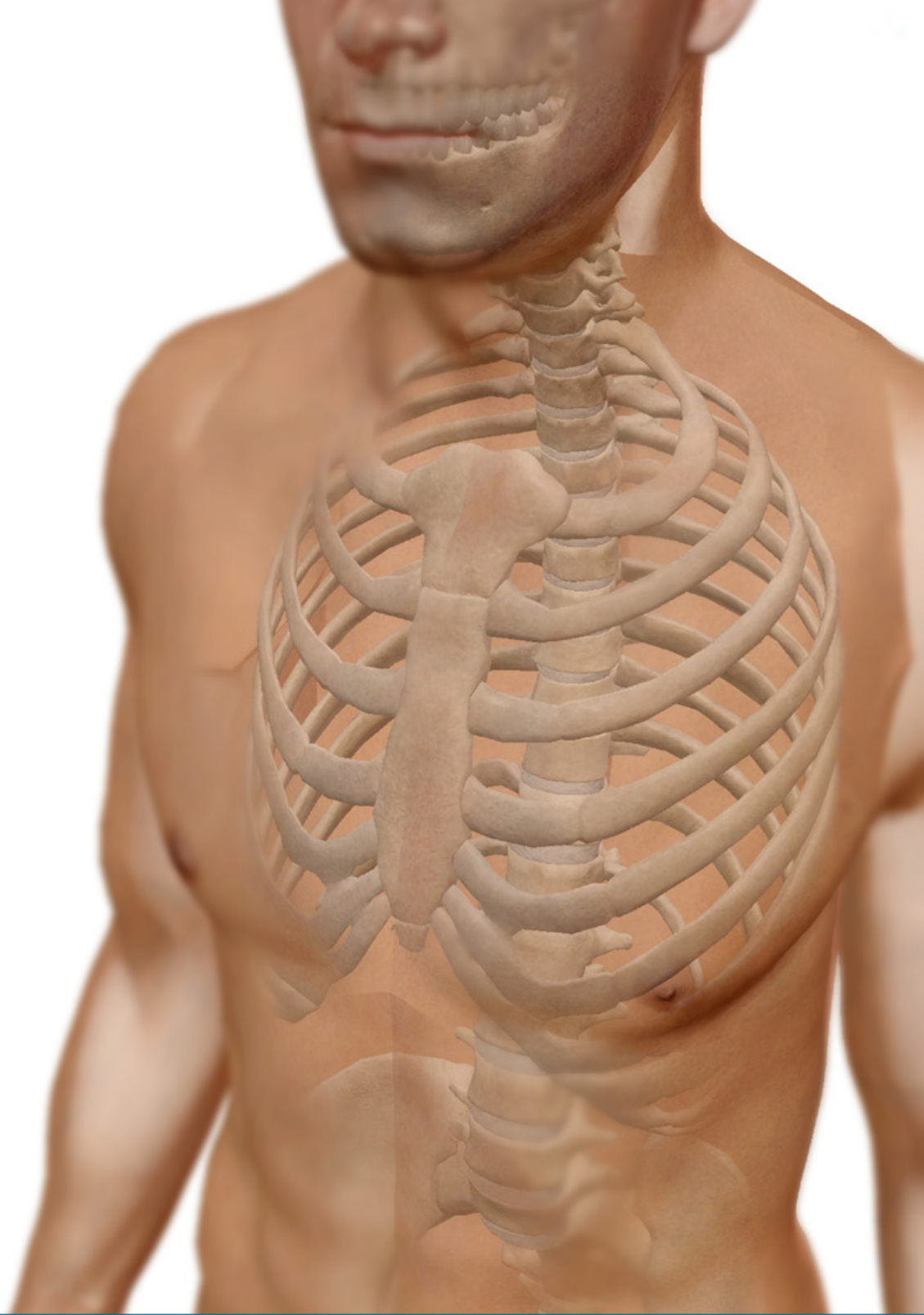



The Axial Skeleton

A skeletal system lab activity using Visible Body's Human Anatomy Atlas

Stephanie Wallace, Instructor of Biology, TCU

PRE-LAB EXERCISES

When studying the skeletal system, the bones are often sorted into two broad categories: the axial skeleton and the appendicular skeleton. This lab focuses on the axial skeleton, which consists of the bones that form the axis of the body. The axial skeleton includes bones in the skull, vertebrae, and thoracic cage, as well as the auditory ossicles and hyoid bone.

In addition to learning about all the bones of the axial skeleton, it is also important to identify some significant bone markings. Bone markings can have many shapes, including holes, round or sharp projections, and shallow or deep valleys, among others. These markings on the bones serve many purposes, including forming attachments to other bones or muscles and allowing passage of a blood vessel or nerve. It is helpful to understand the meanings of some of the more common bone marking terms.

Before we get started, look up the definitions of these common bone marking terms:

Canal:

Condyle:

Facet:

Fissure:

Foramen: (see Module 10.18 Foramina of Skull)

Fossa:

Margin:

Process:

Throughout this exercise, you will notice bold terms. This is meant to focus your attention on these important words. Make sure you pay attention to any bold words and know how to explain their definitions and/or where they are located.

Use the following modules to guide your exploration of the axial skeleton. As you explore these bones in Visible Body's app, also locate the bones and bone markings on any available charts, models, or specimens. You may also find it helpful to palpate bones on yourself or make drawings of the bones with the bone markings labeled. The drawings don't have to be perfect; just make sure the different bone markings are in the correct locations, relative to each other.

If you have trouble finding a bone or bone marking, don't forget you can always type its name into the search bar to get a list of 3D anatomical views where that bone or bone marking is highlighted for you.

To access disarticulated bones with color-coded bone markings, select a bone and then, in the content box, choose the landmark icon, which shows a bone with pink, yellow, and blue ends.

IN-LAB EXERCISES

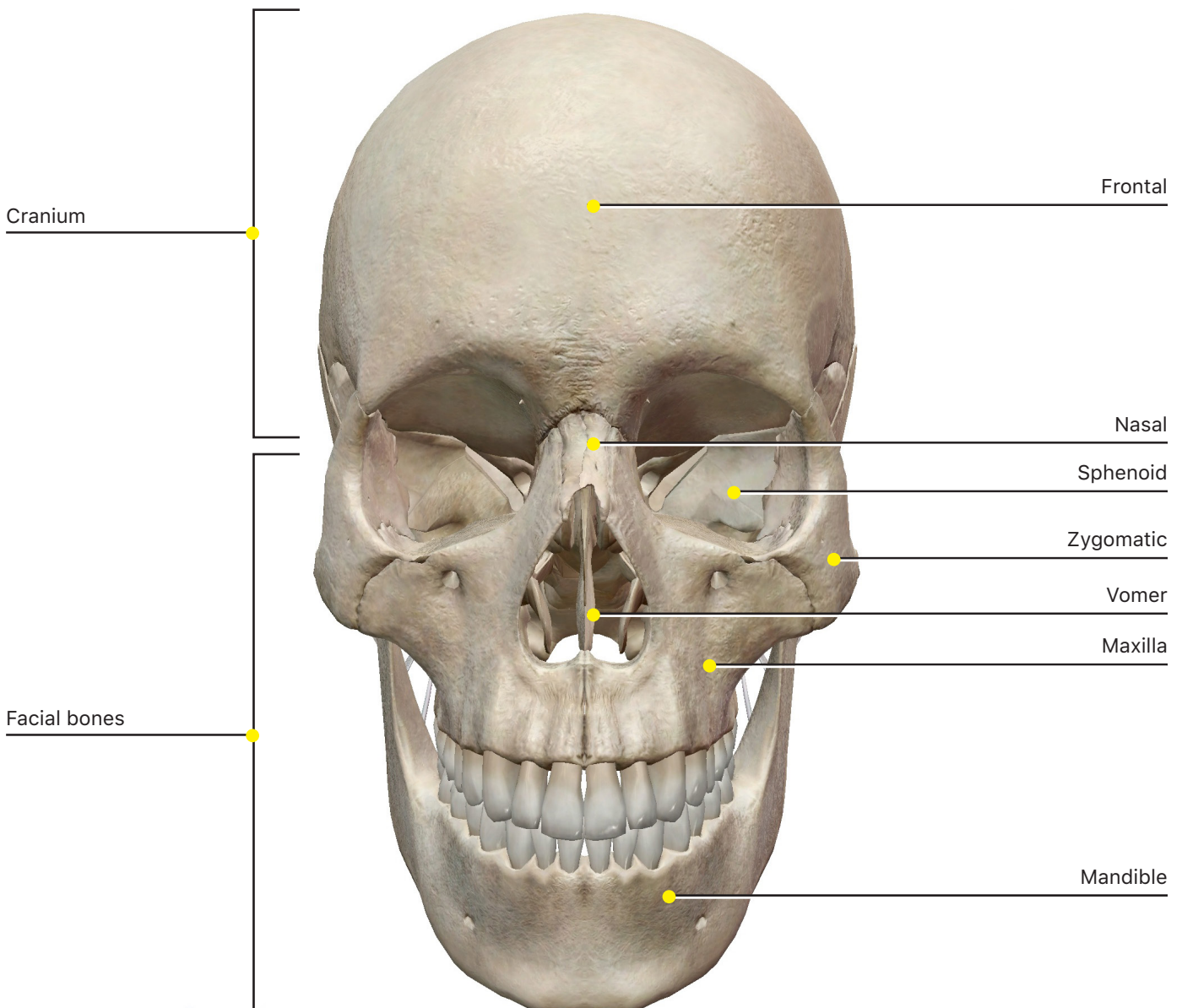
Open the Atlas app. From the Views menu, go to System Views to view the Skeletal System Views at the top of the screen.

You are responsible for the identification of **all bold terms**.

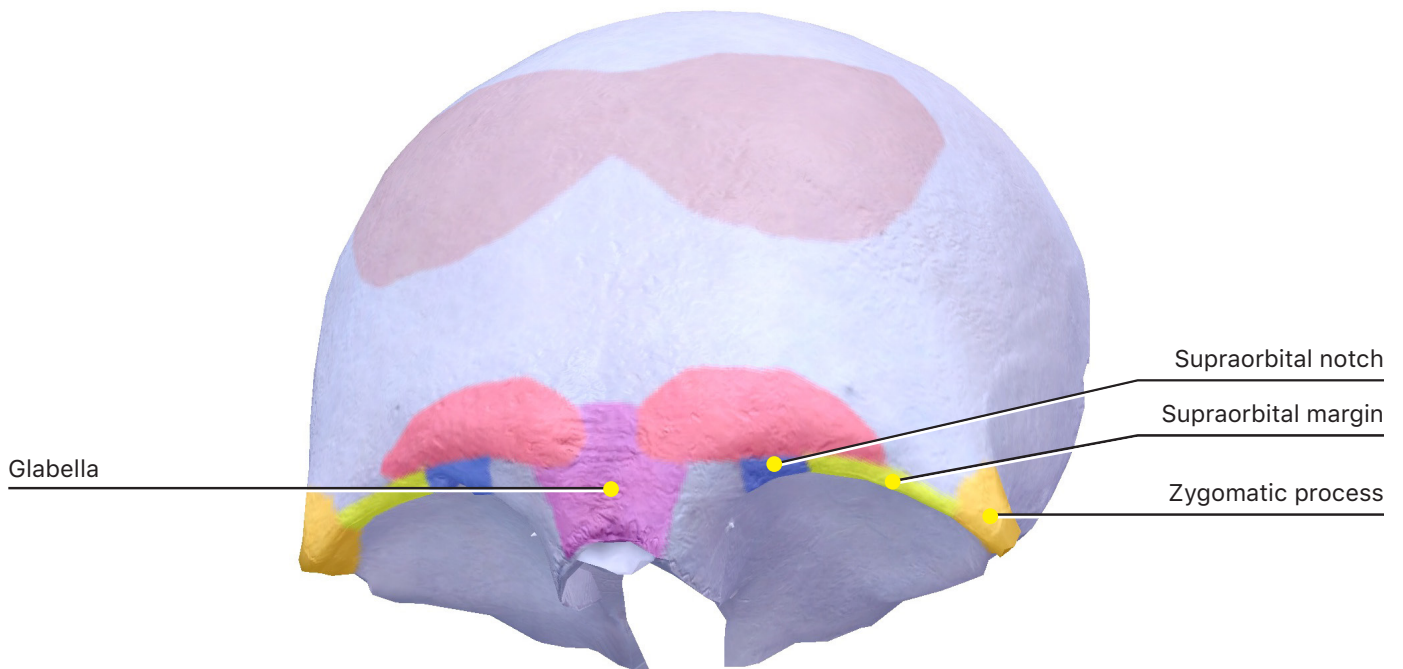
A. The Skull

The skull is composed of two parts: the **cranium** and the **facial bones**. The cranium is responsible for protecting the brain, while the facial bones form the framework of the face and support for the special senses (sight, smell, and taste).

In the Skeletal System Views, select View 2. Skull and locate the following skull bones and bone markings.



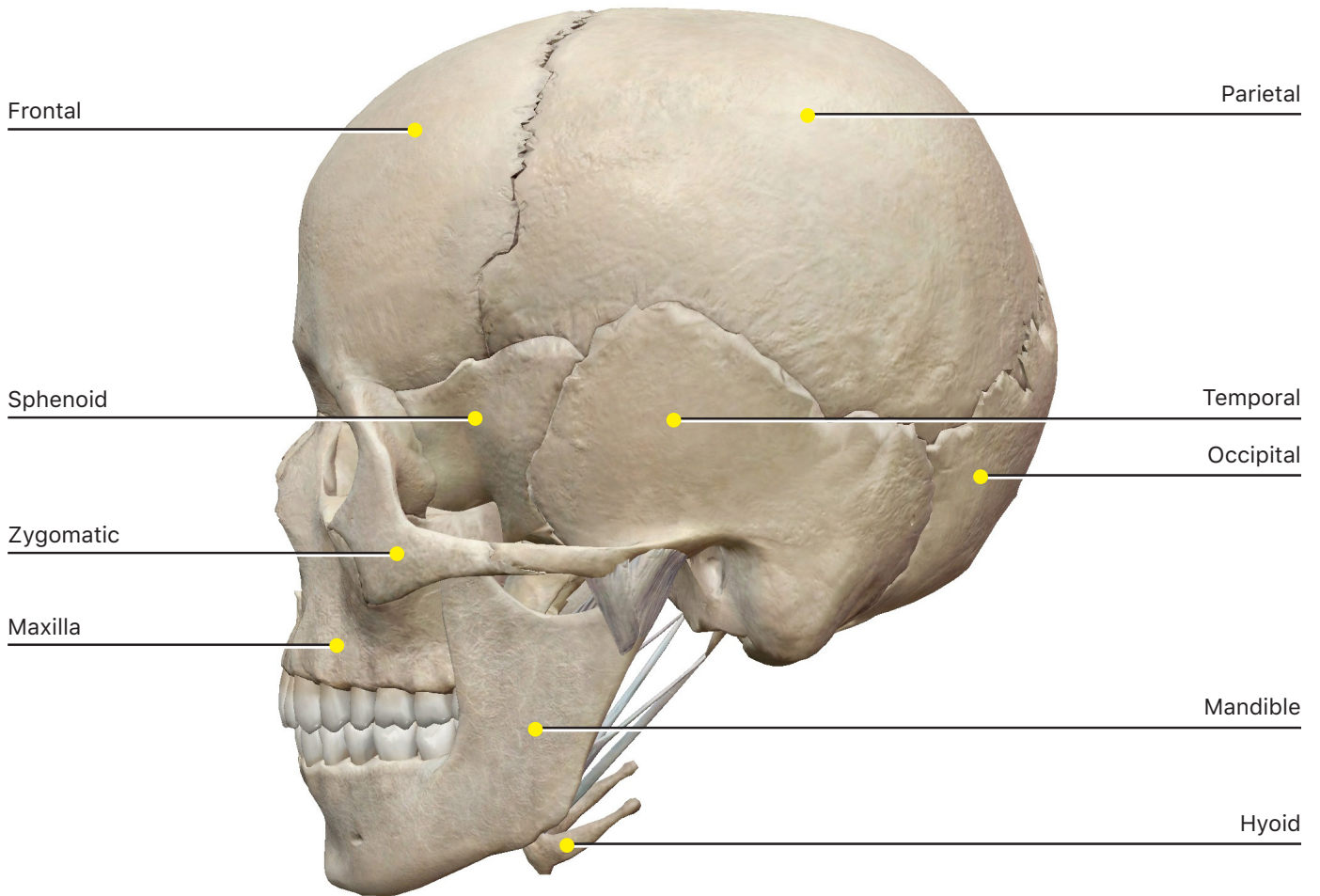
1. Cranial bones



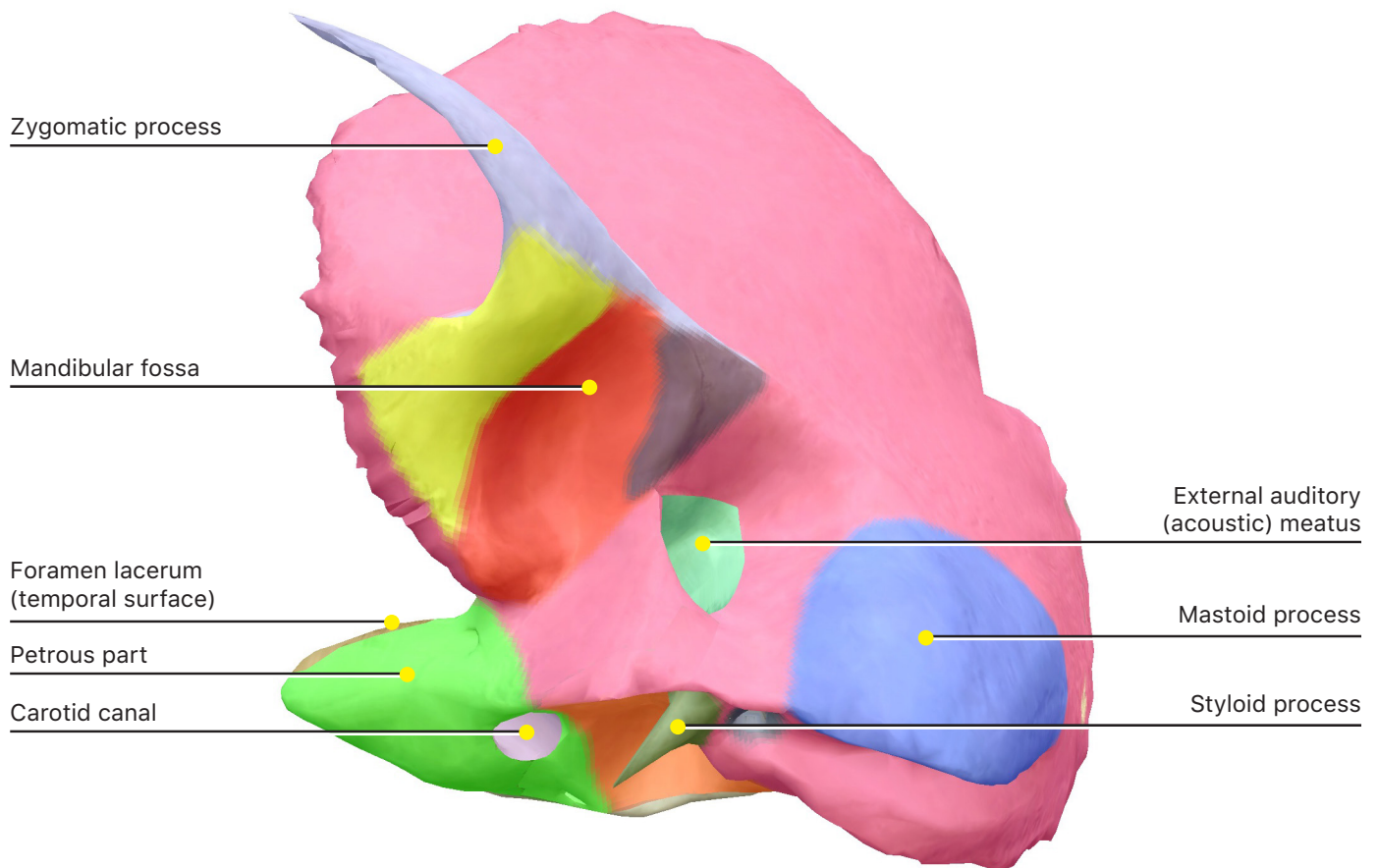
a. Select the **frontal bone**, which is located in the forehead region on the anterior and superior part of the skull. Use the landmark icon in the content box to locate the following bone markings:

- i. **Supraorbital notch**
- ii. **Supraorbital margin**
- iii. **Glabella**
- iv. **Zygomatic process**

b. Rotate the skull to see the lateral side and select the right or left **parietal bone**, located on the lateral and superior part of the skull.



c. Select the right or left **temporal bone**, which is located immediately inferior to the parietal bone.



i. Use the landmark icon in the content box to locate the following bone markings:

a. **Petrous part**

b. **Zygomatic process** (note how the zygomatic process of the temporal bone is different from the zygomatic process of the frontal bone)

c. **Mandibular fossa**

d. **External auditory (acoustic) meatus**

e. **Internal auditory (acoustic) meatus** (turn the model around to the medial side of the bone to find this)

f. **Styloid process**

g. **Mastoid process**

h. **Carotid canal**

i. **Jugular fossa**

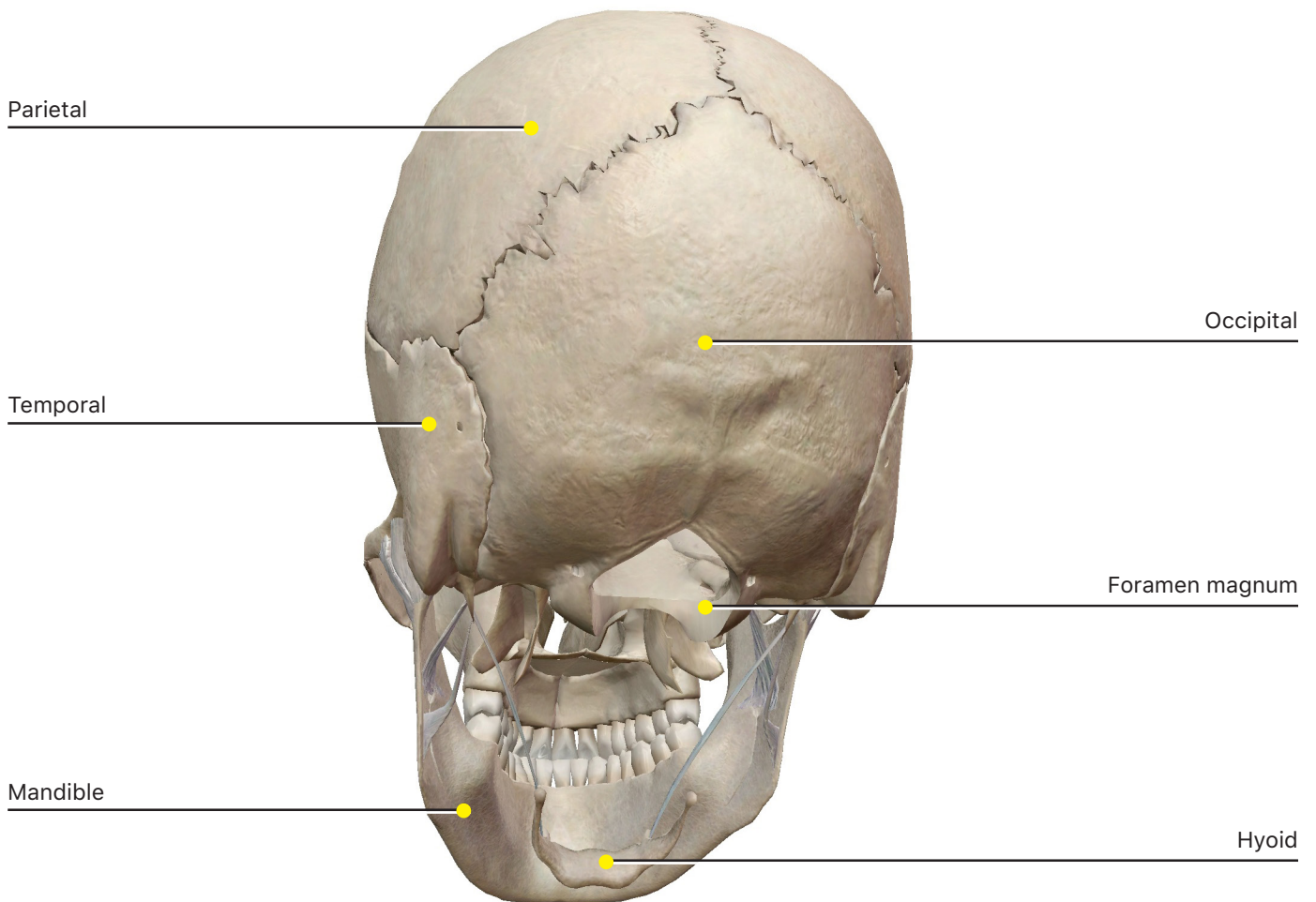
j. **Jugular foramen (temporal surface)**

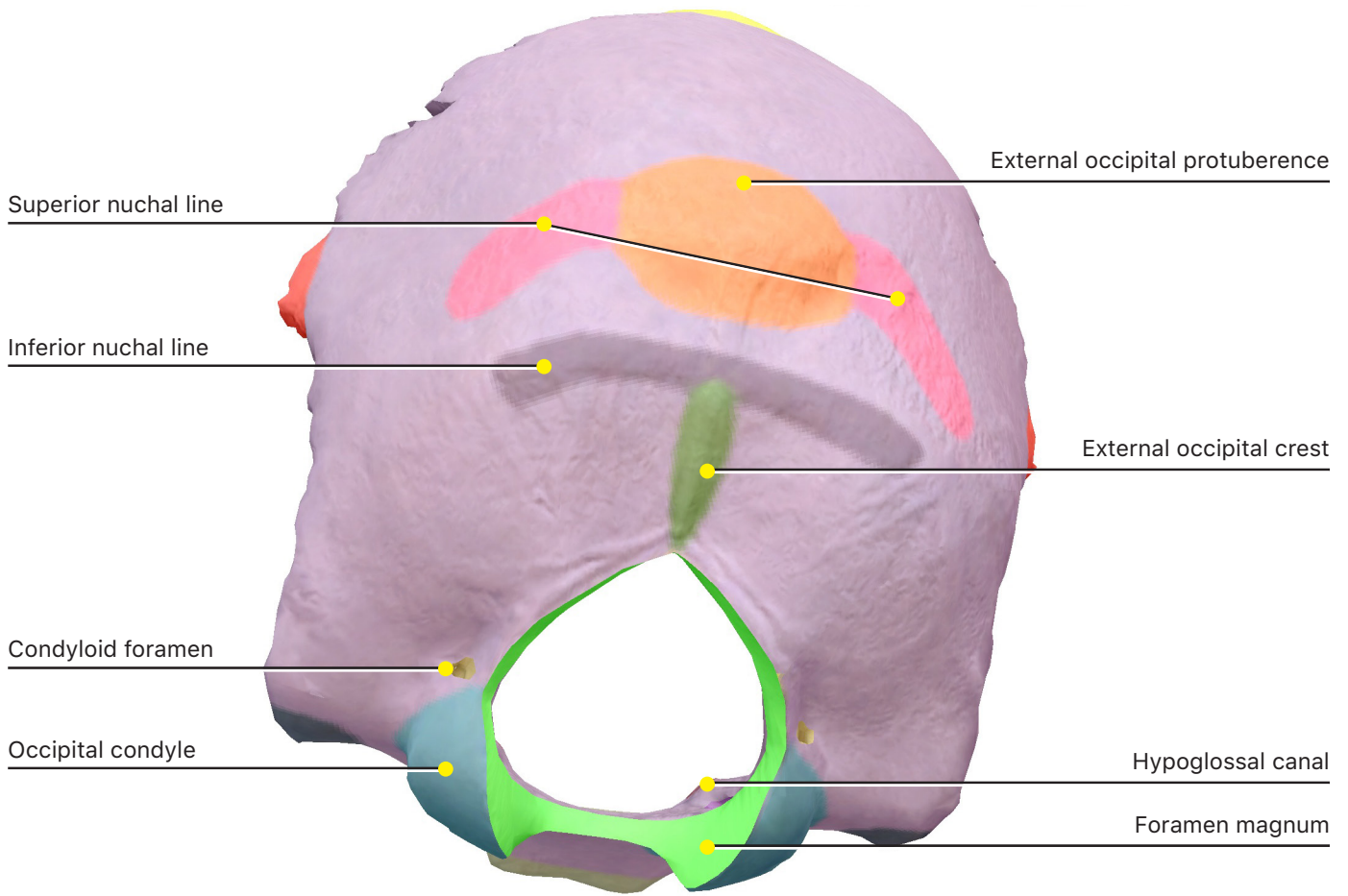
k. **Foramen lacerum (temporal surface)**

ii. Where does the lower jaw attach to the skull?

iii. Where do sound waves enter the ear?

d. Continue to rotate the skull and select the occipital bone, located on the posterior side of the skull.





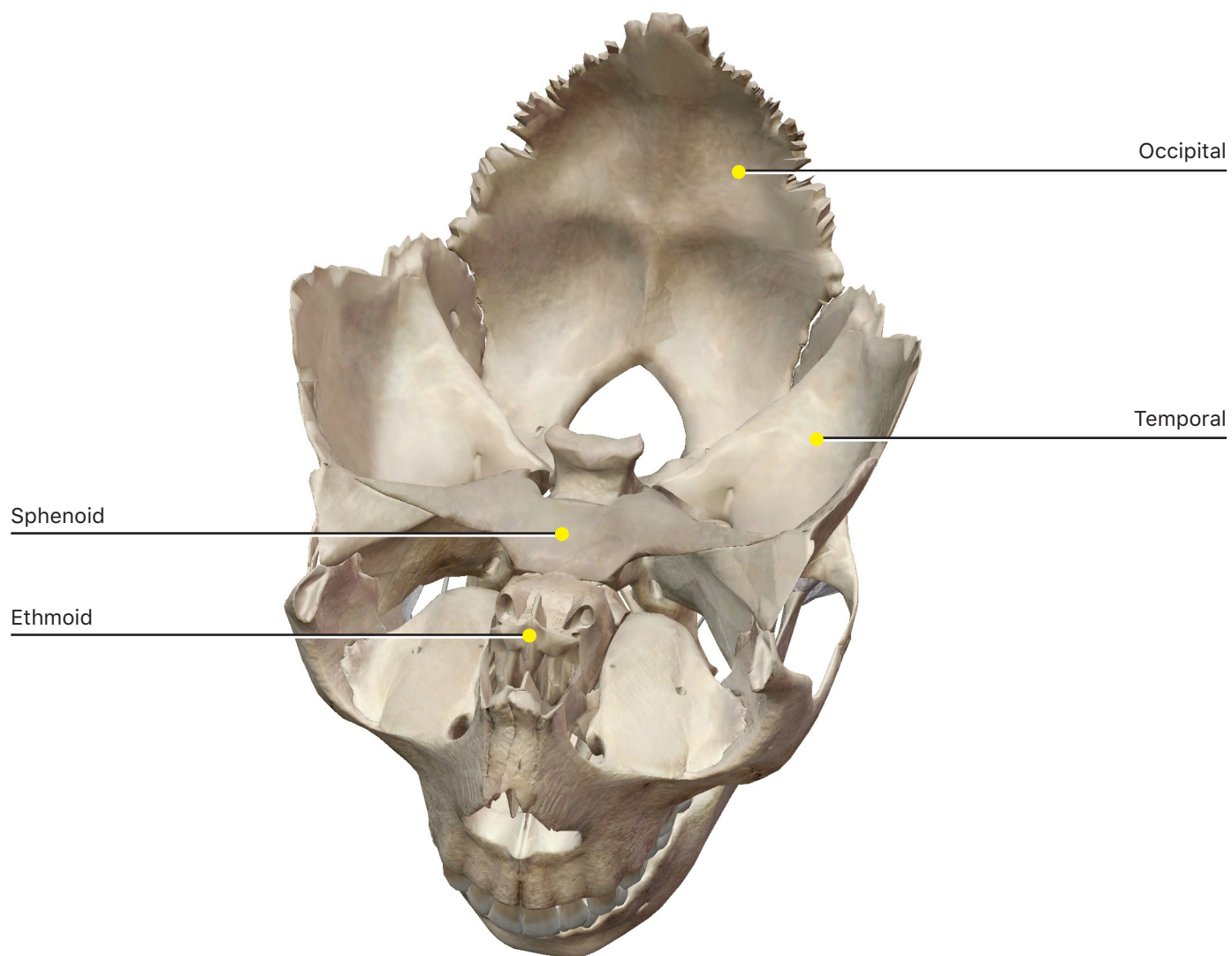
i. Use the landmark icon in the content box to locate the following bone markings:

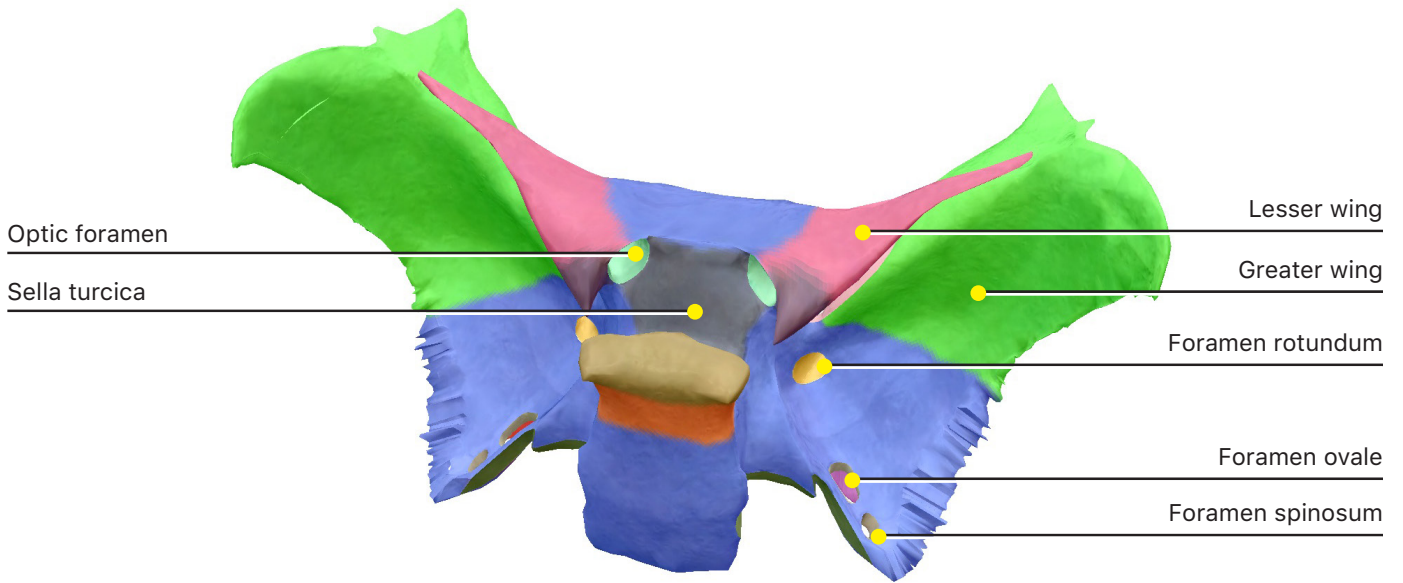
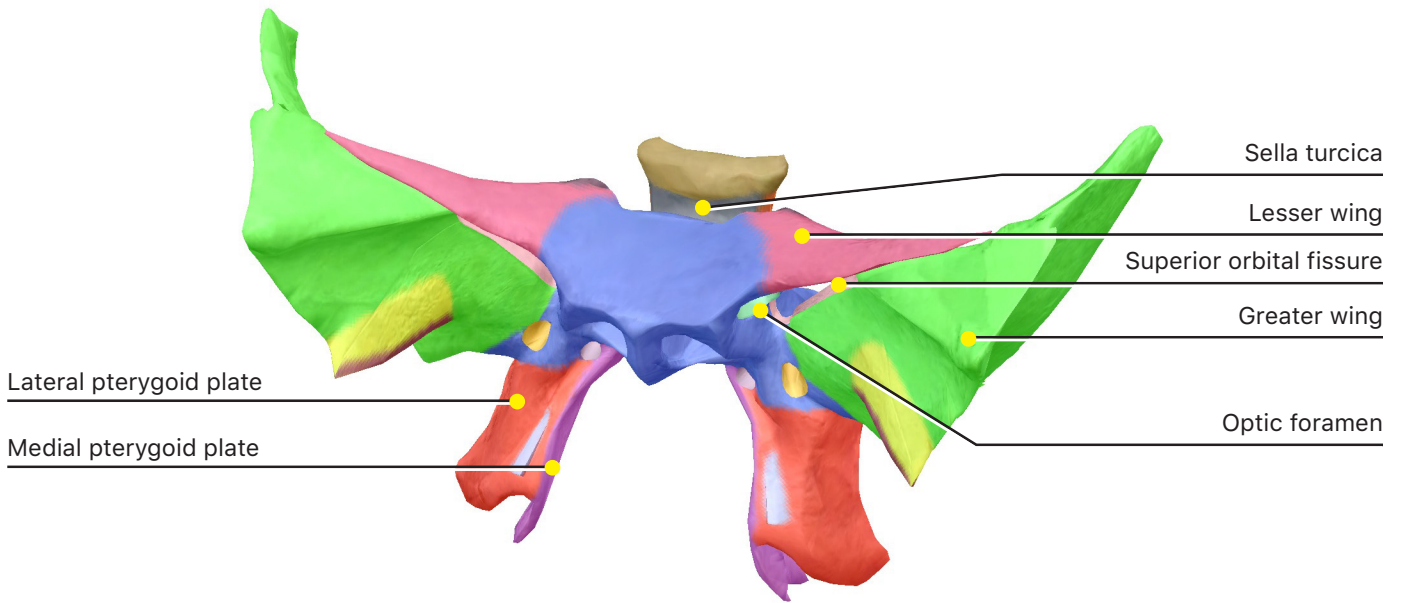
- a. **Foramen magnum**
- b. **Hypoglossal canal**
- c. **Occipital condyle**
- d. **Condyloid foramen**
- e. **External occipital protuberance**
- f. **Inferior nuchal line**
- g. **Superior nuchal line**
- h. **Jugular foramen (occipital surface)**
- i. **Foramen lacerum (occipital surface)**

ii. What structure passes through the foramen magnum?

iii. What structure is responsible for articulating with the vertebral column?

e. Rotate the skull to look at the superior (top) surface. Select and hide the frontal bone and the two parietal bones and choose the sphenoid bone, which is shaped like a butterfly.



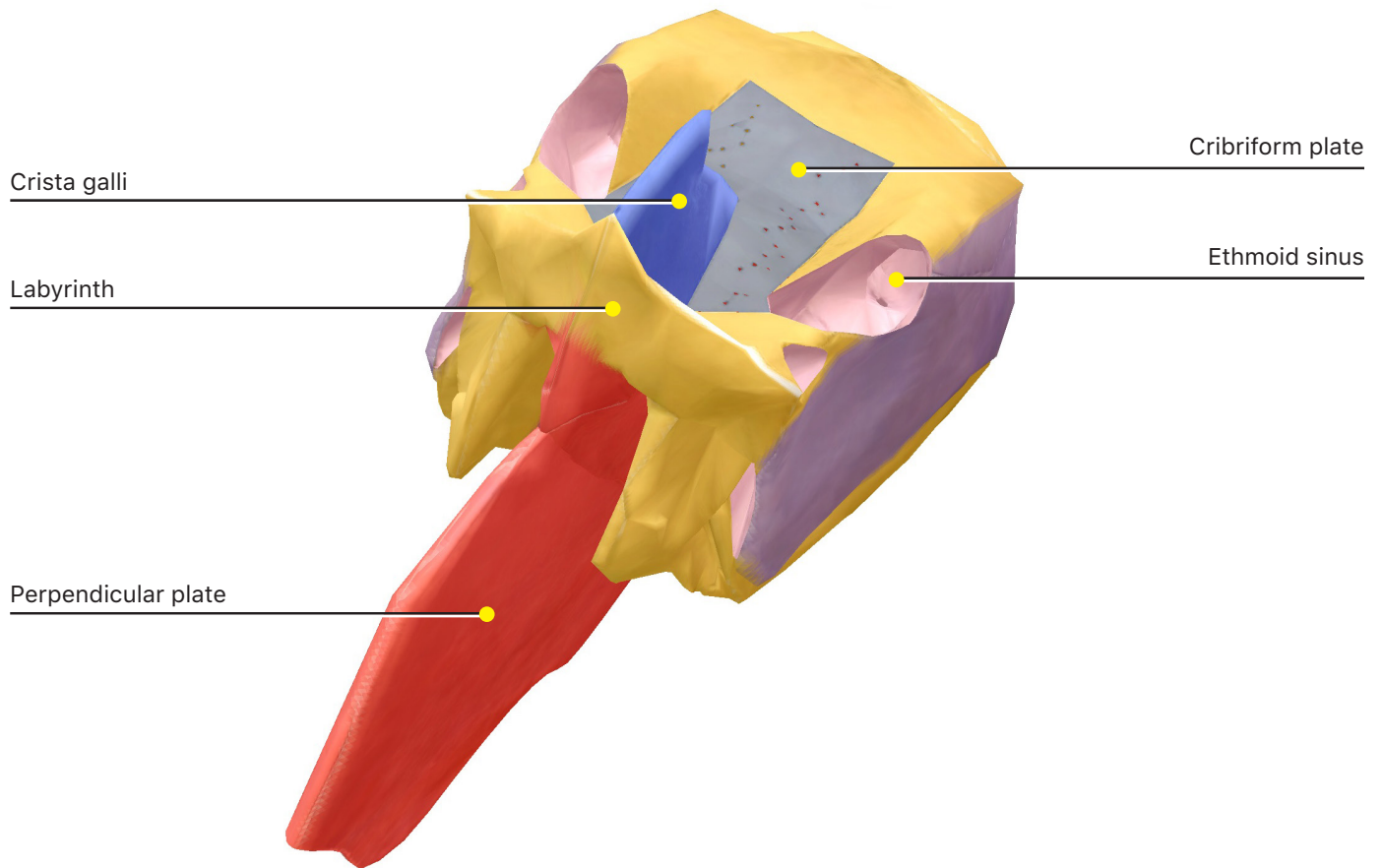


i. Use the landmark icon in the content box to locate the following bone markings:

- a. **Greater wing**
- b. **Lesser wing**
- c. **Sella turcica**
- d. **Dorsum sellae**
- e. **Optic foramen**
- f. **Superior orbital fissure**
- g. **Inferior orbital fissure (sphenoid surface)**
- h. **Foramen rotundum**
- i. **Foramen ovale**
- j. **Foramen spinosum**
- k. **Foramen lacerum (sphenoidal surface)**
- l. **Medial pterygoid plate**
- m. **Lateral pterygoid plate**

ii. The pituitary gland is nicknamed the “master gland” of the body because it secretes many hormones that have widespread effects in the body. Which part of the sphenoid bone houses it?

f. Select the **ethmoid bone**, which is located anterior to the sphenoid bone between the orbits of the eyes.

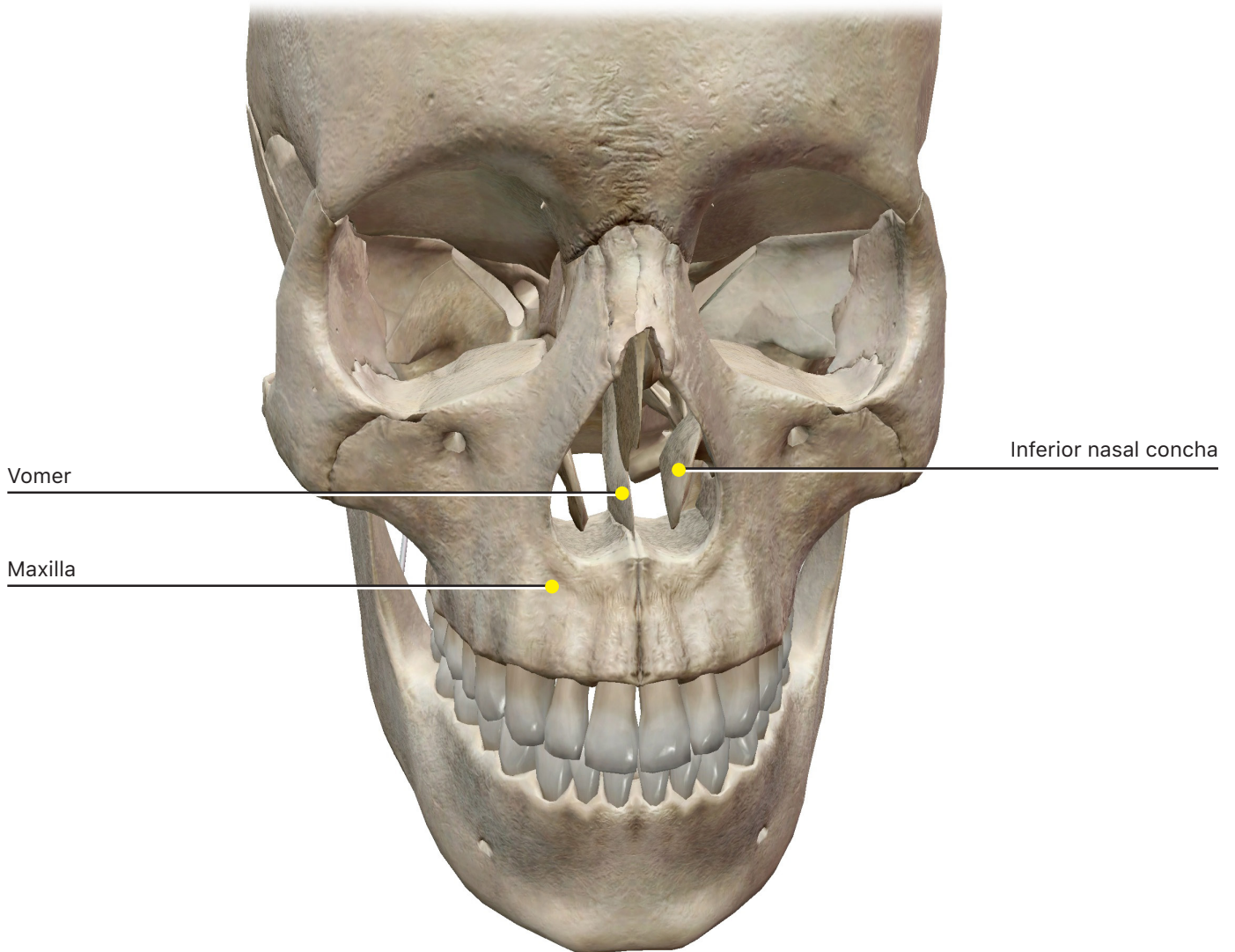


i. Use the landmark icon in the content box to locate the following bone markings:

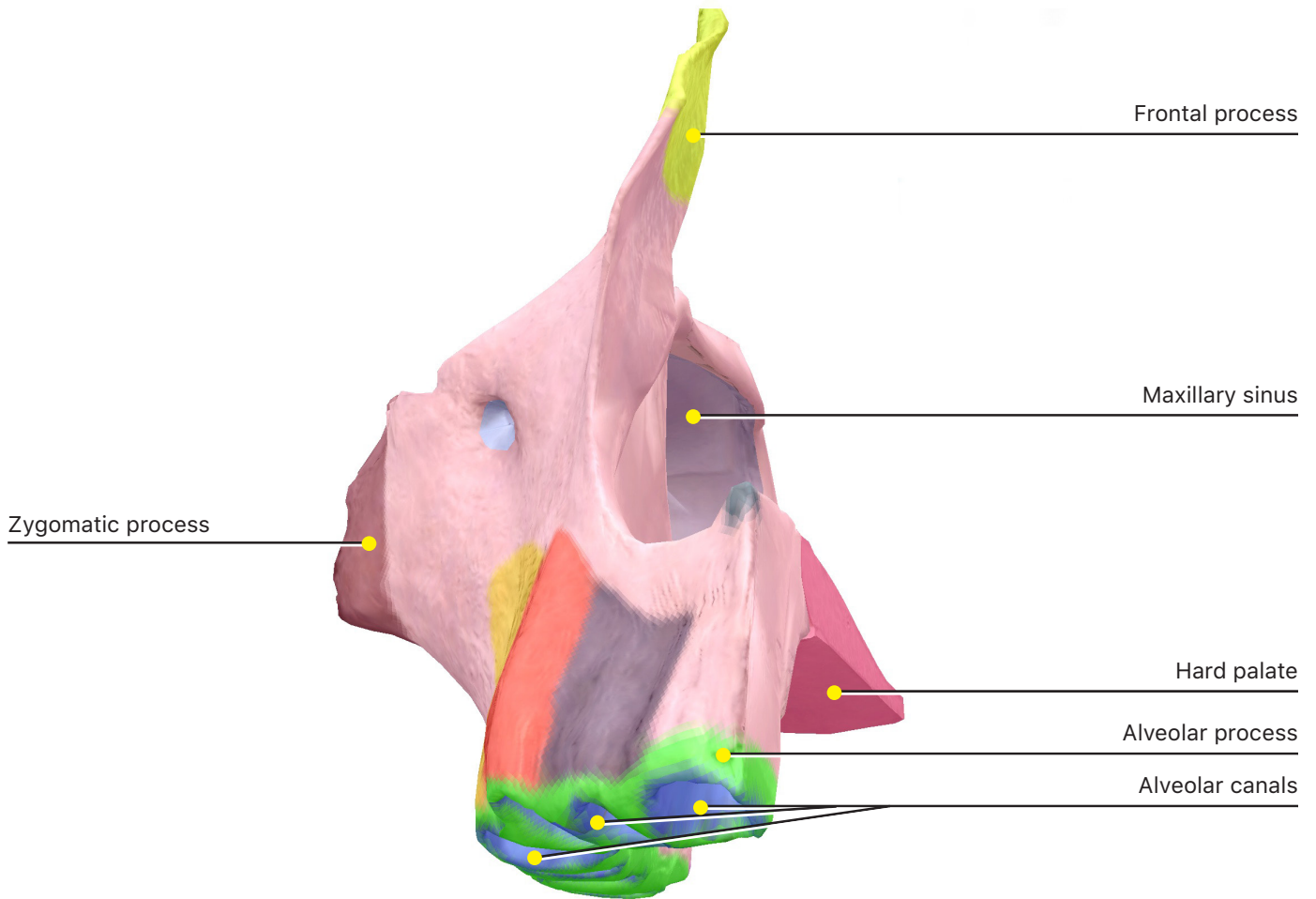
- a. **Crista galli**
- b. **Cribriform plate**
- c. **Middle nasal concha**
- d. **Labyrinth**
- e. **Perpendicular plate**

i. Use the landmark icon in the content box to locate the following bone markings:

2. Facial bones



- Rotate the skull, so you're looking at the anterior (face) side again. Zoom into the nose area and select one of the **inferior nasal conchae bones**, which stick out toward the inside of the nose.
- Select the **vomer**, which is located medial to the two inferior nasal conchae in the nose.
- Select one of the **maxillae** bones, which form the upper jaw.



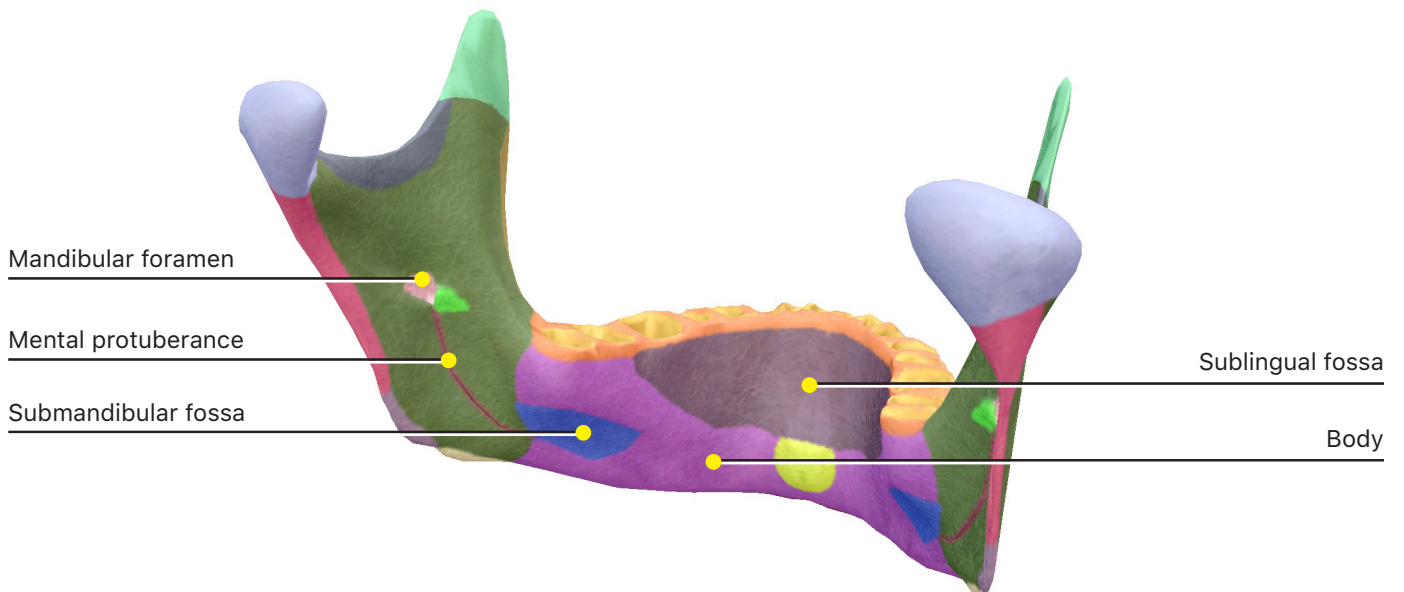
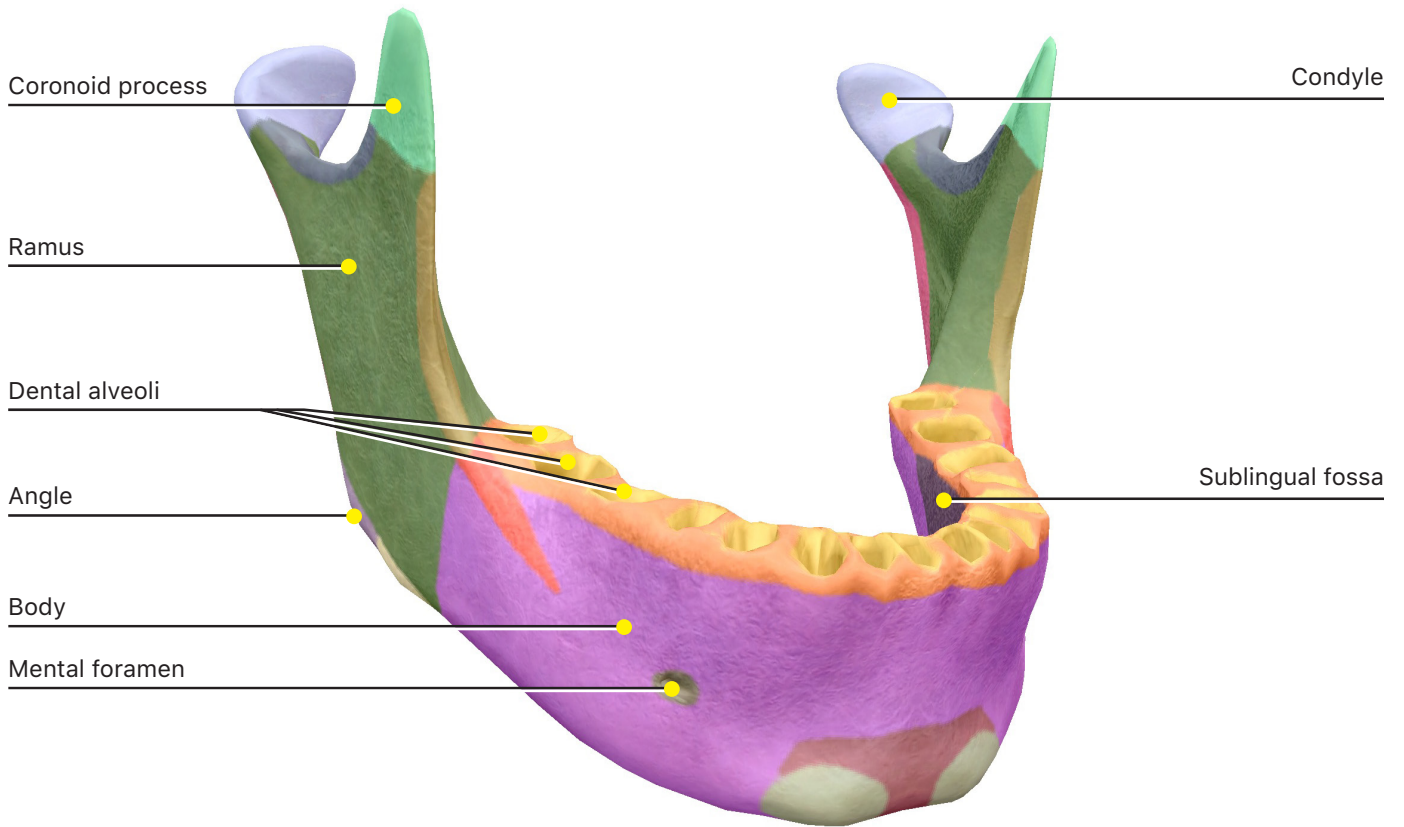
i. Use the landmark icon in the content box to locate the following bone markings:

- a. **Alveolar canal**
- b. **Alveolar process**
- c. **Zygomatic process** (note how this is different from the zygomatic processes of the frontal and temporal bones, but all point toward the zygomatic bone)
- d. **Frontal process**
- e. **Hard palate**
- f. **Inferior orbital fissure (maxillary surface)**
- g. **Infraorbital canal and foramen**
- h. **Maxillary sinus**

ii. What structures insert into the alveolar canal?

iii. What structure forms the roof of the mouth?

d. Select the **mandible**, which forms the lower jaw

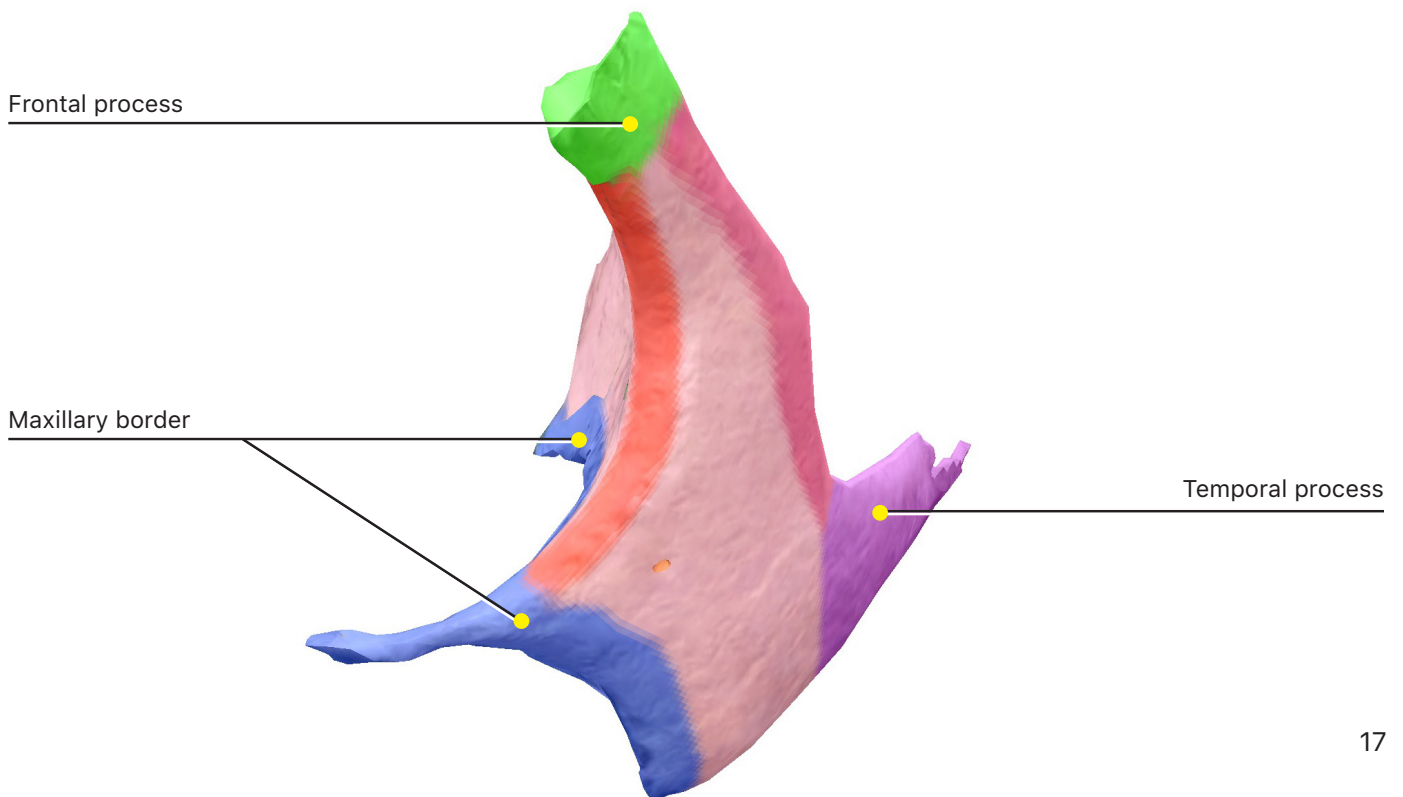
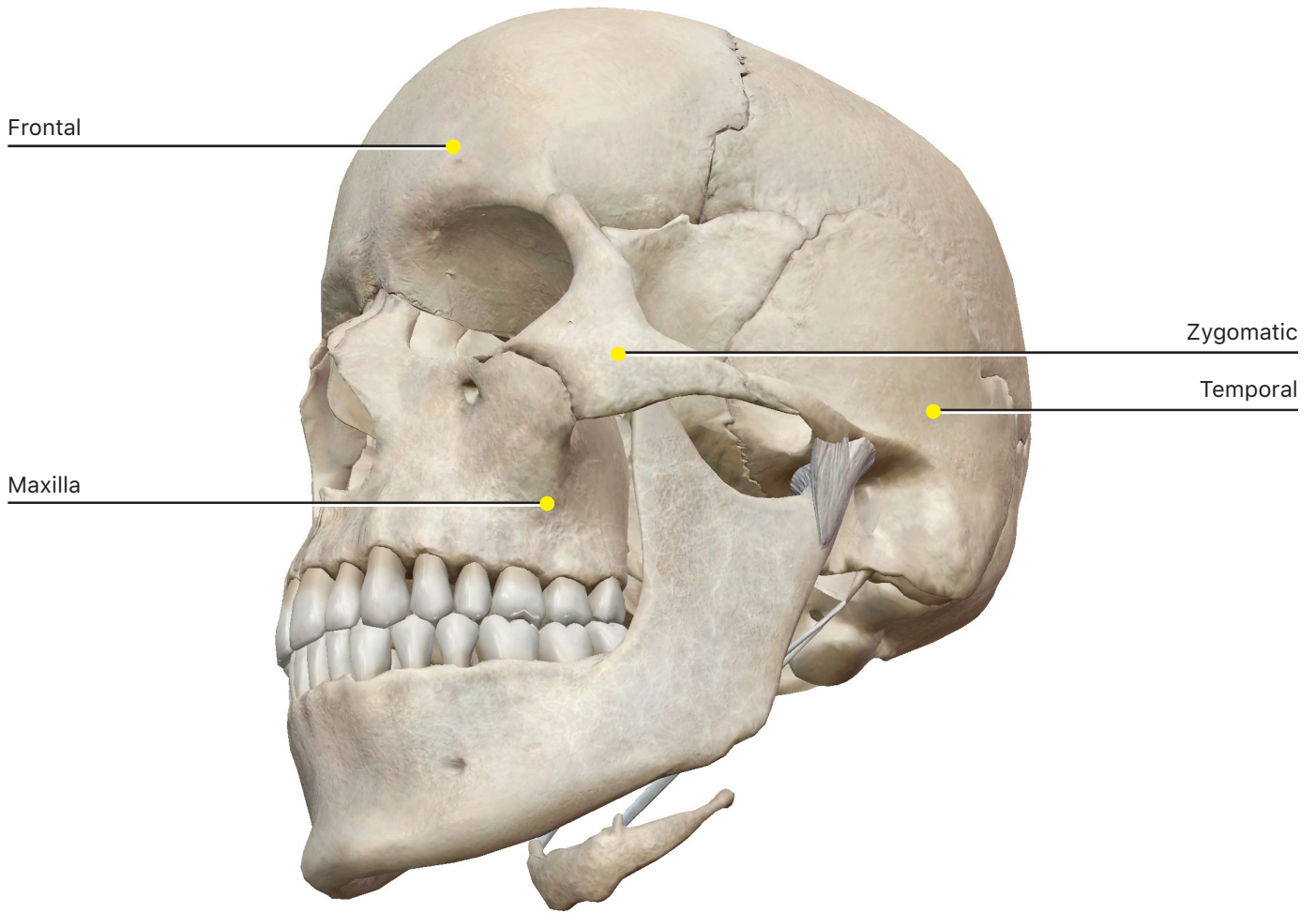


i. Use the landmark icon in the content box to locate the following bone markings:

- a. **Body**
- b. **Ramus**
- c. **Angle**
- d. **Sublingual fossa**
- e. **Coronoid process**
- f. **Condyle**
- g. **Dental alveoli**
- h. **Mandibular foramen**
- i. **Mental foramen**

ii. Which part of the mandible attaches to the cranium? Where does it articulate?

e. Select one of the **zygomatic bones**, which form part of the cheekbones of the face. The zygomatic bones are shaped roughly like triangles, with each vertex pointing toward a different bone: the temporal bone, maxilla, or frontal bone. Use the landmark icon in the content box to locate the following bone markings:



i. **Temporal process**

ii. **Maxillary border**

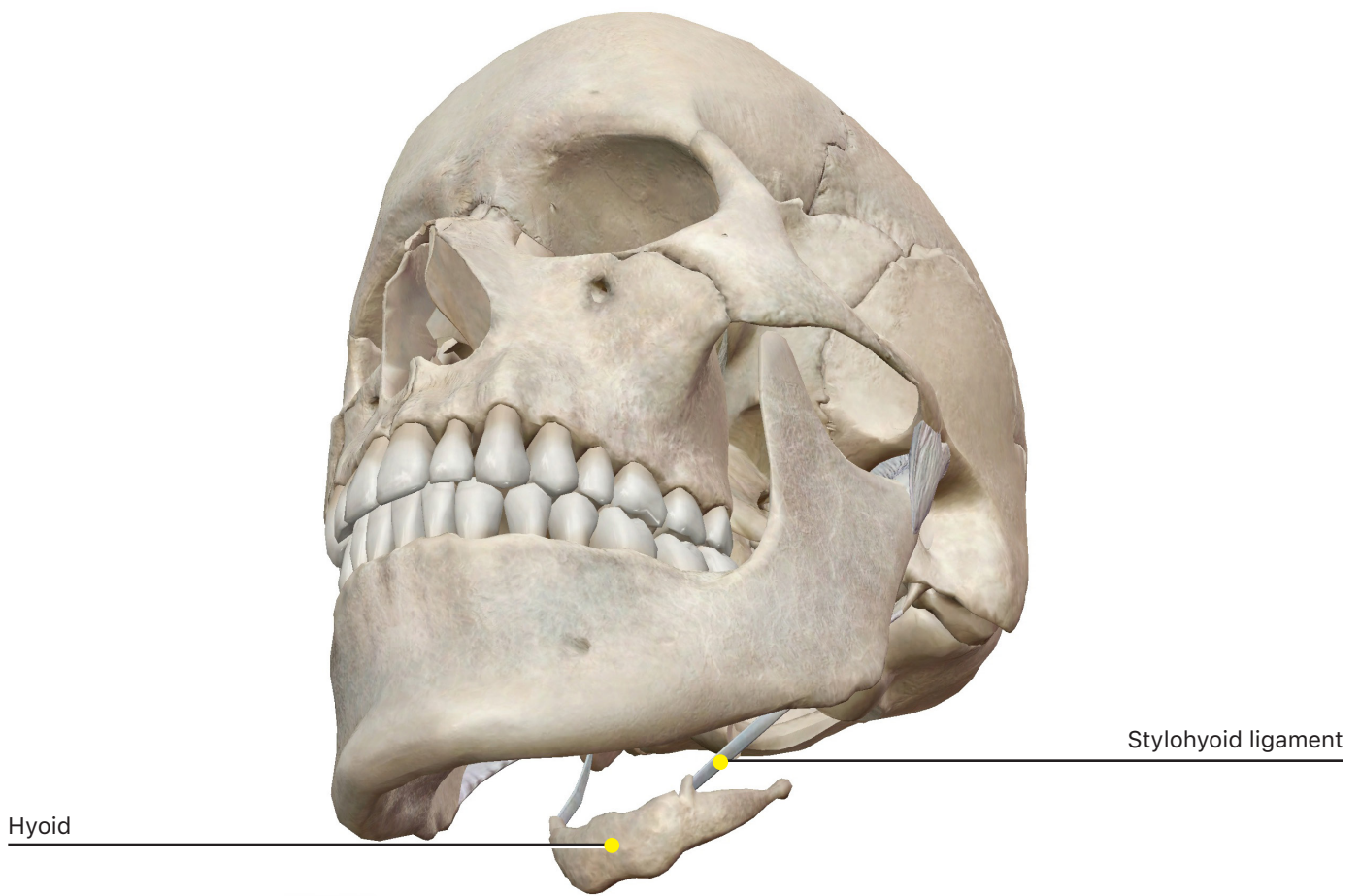iii. **Frontal process**

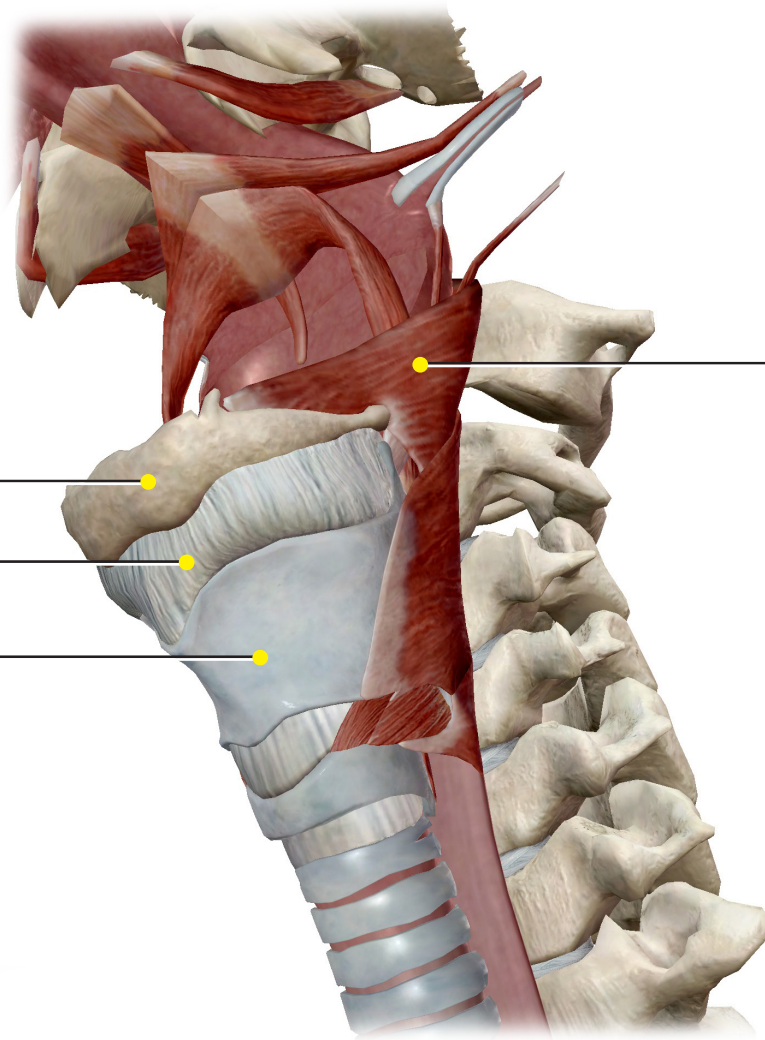
f. Locate the small **nasal bones** on the bridge of the nose.

g. Locate the **lacrimal bones** next to the frontal processes of the maxillae.

h. Locate the **palatine bones**, which are posterior to the hard palate of the maxillae.

3. Rotate the skull, so you are looking at the inferior side and find the **hyoid** bone, which is attached by only ligaments. For a better view of the hyoid in relation to its function, go back to the Systems menu, scroll down to the Respiratory System Views, and select view 4. Pharynx and Larynx. Although the hyoid does not articulate with any other bones, notice how many muscles and ligaments attach to the hyoid.





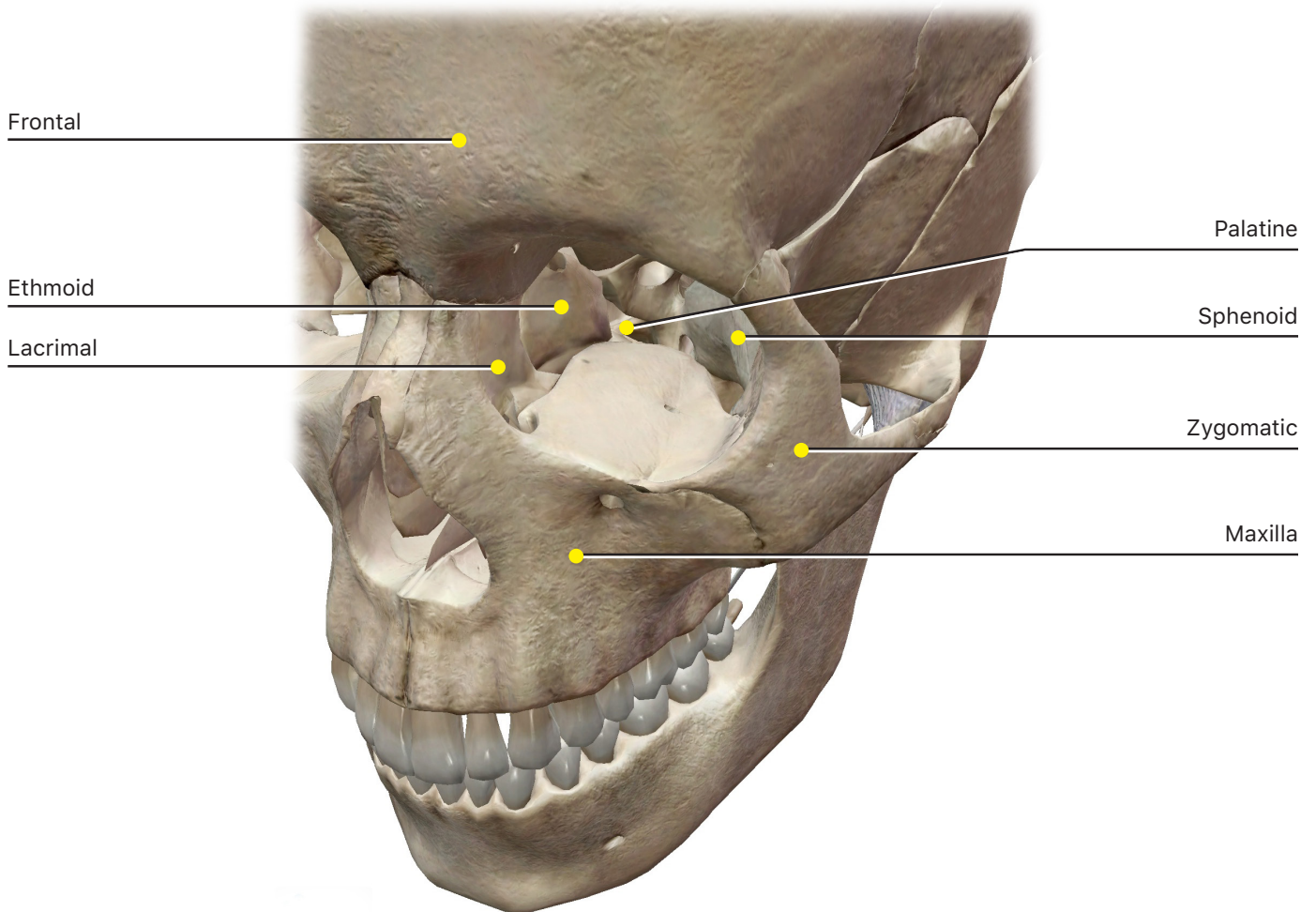
Middle pharyngeal constrictor muscle

Hyoid bone

Thyrohyoid membrane

Thyroid cartilage

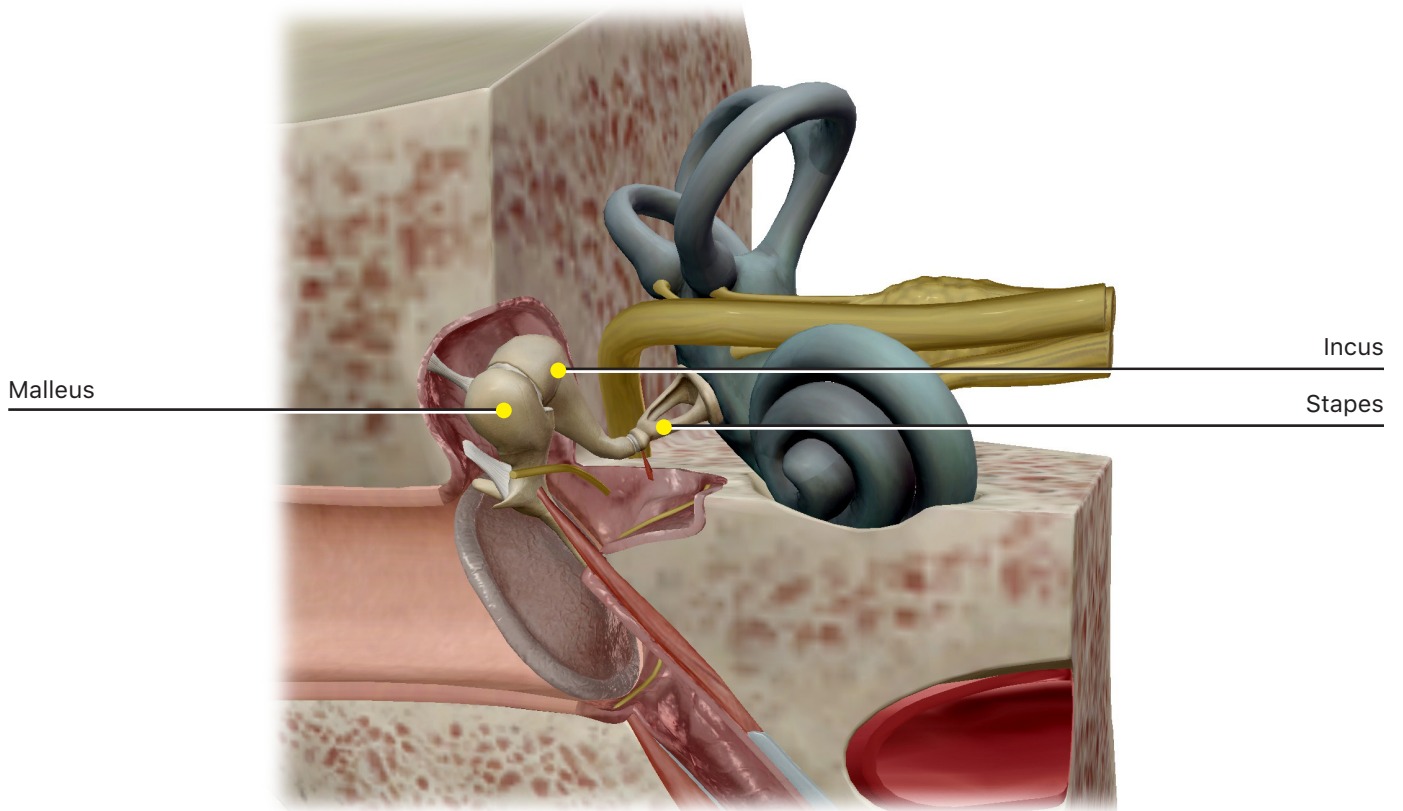
B. Cavities of the Skull



1. Which bones compose the **orbit**?
2. Which bones and cartilages compose the **nasal septum**?
3. Which bones compose the **oral cavity**?
4. Which bones compose the **nasal cavity**?

C. The Auditory Ossicles

Go back to the menu, choose the Microanatomy menu, and select View 9. Inner Ear.



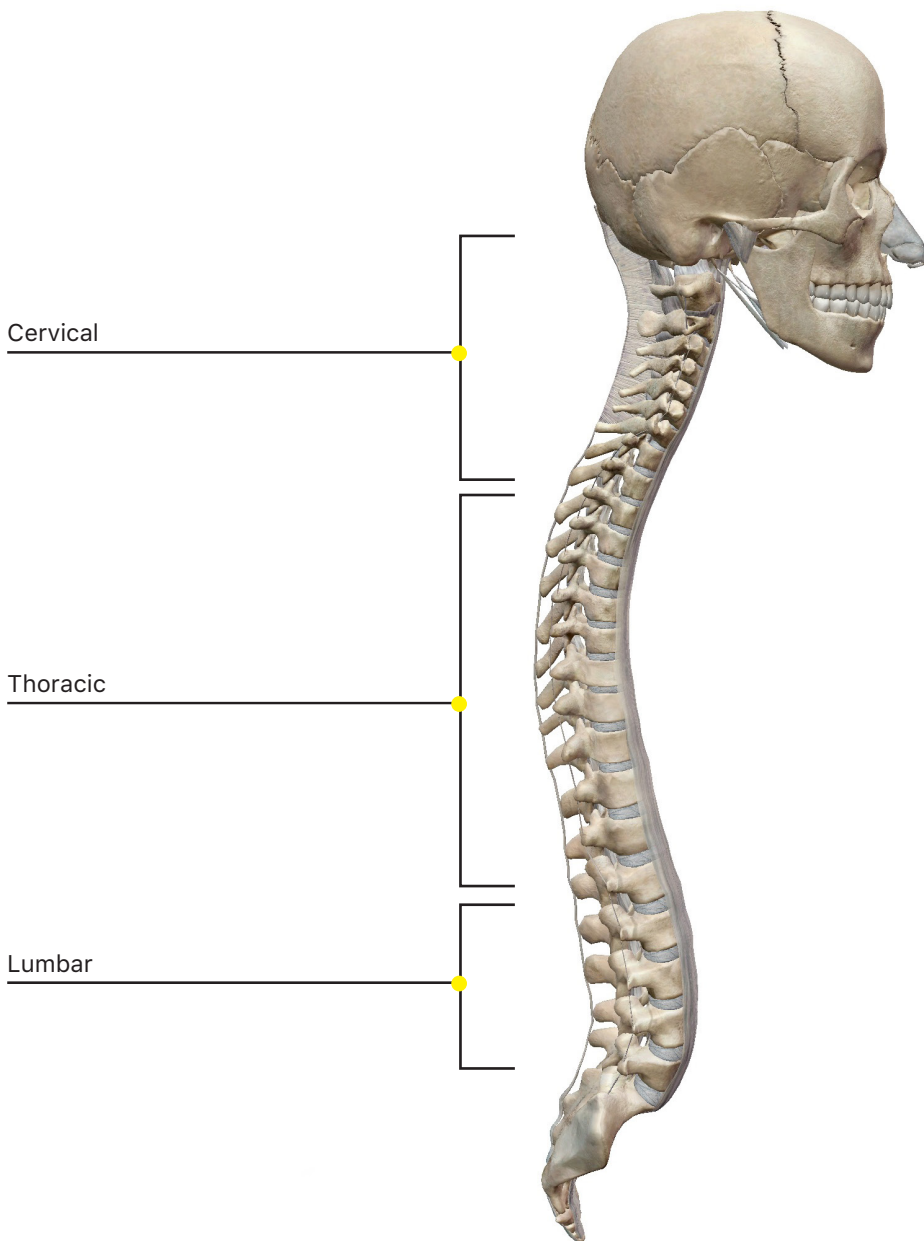
1. As the auditory ossicles vibrate, they conduct sound to your hearing receptors. Which bones comprise the auditory ossicles?

D. Vertebral Column (Spine)

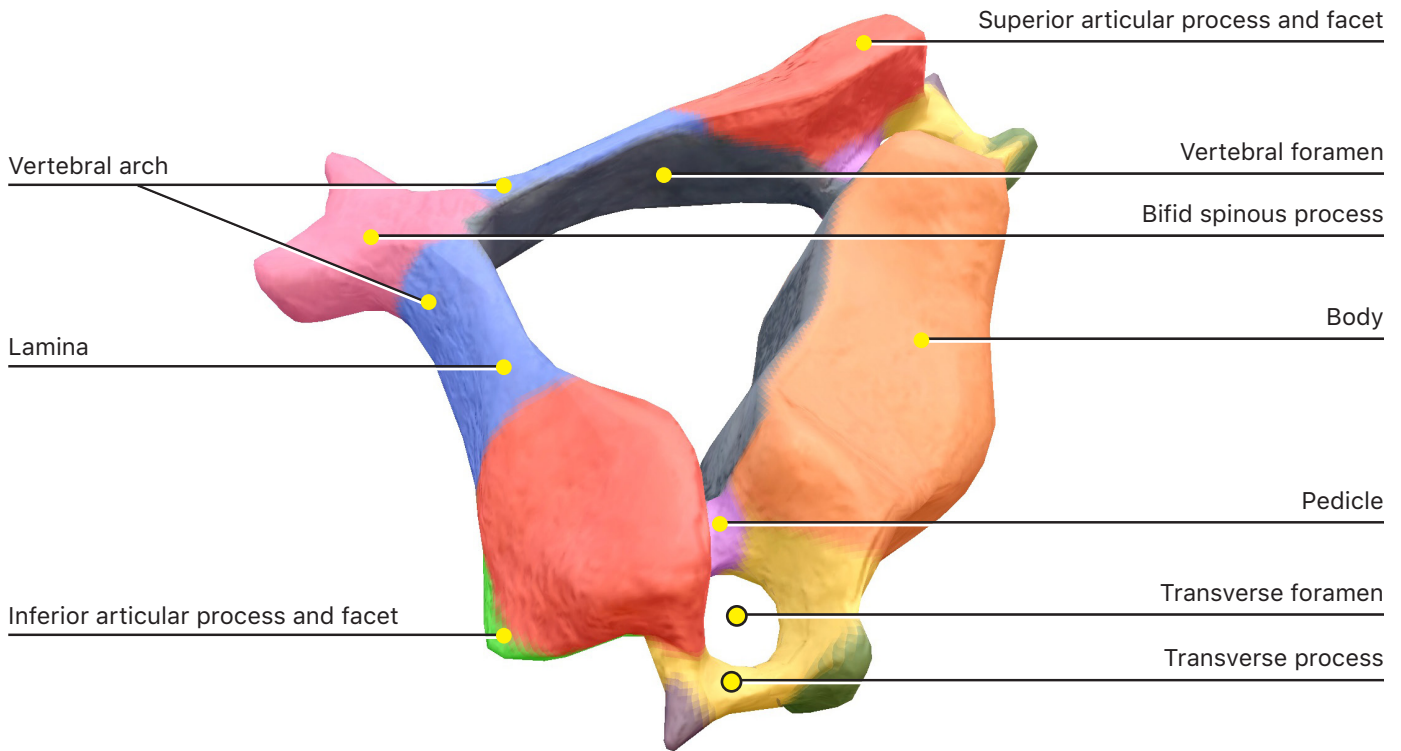
The **vertebral column** consists of 24 vertebrae of different sizes and shapes. The primary function of the **vertebrae** is to protect the spinal cord. They are classified in groups based on their location. As you look at the different vertebrae, compare and contrast vertebrae from different regions in the body. Take note of the bone markings that are found in each type of vertebrae.

Students often confuse processes and facets that have the same name. Remember the definitions for these terms: processes are bony projections, while facets are flat surfaces.

Go back to the Skeletal System Views and select View 13. Spine, Lateral. Identify the following bone markings and answer the questions.



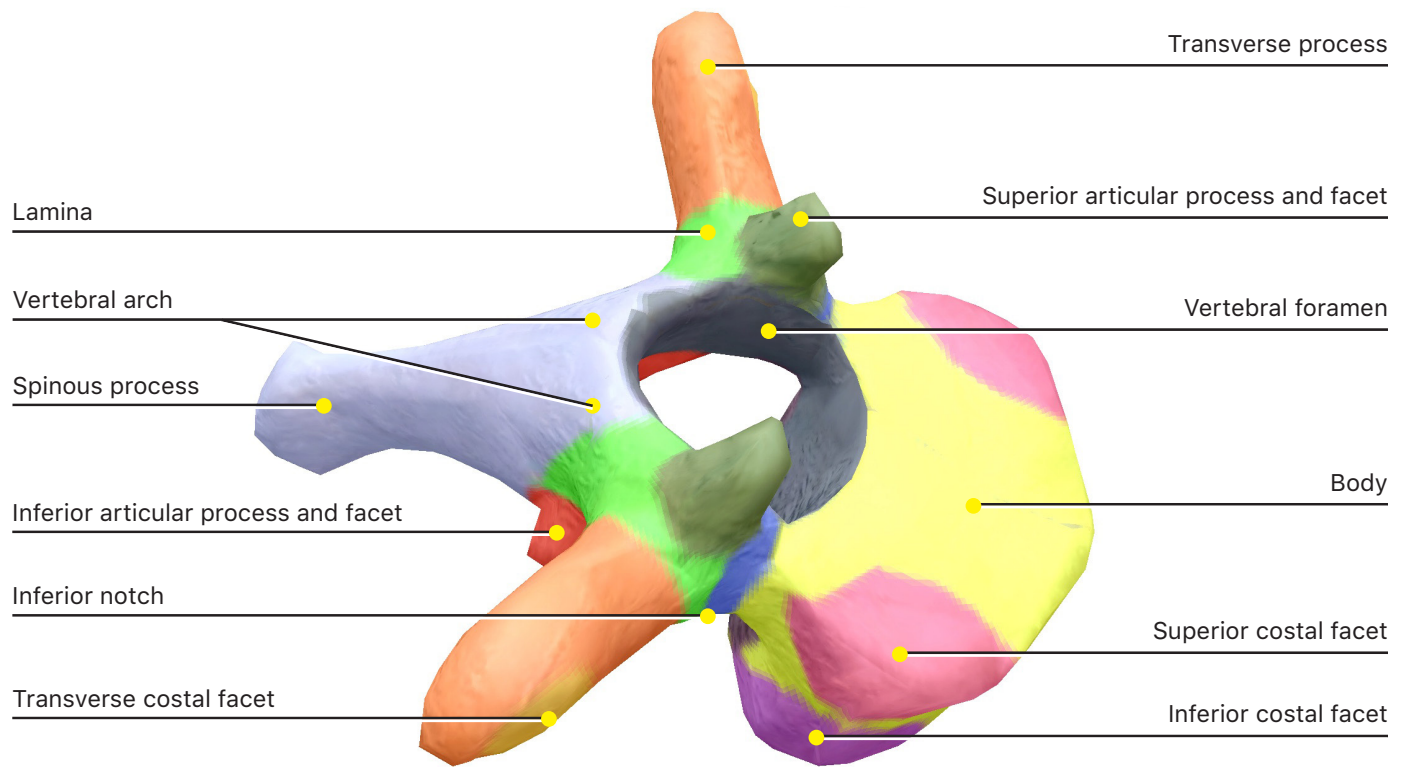
1. **Cervical vertebrae** are in the neck area, **thoracic vertebrae** are in the chest area on the back of the ribs, and **lumbar vertebrae** are in the small of the back. Identify the bone markings found in these different types of vertebrae. While all vertebrae share common characteristics, there are also markings that distinguish them from each other. Pay attention to these distinguishing characteristics so you can tell the difference between cervical, thoracic, and lumbar vertebrae just by looking at them.



a. Identify the **atlas (C1)** and **axis (C2)**, as well as the following bone markings of the cervical vertebrae:

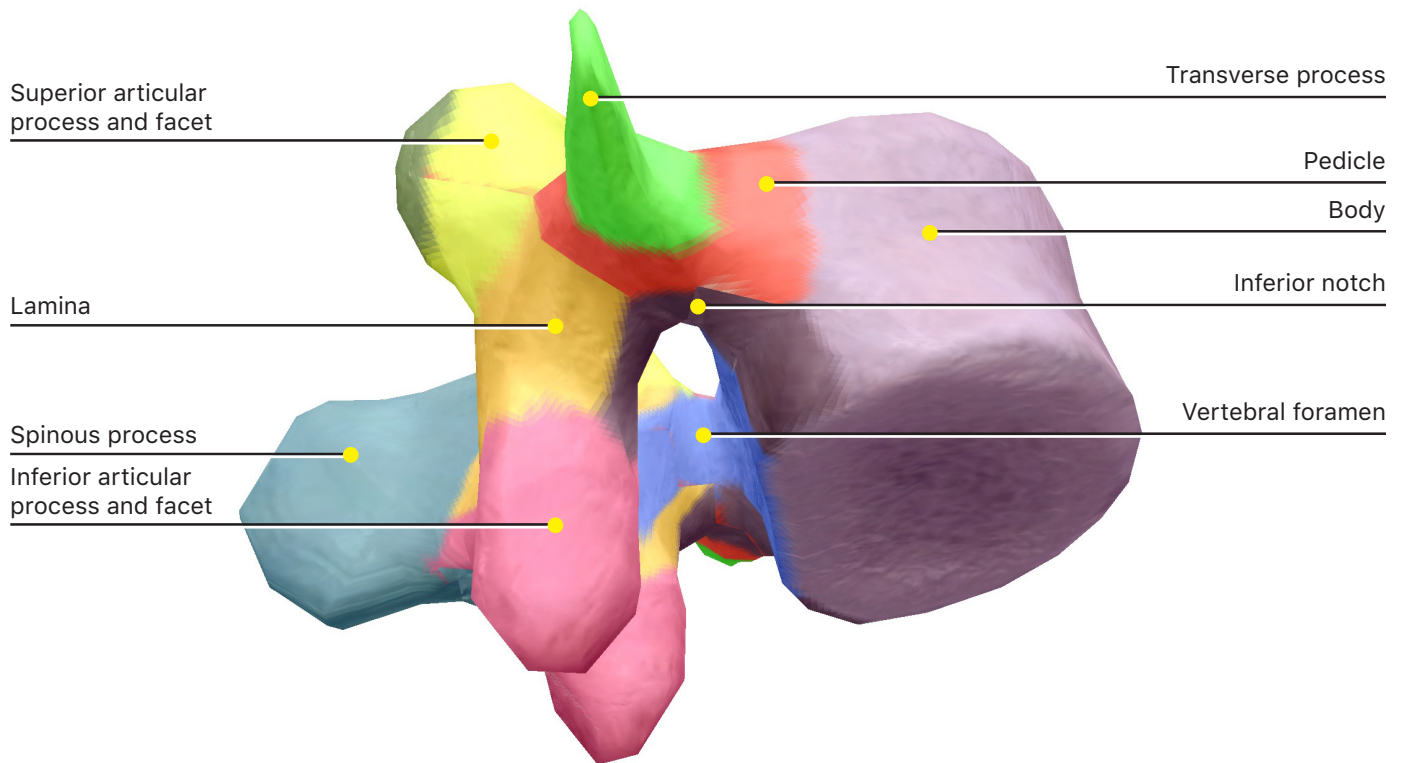
- i. **Body**
- ii. **Vertebral arch**
- iii. **Pedicle**
- iv. **Lamina**
- v. **Inferior notch**
- vi. **Superior articular process and facet**
- vii. **Inferior articular process and facet**
- viii. **Bifid spinous process**
- ix. **Transverse process and foramen**
- x. **Vertebral foramen**

b. Identify the following bone markings of the thoracic vertebrae:



- i. **Body**
- ii. **Vertebral arch**
- iii. **Pedicle**
- iv. **Lamina**
- v. **Vertebral foramen**
- vi. **Inferior notch**
- vii. **Spinous process**
- viii. **Transverse process**
- ix. **Transverse costal facet**
- x. **Superior costal facet**
- xi. **Inferior costal facet**
- xii. **Vertebral foramen**
- xiii. **Superior articular process and facet**
- xiv. **Inferior articular process and facet**

c. Identify the following bone markings of the lumbar vertebrae:



- i. **Body**
- ii. **Vertebral arch**
- iii. **Pedicle**
- iv. **Lamina**
- v. **Vertebral foramen**
- vi. **Spinous process**
- vii. **Transverse process**
- viii. **Superior articular process and facet**
- ix. **Inferior articular process and facet**
- x. **Inferior notch**

d. How many cervical, thoracic, and lumbar vertebrae are there?

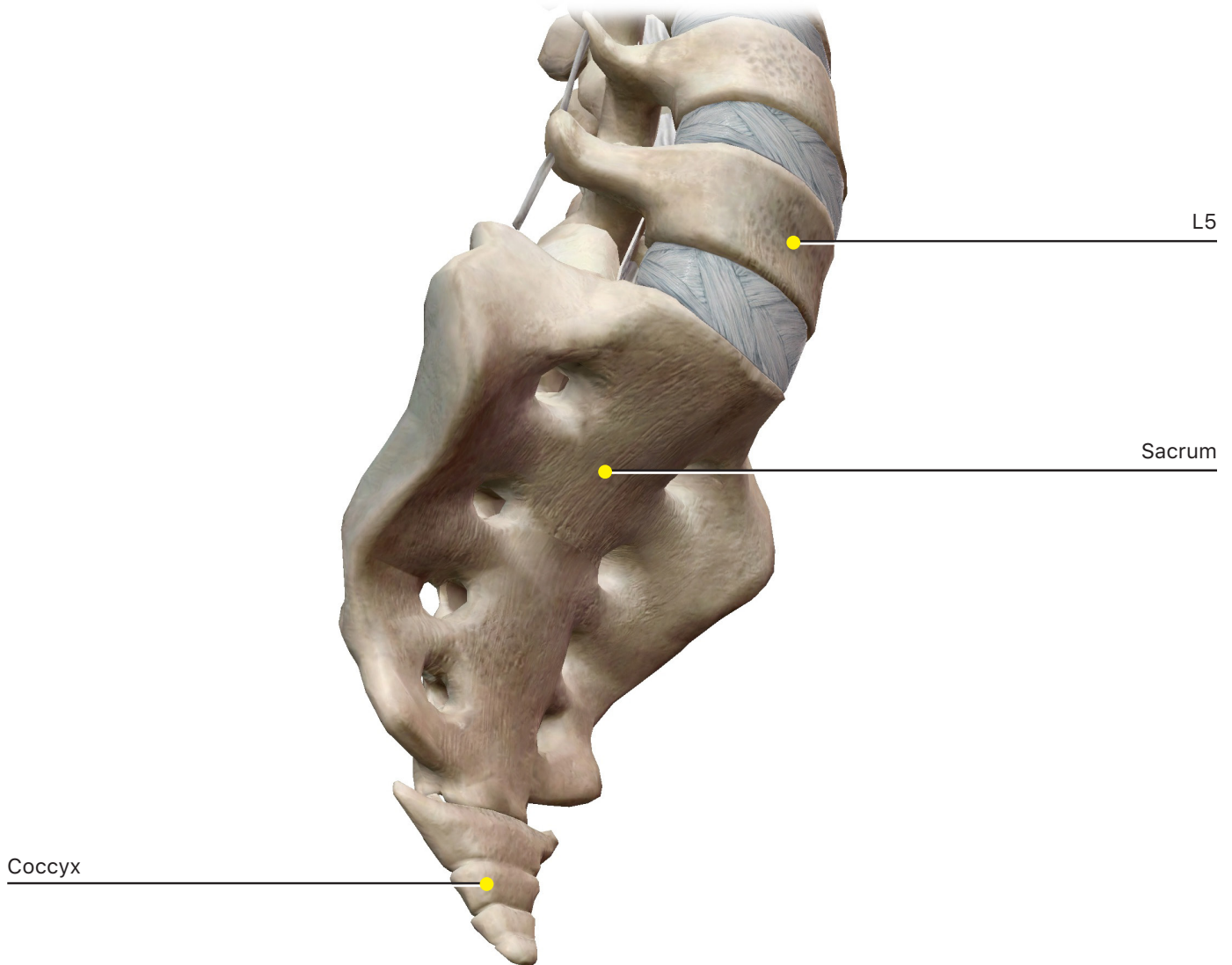
e. Which bone markings enclose the spinal cord?

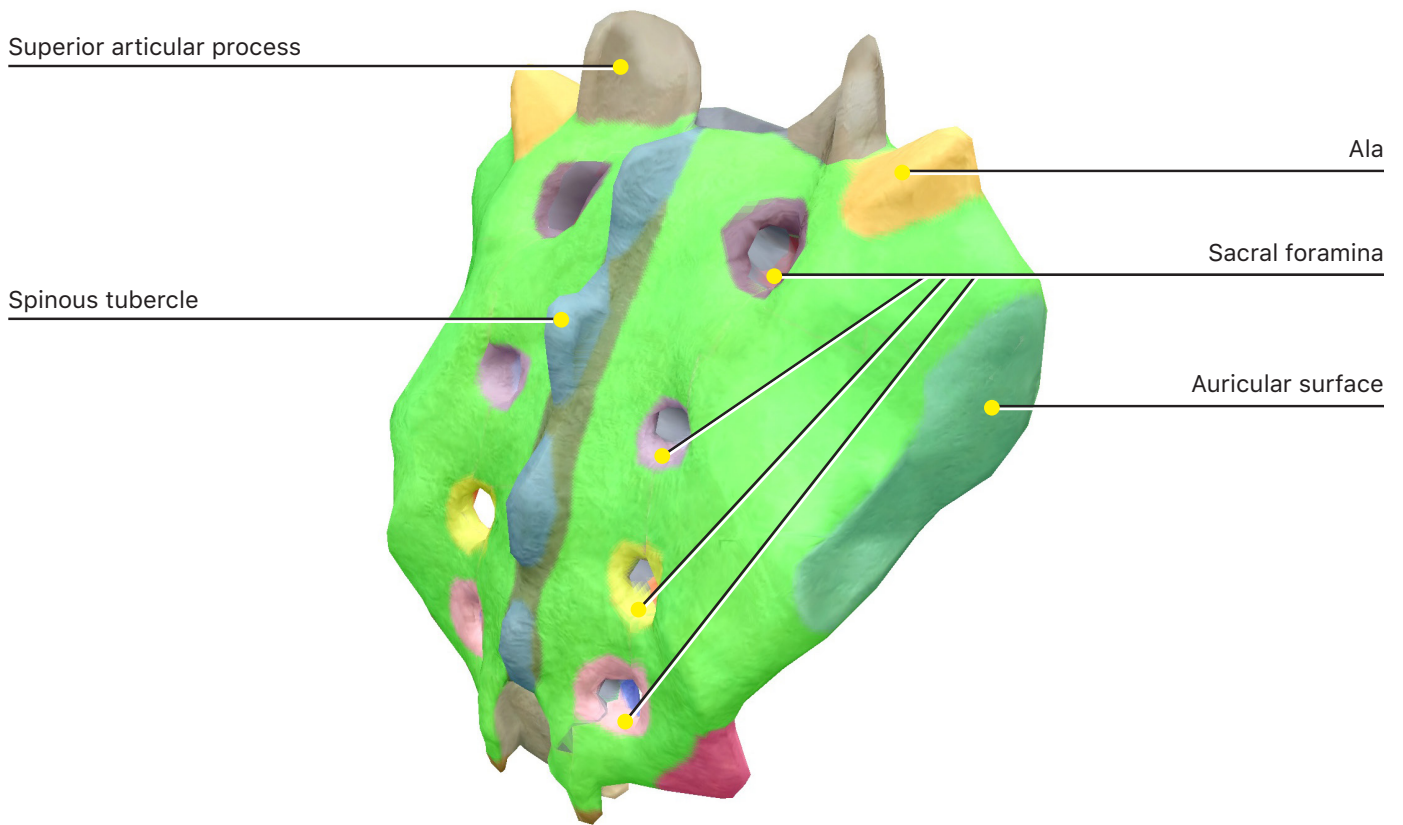
f. What is the function of the costal facets of the thoracic vertebrae?

g. What is the significance of the size of the body in lumbar vertebrae?

h. What are the distinguishing characteristics of cervical vertebrae?

2. The **sacrum** and **coccyx** are found in the pelvis in the inferior part of the vertebral column.





a. Identify the following bone markings of the sacrum:

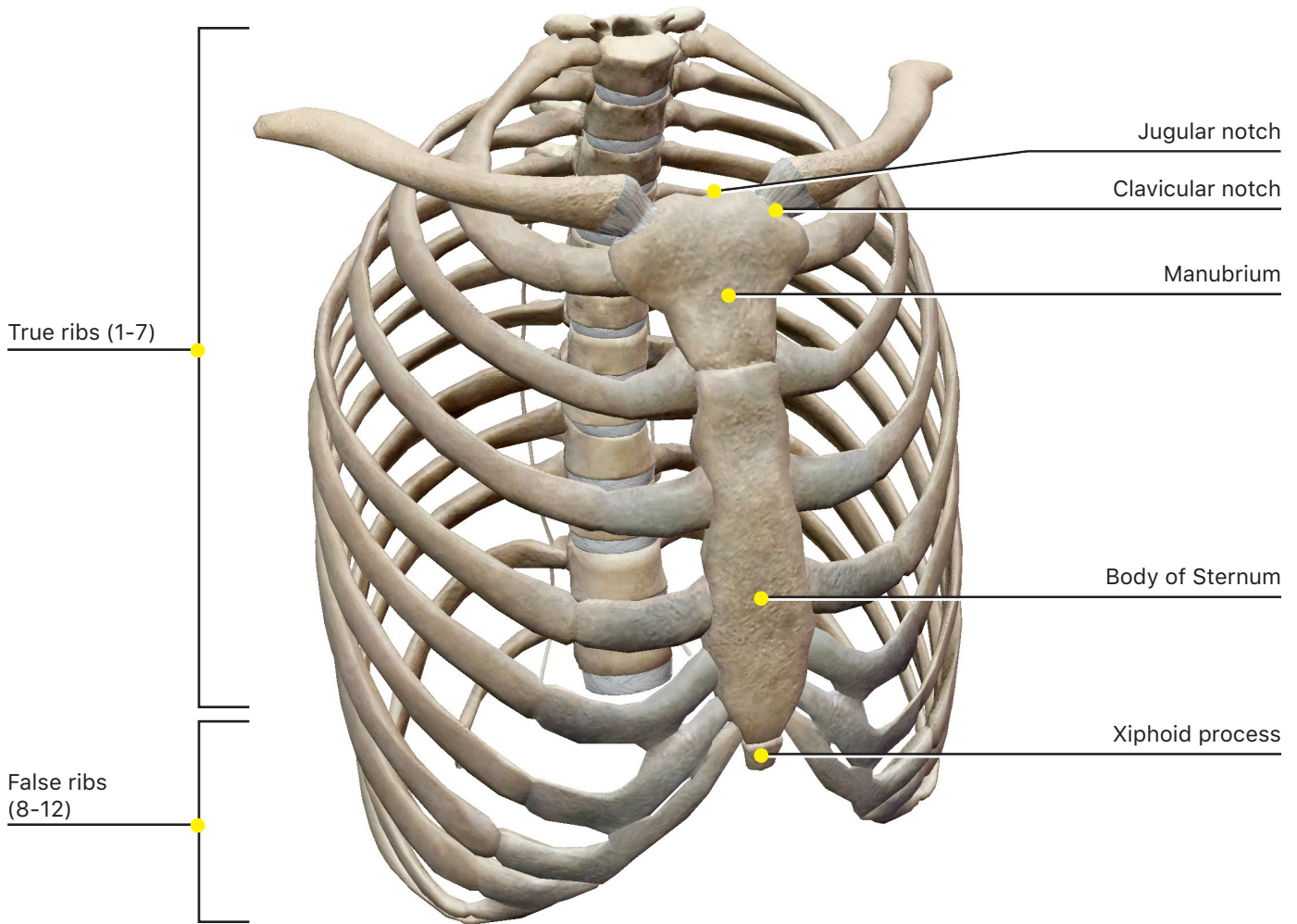
- i. **Spinous tubercle**
- ii. **Ala**
- iii. **Promontory**
- iv. **Sacral foramina**
- v. **Superior articular process**
- vi. **Auricular surface**

b. Identify the coccyx.

E. Thoracic Cage

The thoracic cage protects important underlying organs, such as the heart and lungs. The bones also serve as attachment points for respiratory muscles.

Go back to the Skeletal System Views and select View 9. Thoracic Cage. Identify the following bones and bone markings:



1. Sternum

a. Manubrium

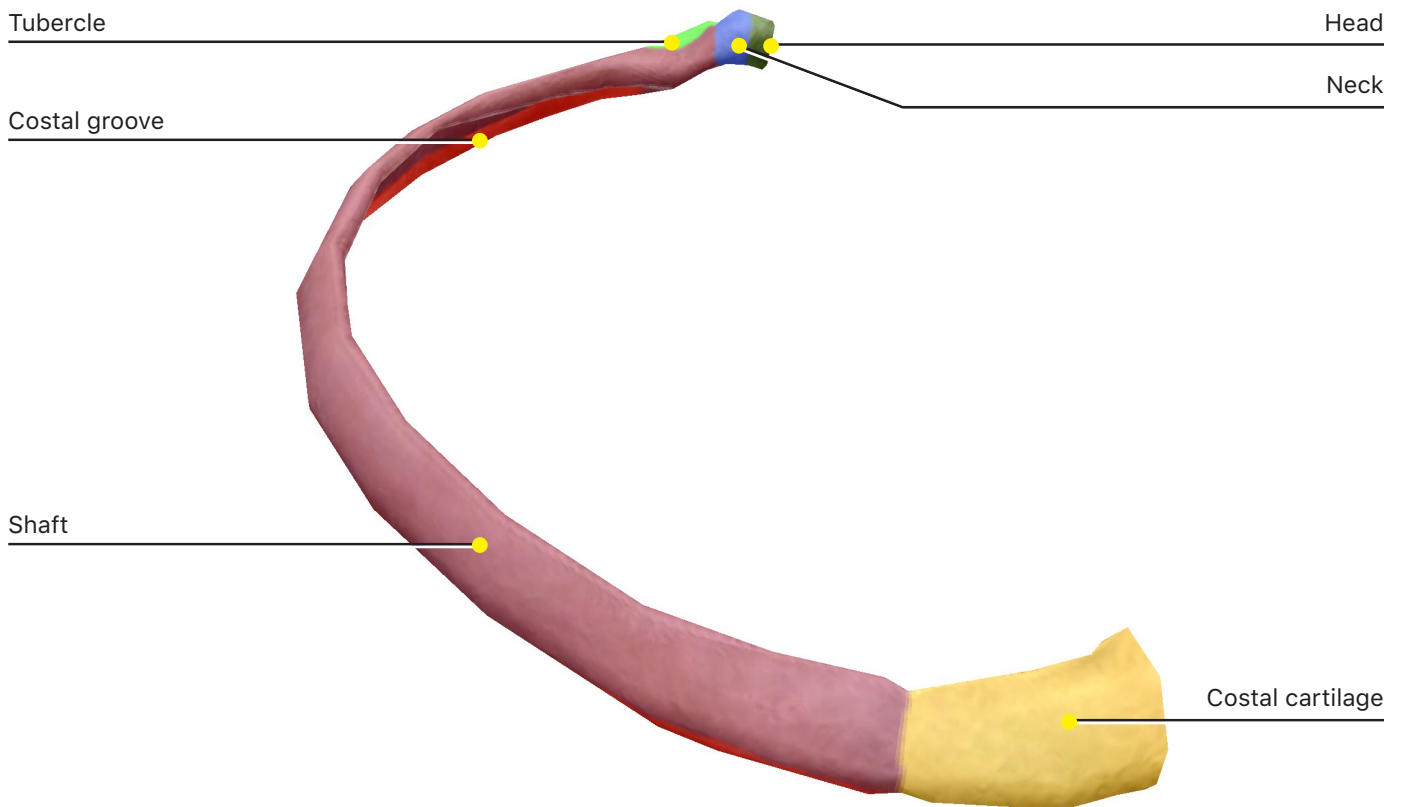
i. Jugular notch

ii. Clavicular notch

b. Body of the sternum

c. Xiphoid process

2. The **ribs** are classified based on how they attach to the sternum. Be sure to select the book icon for several different ribs to read about how they are classified.



a. Identify the following bone markings:

- i. **Head**
- ii. **Neck**
- iii. **Costal groove**
- iv. **Tubercle**

b. Which ribs are **true ribs**? Why are they classified as true ribs?

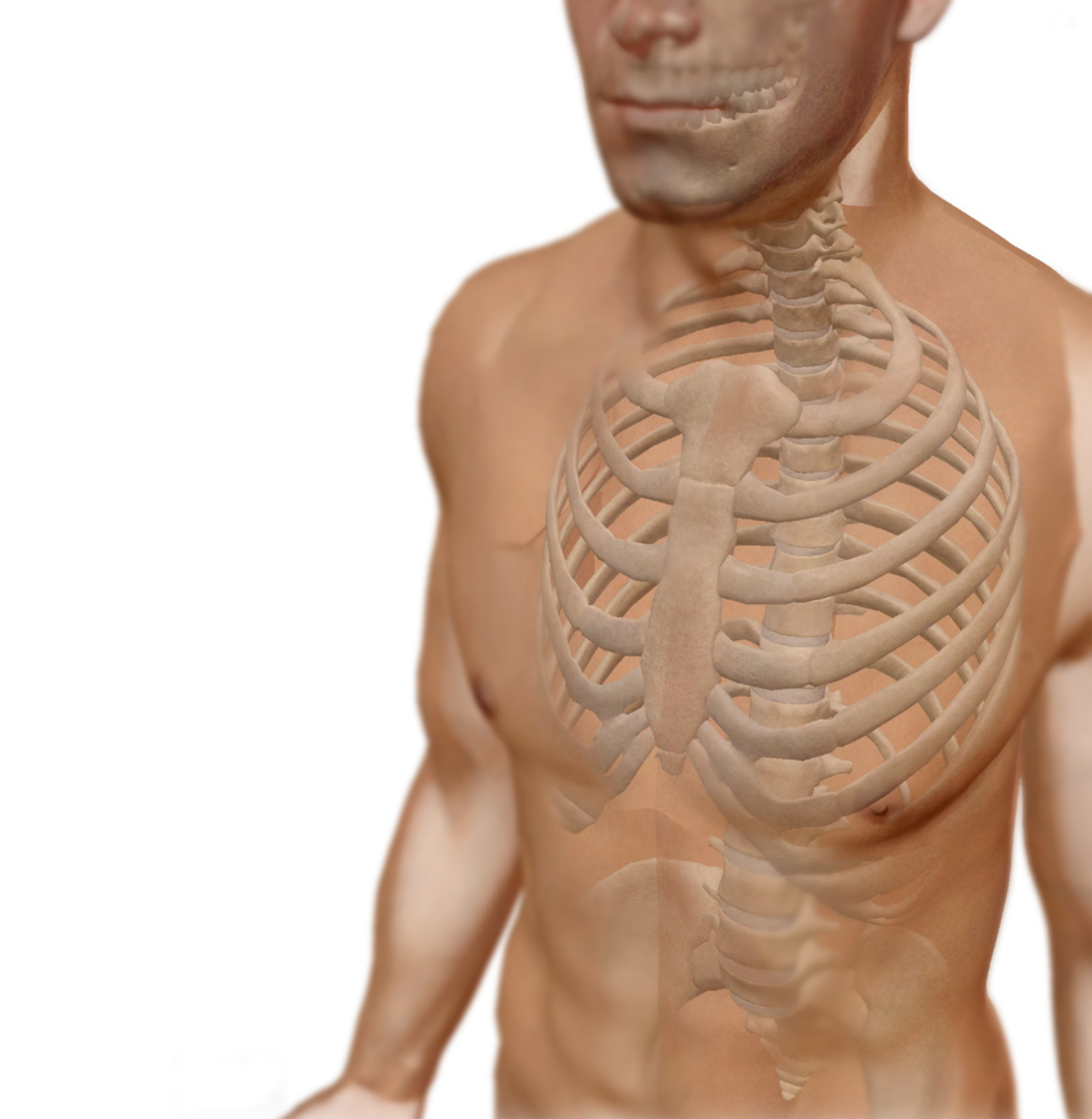
c. Which ribs are **false ribs**? Why are these classified as false ribs?

PUTTING IT ALL TOGETHER

1. You identified the hard palate of the maxilla. Why was the soft palate not included in this exercise?
2. Where would be a good place for a lidocaine injection prior to dental work? You would want easy access to a blood vessel in the jaw.
3. If you have high cheekbones, to which bones does this refer?
4. Imagine that you are working as a medical examiner and a new body is brought in. The body appears to be healthy, except for a broken hyoid bone. What do you suspect is the cause of death?
5. Why does the thoracic cage need to be slightly flexible?
6. What are the four different places where ribs attach?

TIME TO PRACTICE!

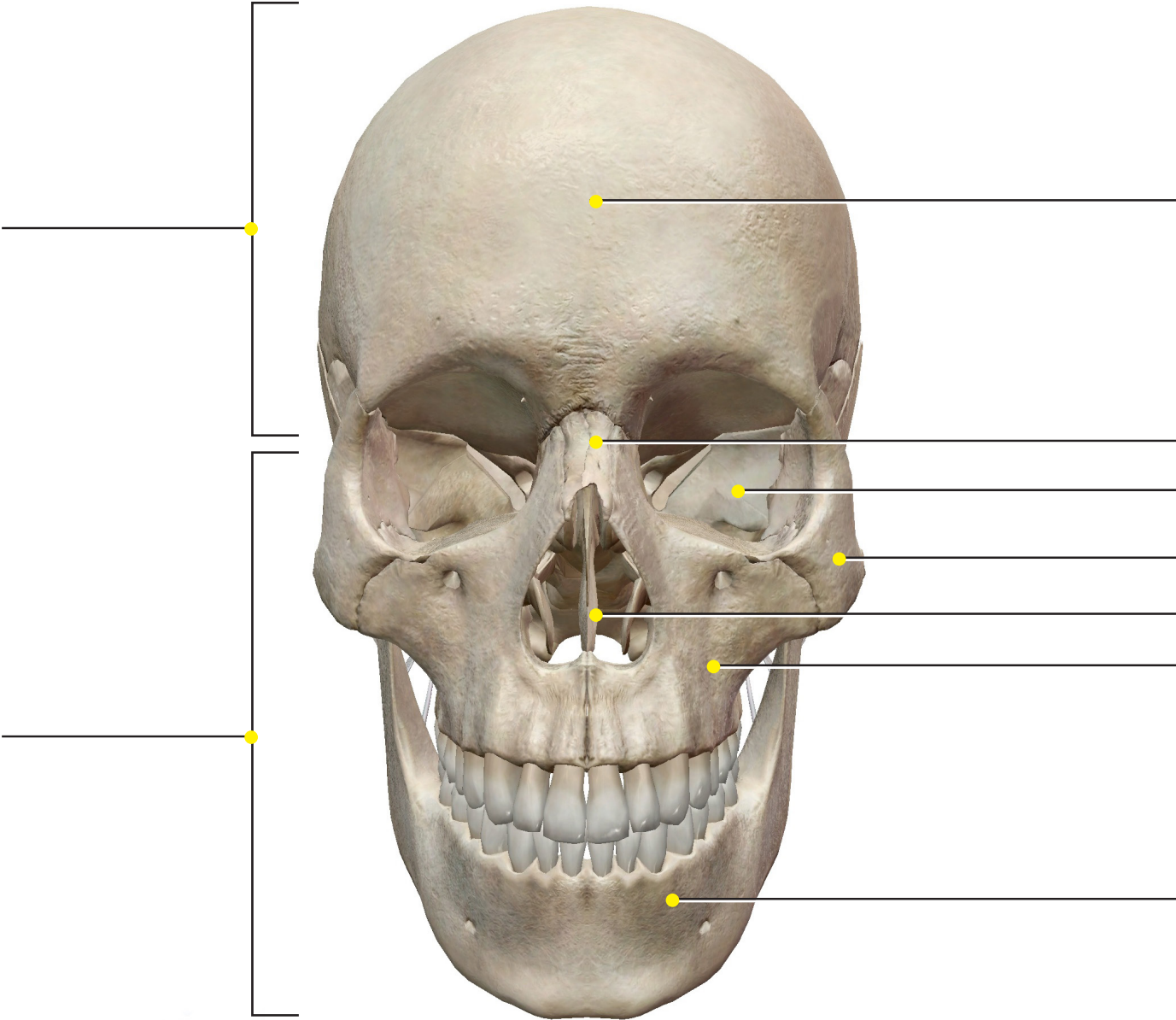
GO TO THE SKELETAL SYSTEM QUIZZES AND TAKE QUIZ 1 SKULL, QUIZ 4 THORACIC CAGE, QUIZ 5 STERNUM, AND QUIZ 6 VERTEBRAL COLUMN



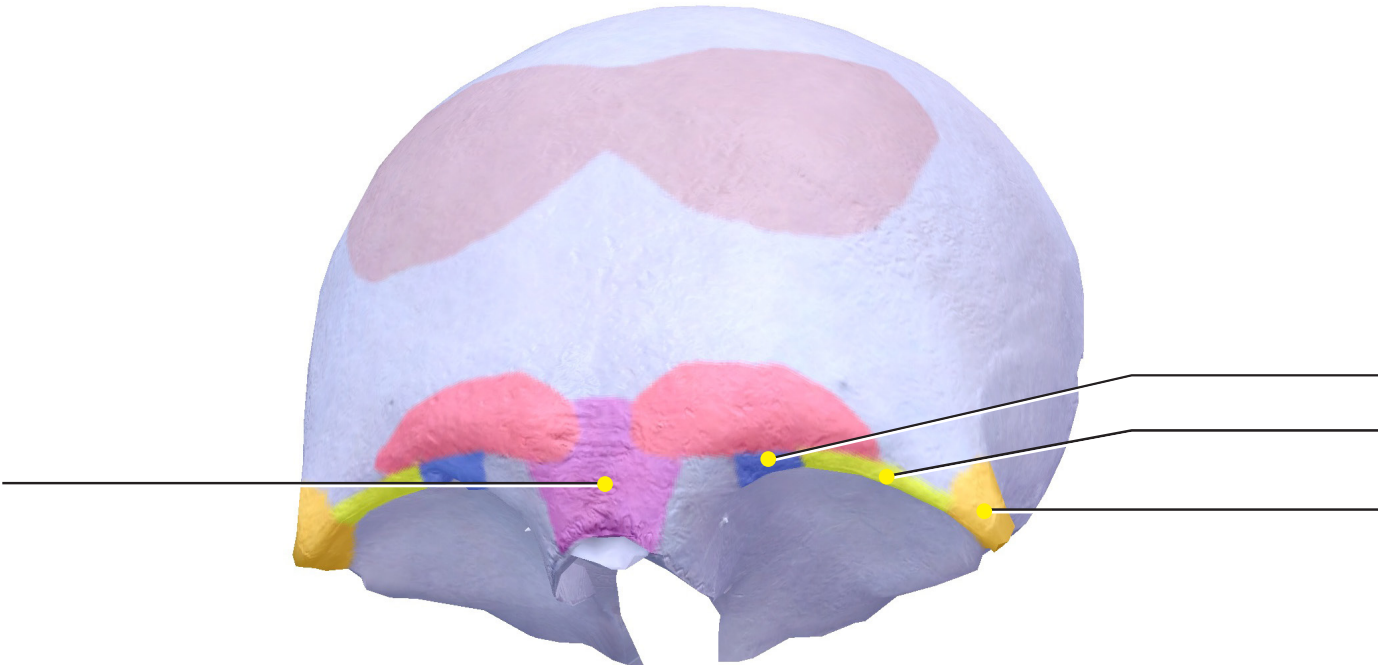
Student Practice

Label all the structures on the following images.

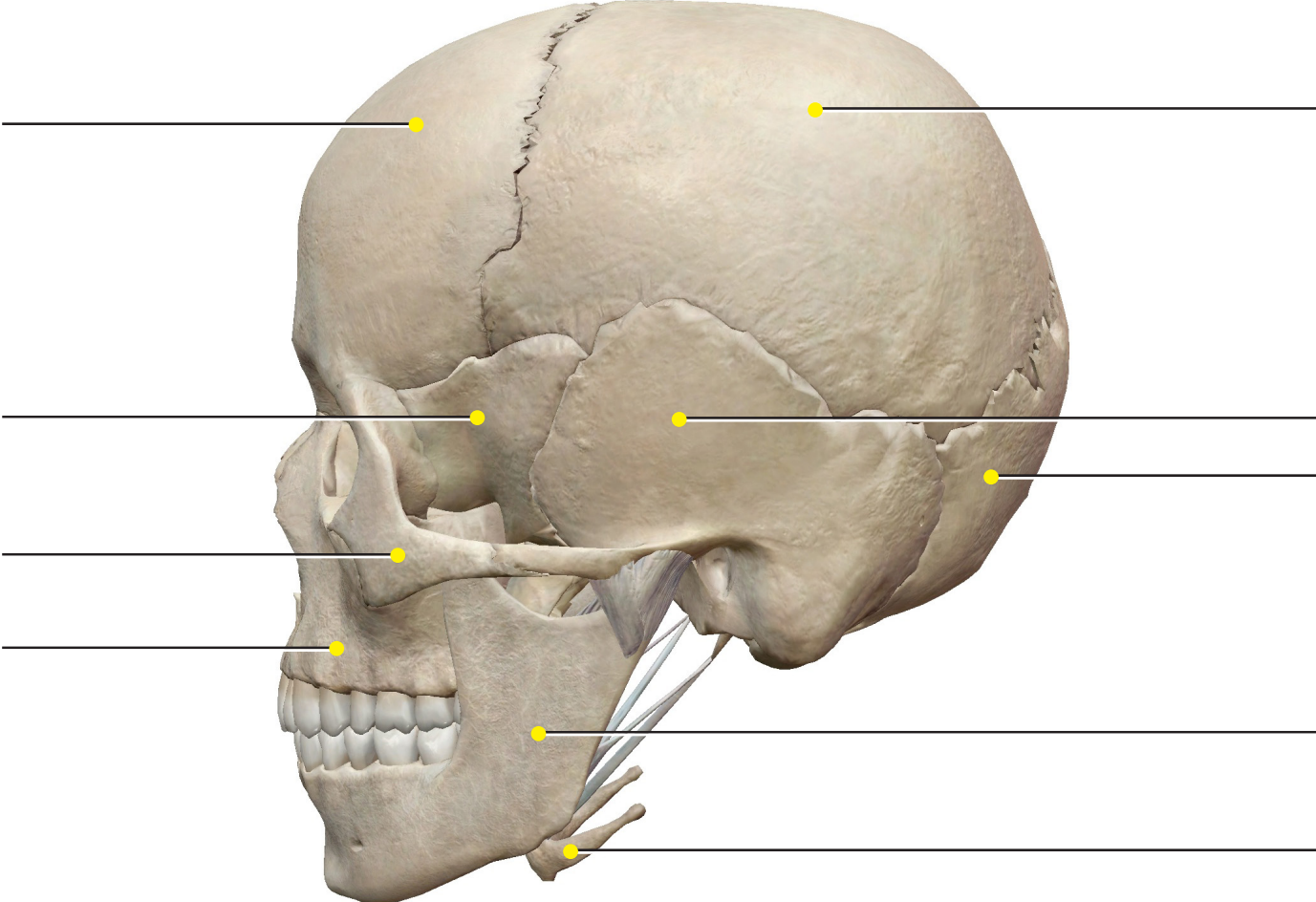
Source: Skeletal System Views: View 2. Skull



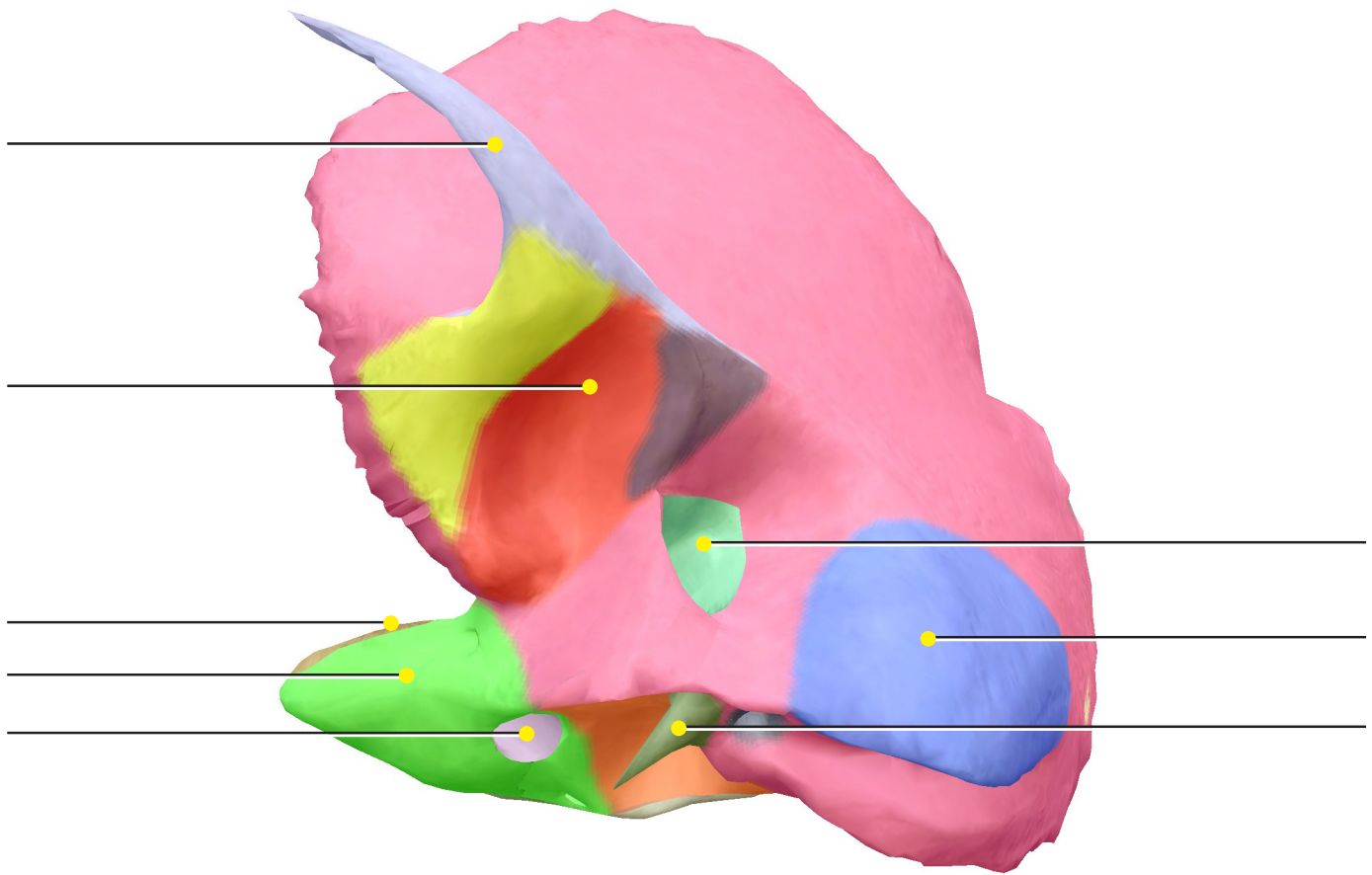
Source: Skeletal System Views: View 2. Skull



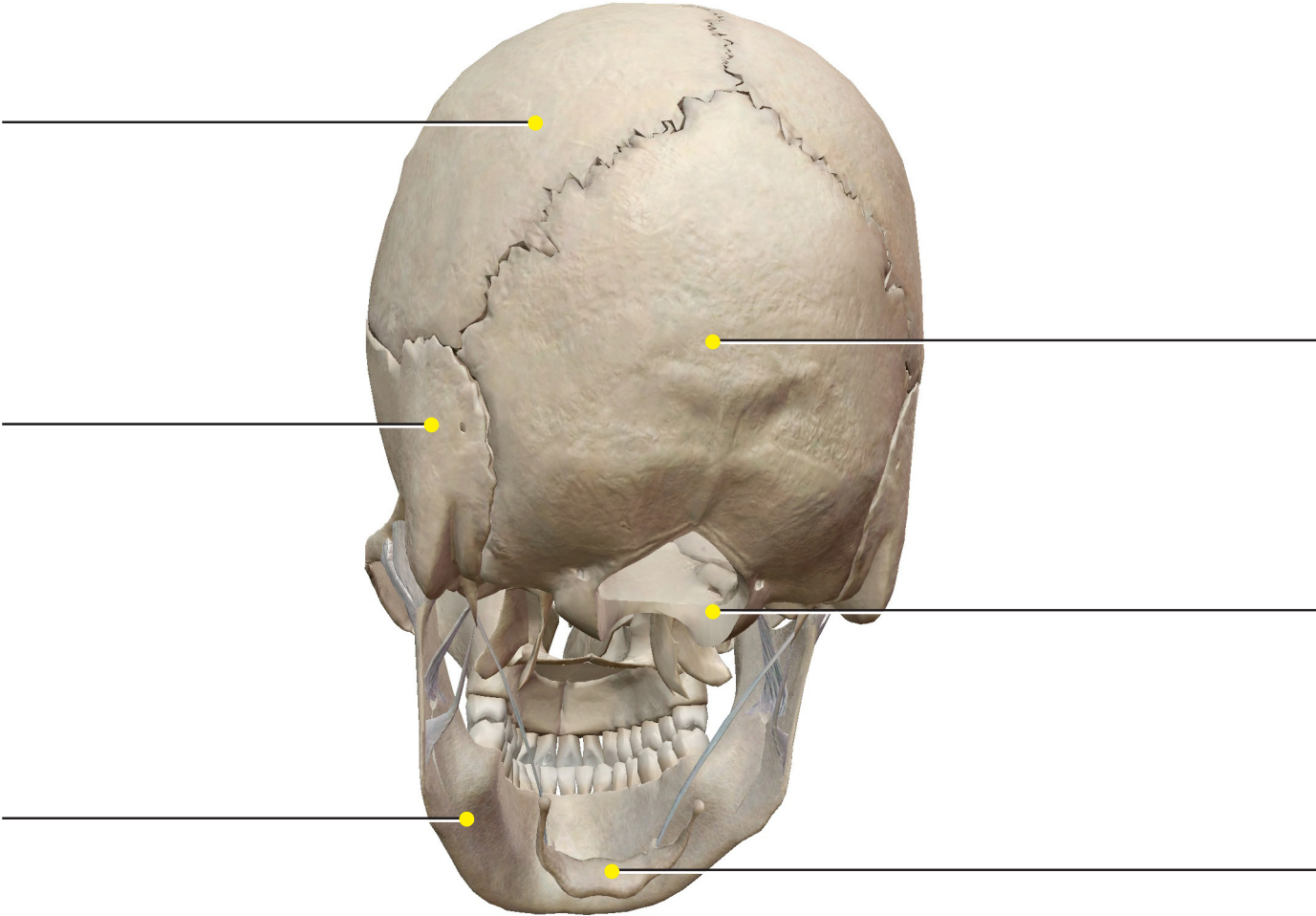
Source: Skeletal System Views: View 2. Skull



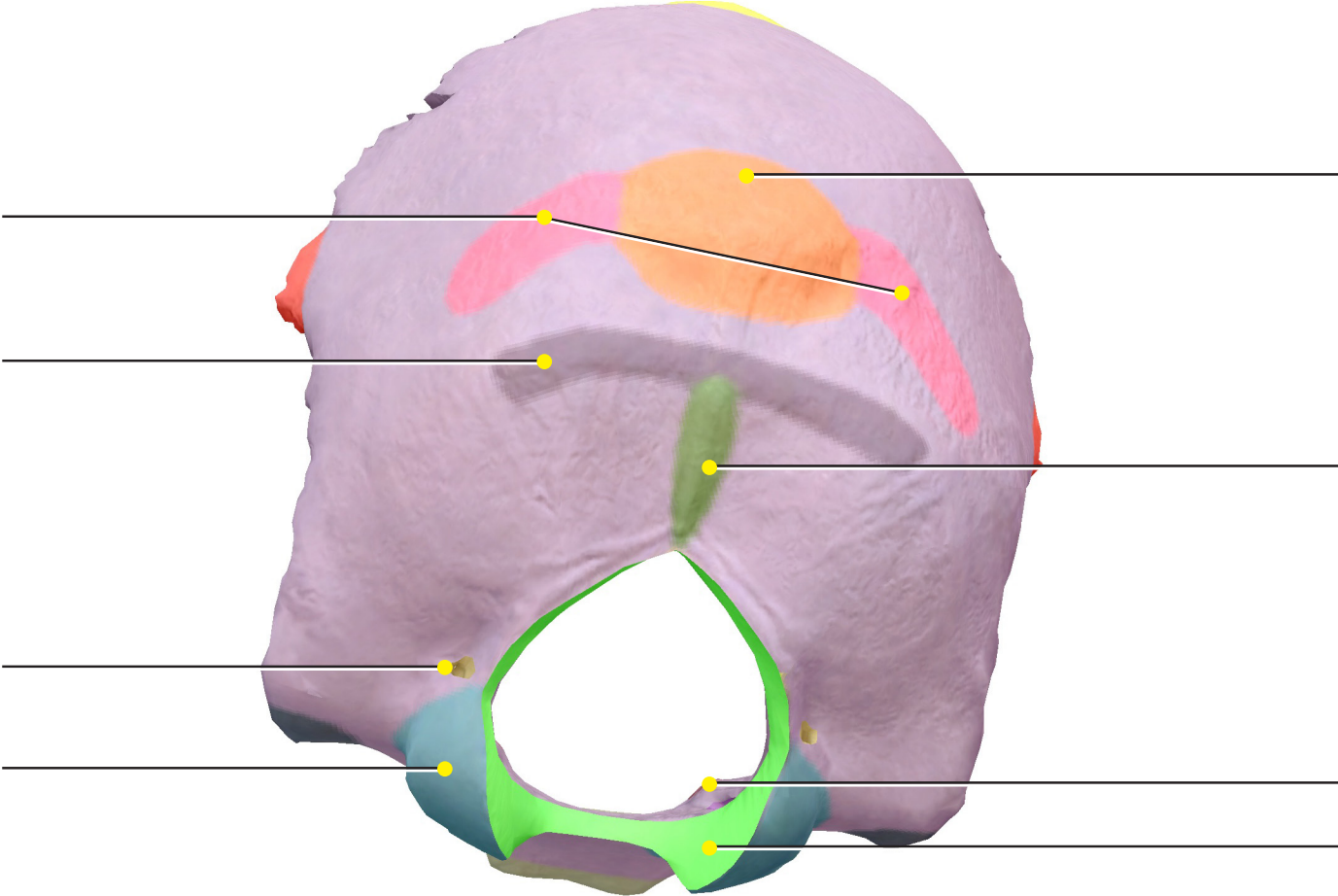
Source: Skeletal System Views: View 2. Skull



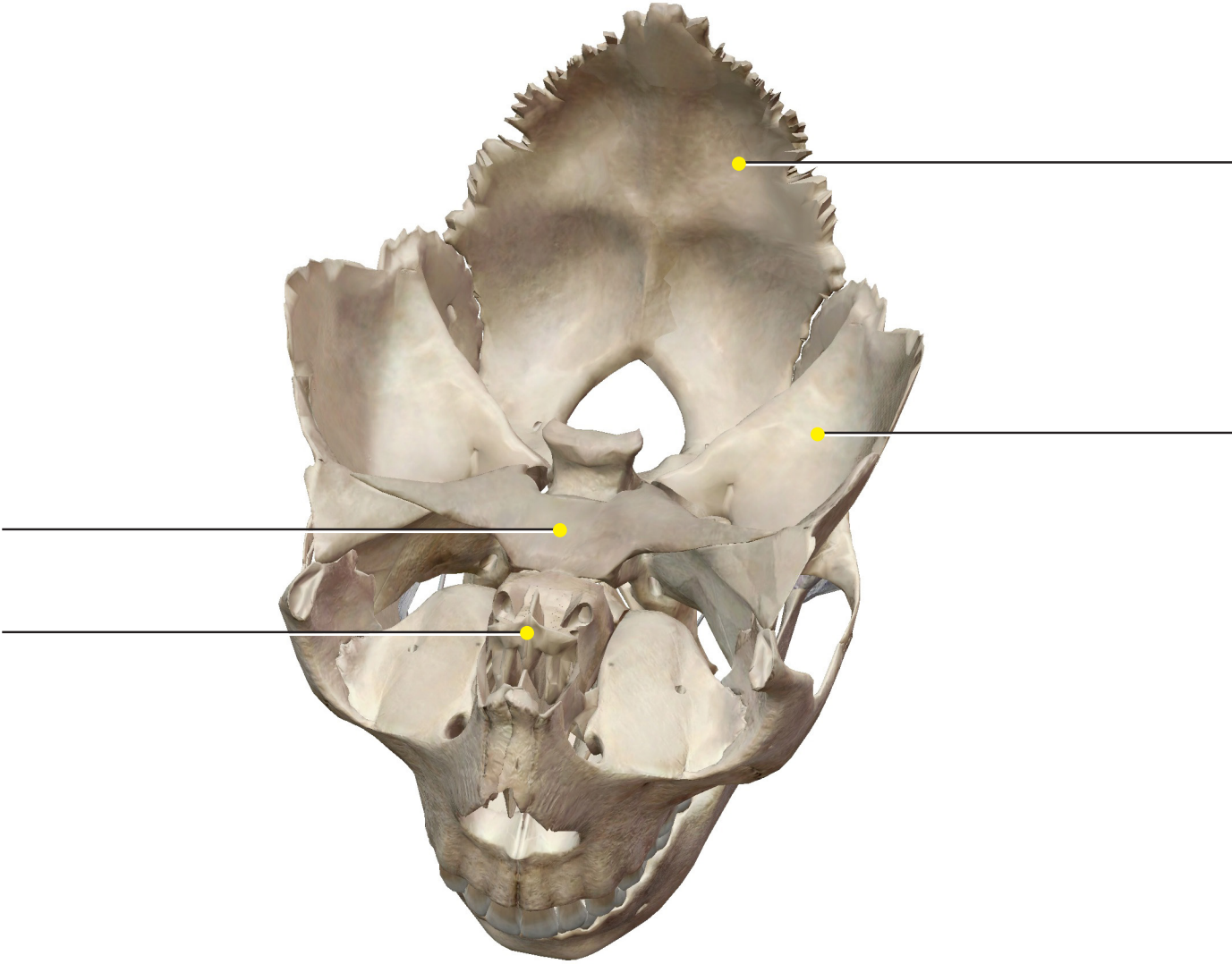
Source: Skeletal System Views: View 2. Skull



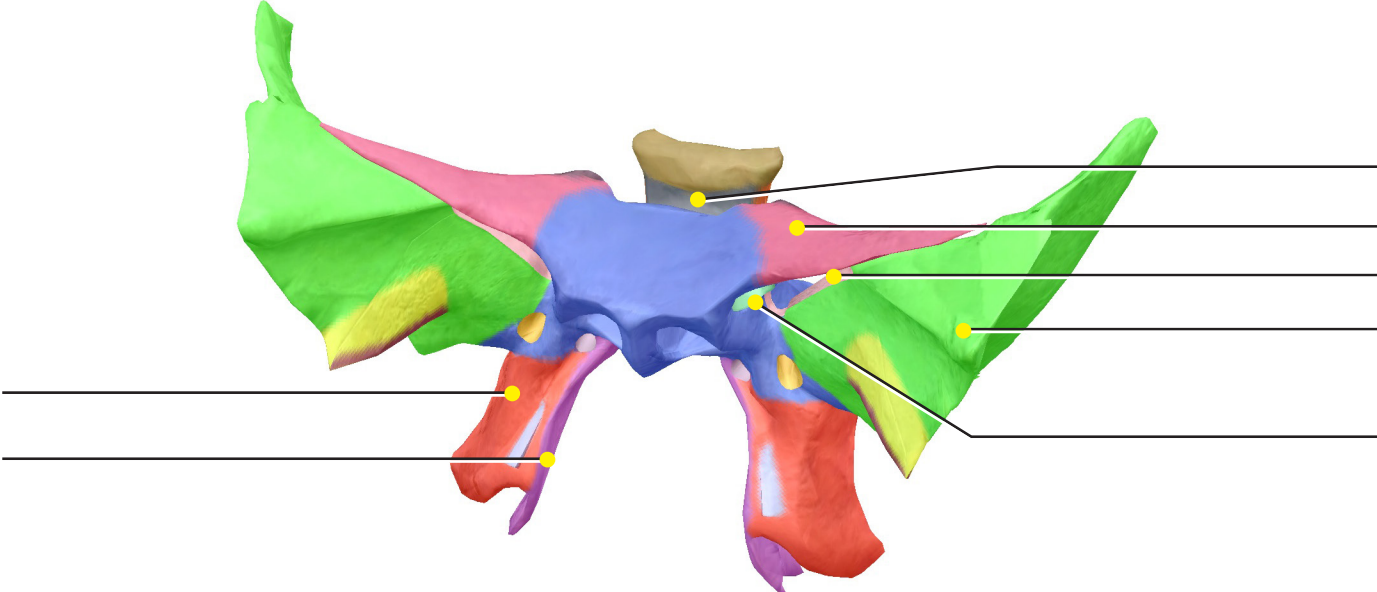
Source: Skeletal System Views: View 2. Skull



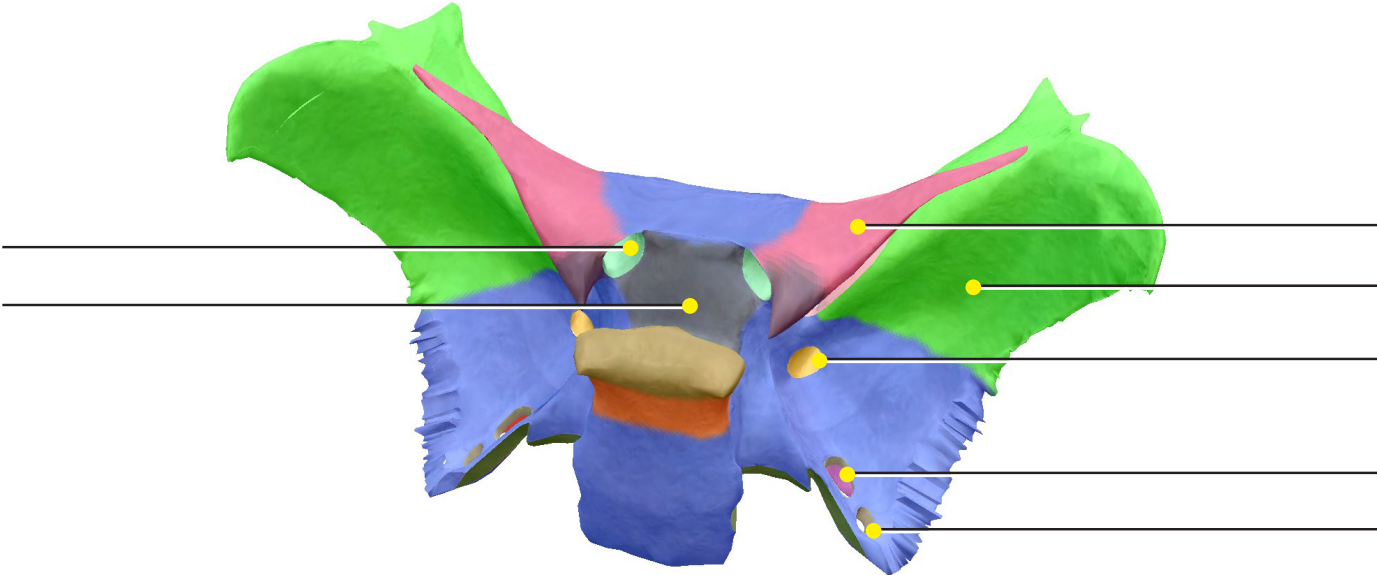
Source: Skeletal System Views: View 2. Skull



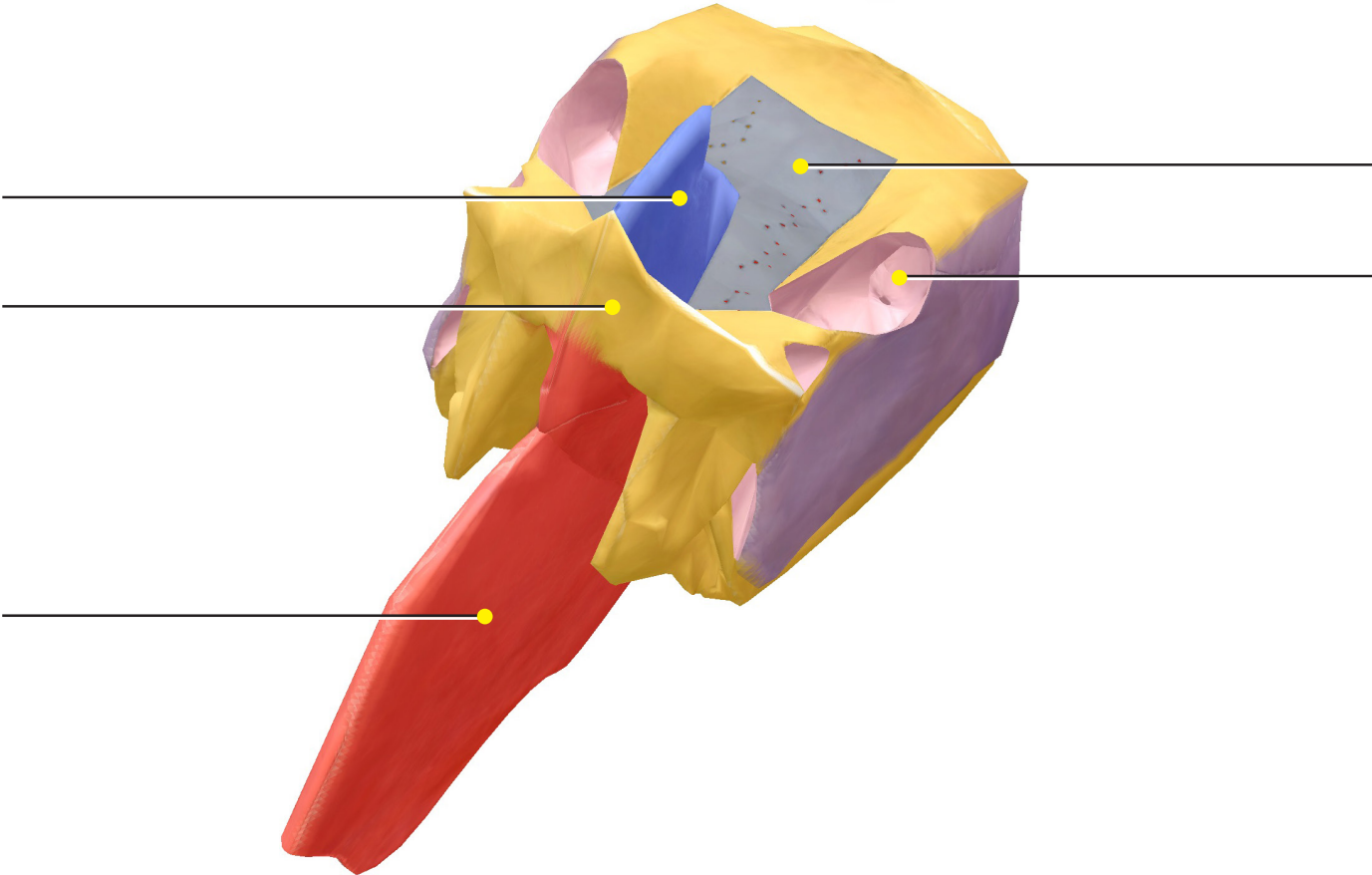
Source: Skeletal System Views: View 2. Skull



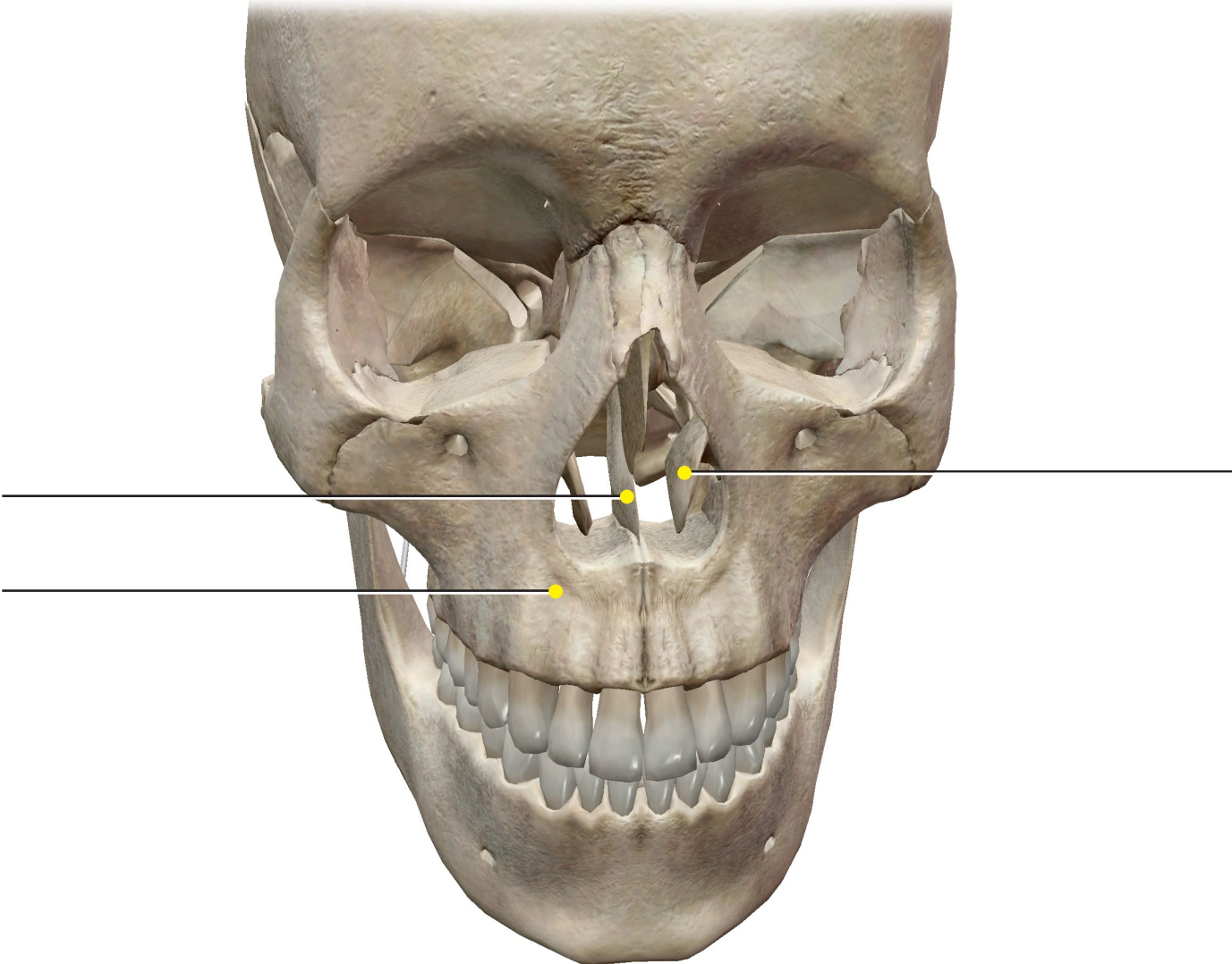
Source: Skeletal System Views: View 2. Skull



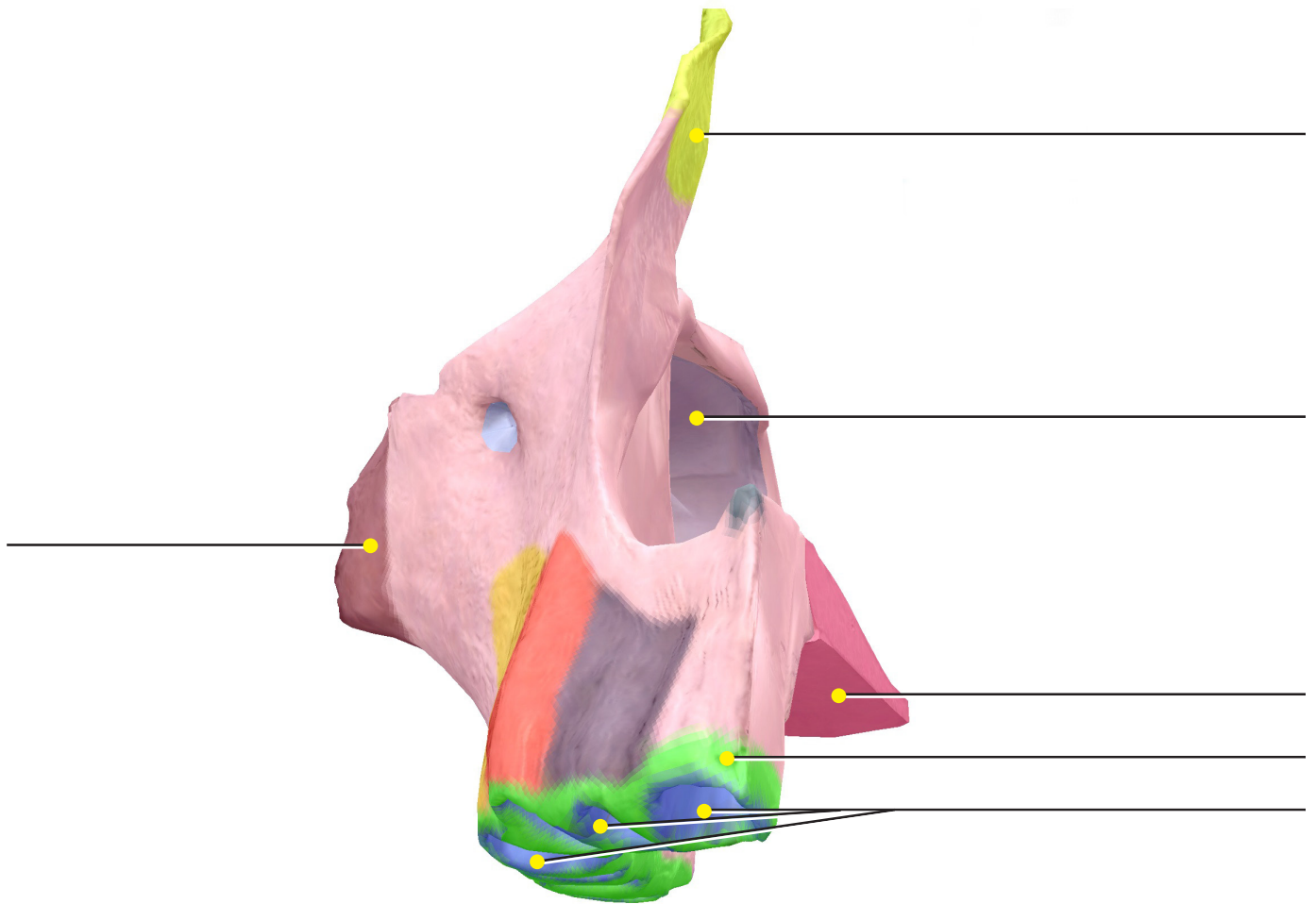
Source: Skeletal System Views: View 2. Skull



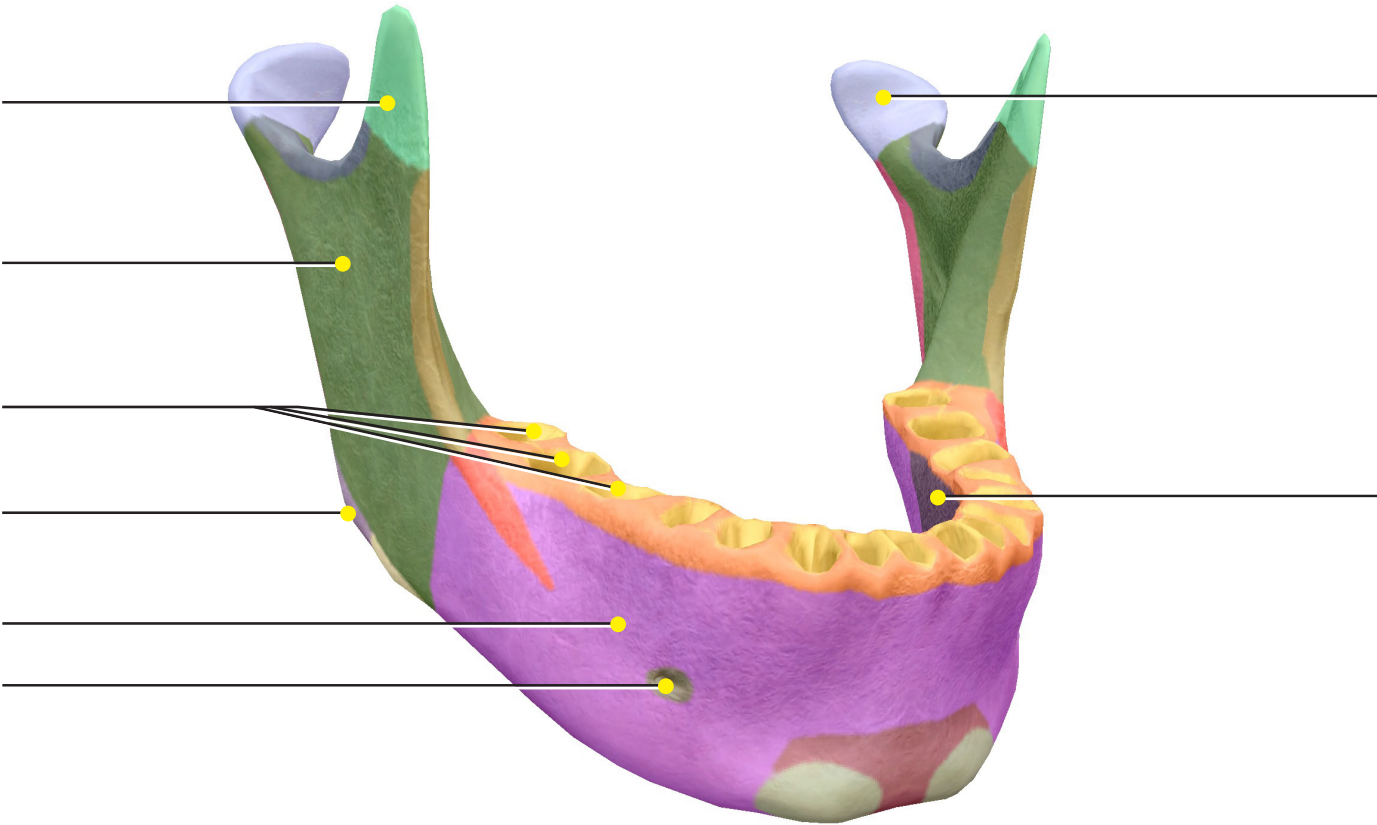
Source: Skeletal System Views: View 2. Skull



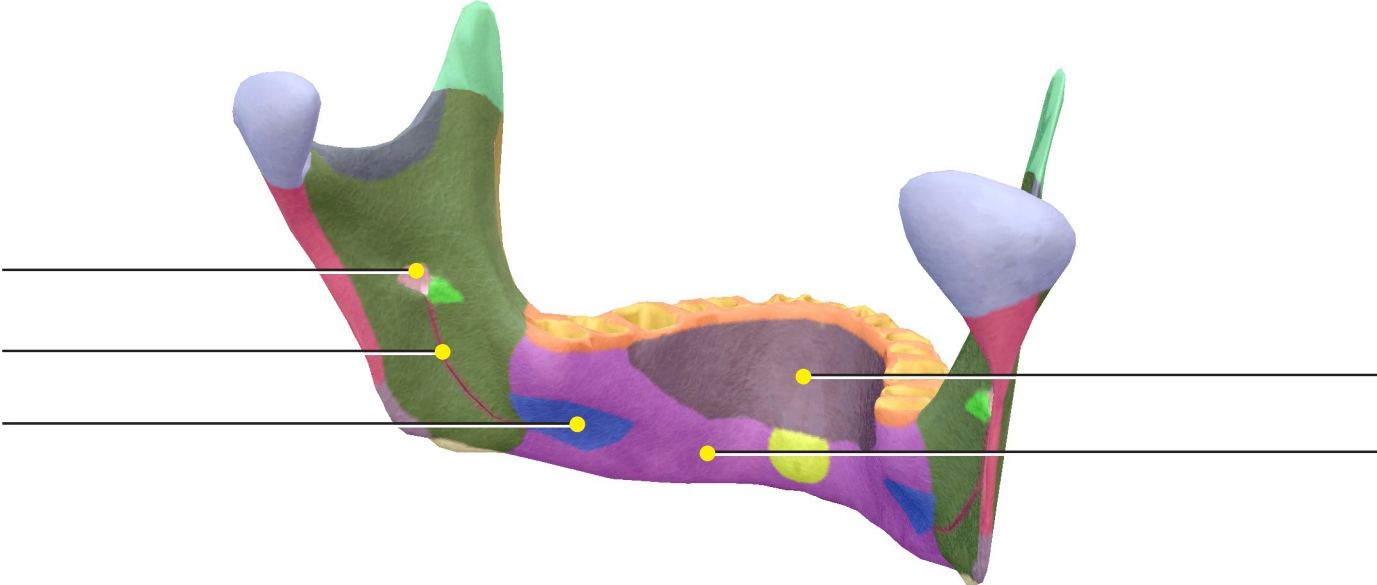
Source: Skeletal System Views: View 2. Skull



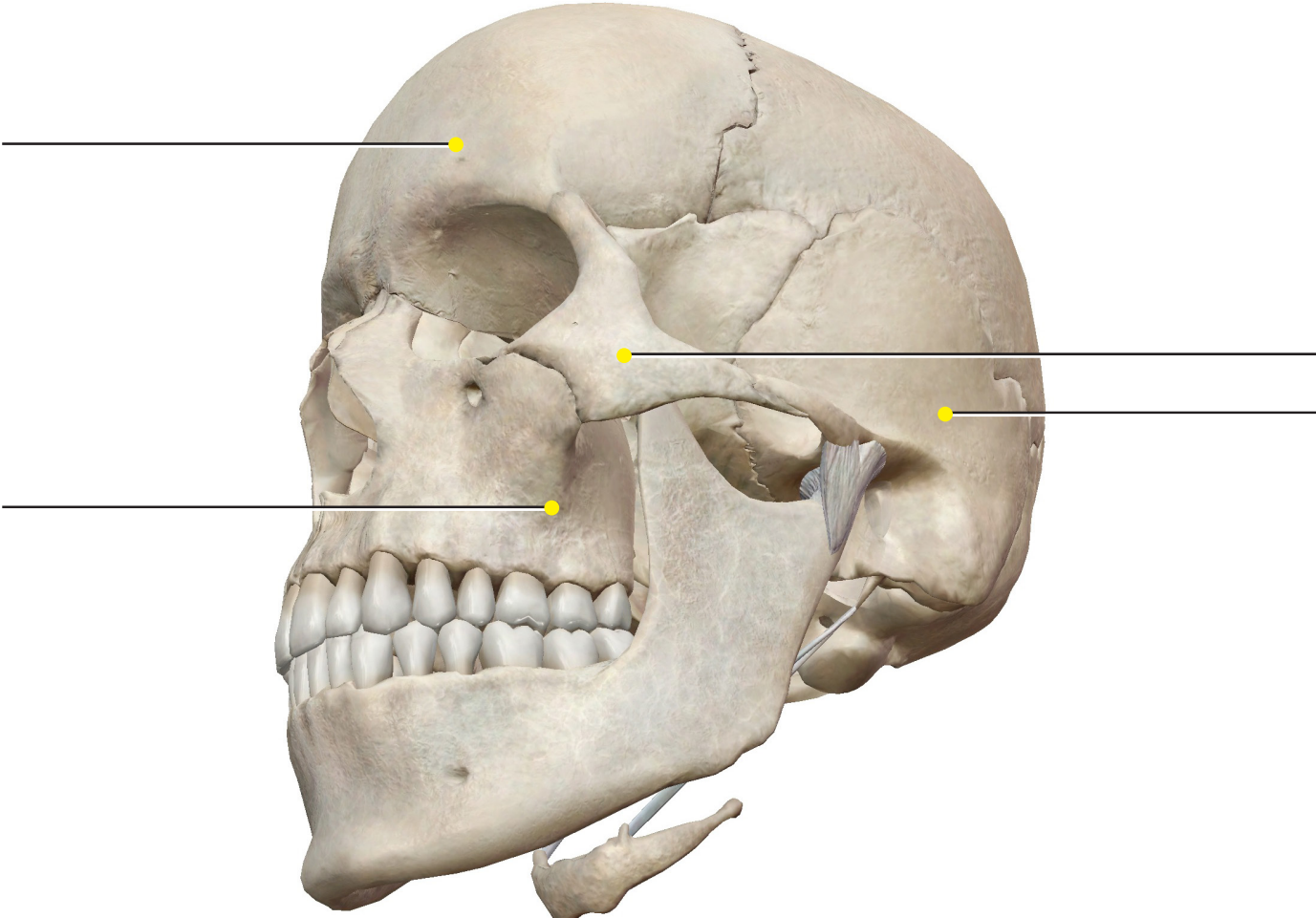
Source: Skeletal System Views: View 2. Skull



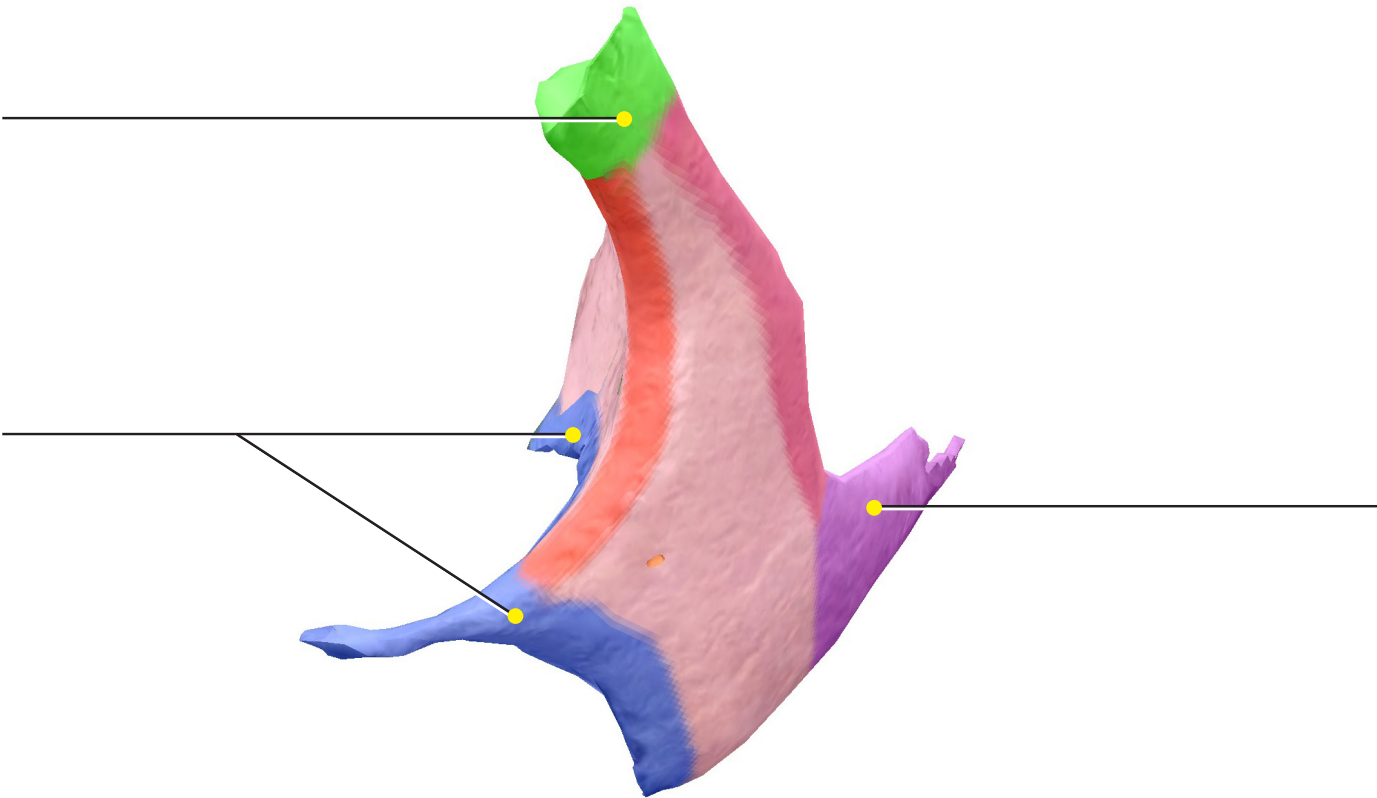
Source: Skeletal System Views: View 2. Skull



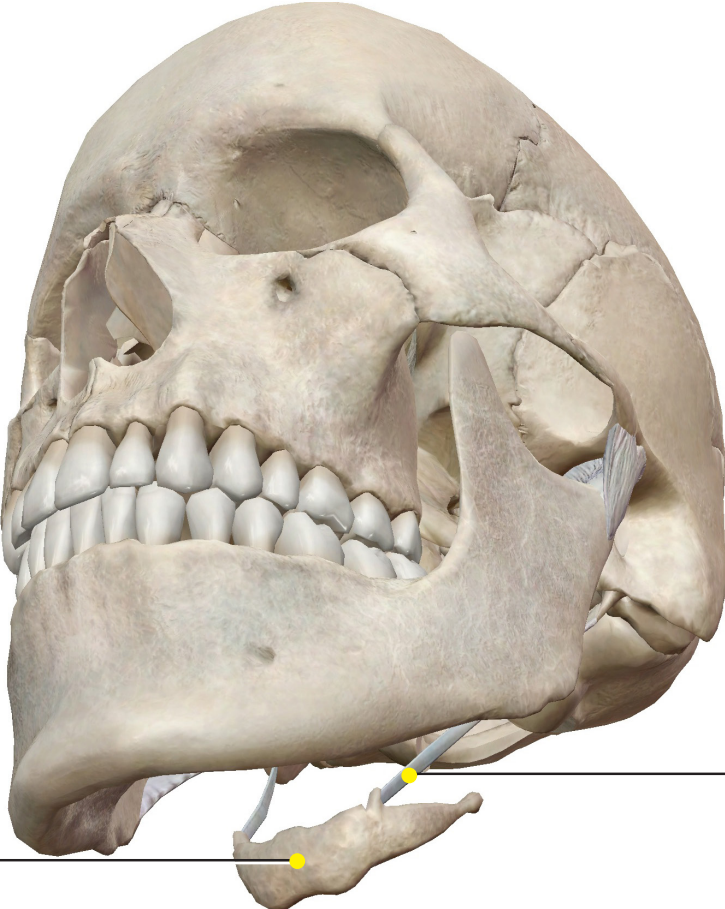
Source: Skeletal System Views: View 2. Skull



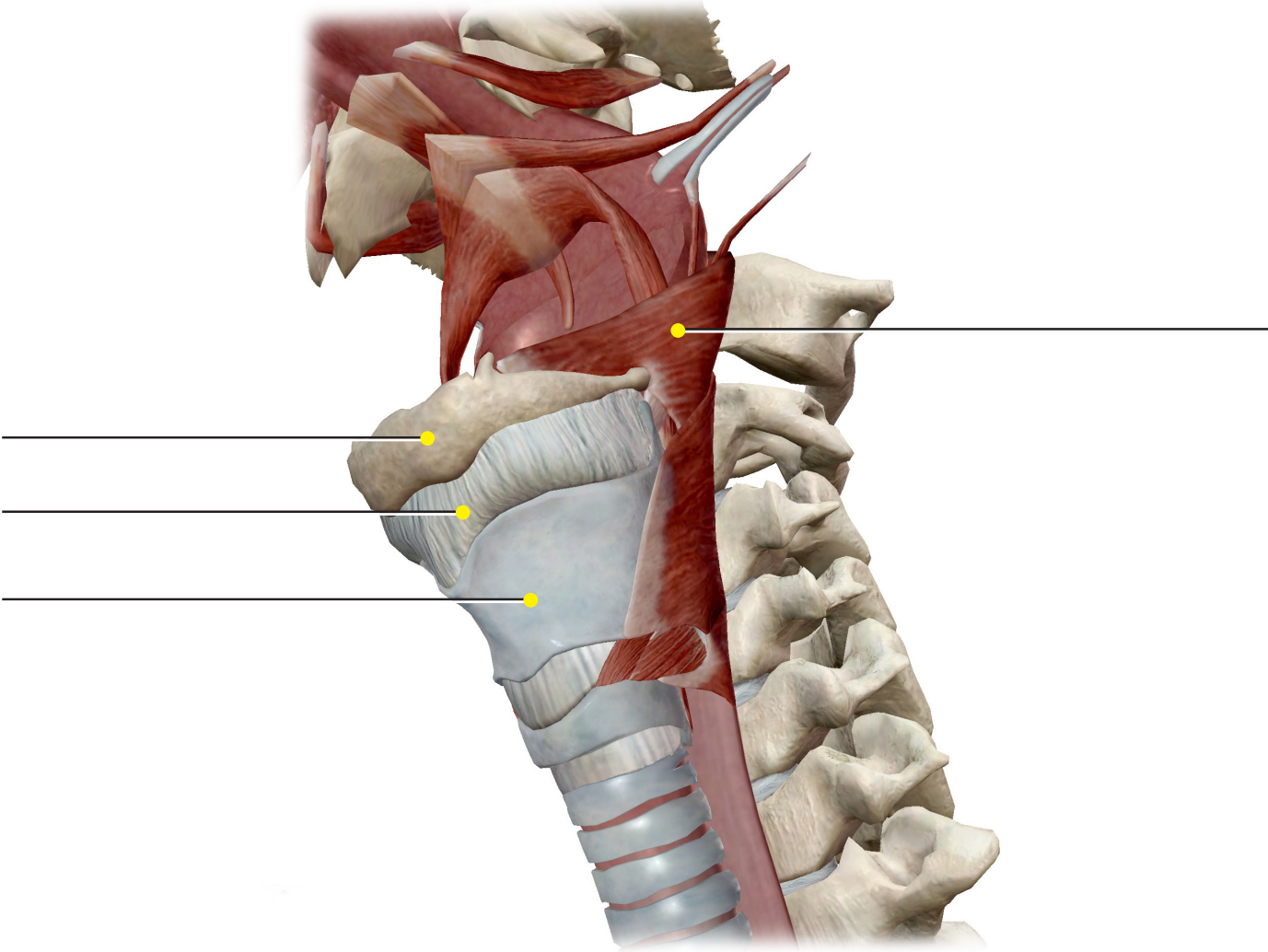
Source: Skeletal System Views: View 2. Skull



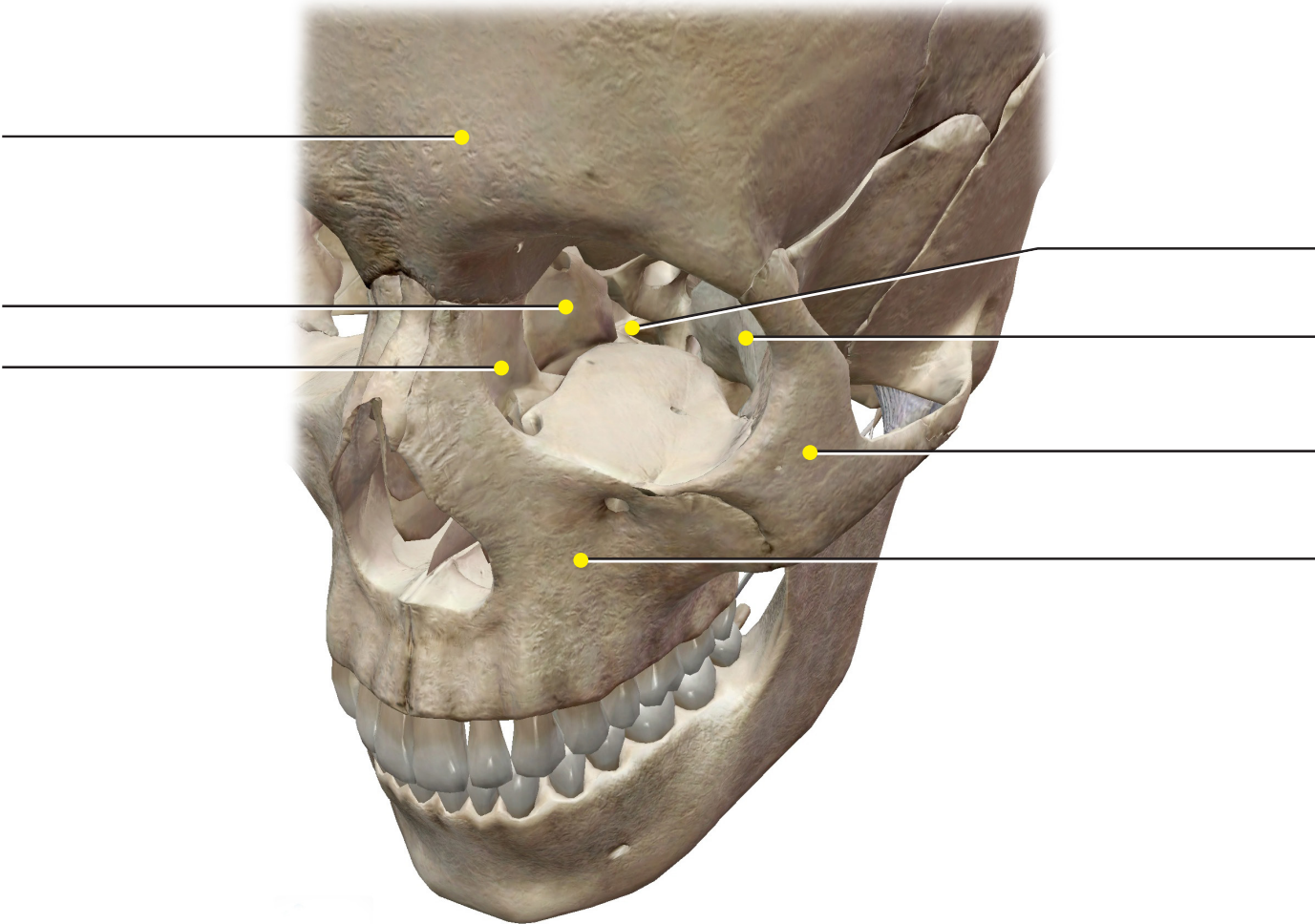
Source: Skeletal System Views: View 2. Skull



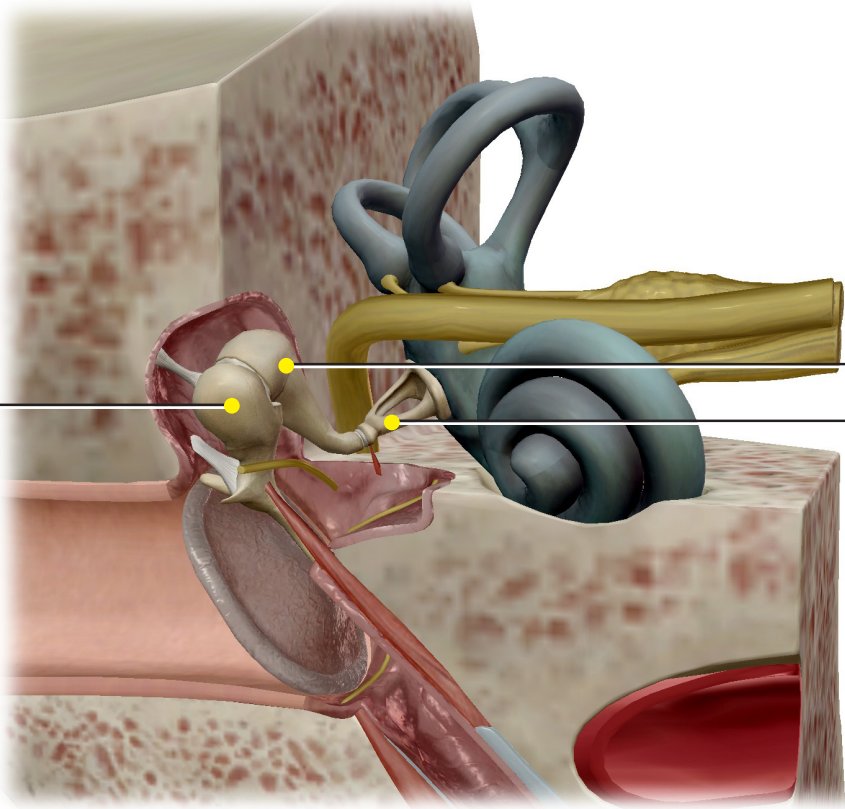
Source: Respiratory System Views: View 4. Pharynx and Larynx



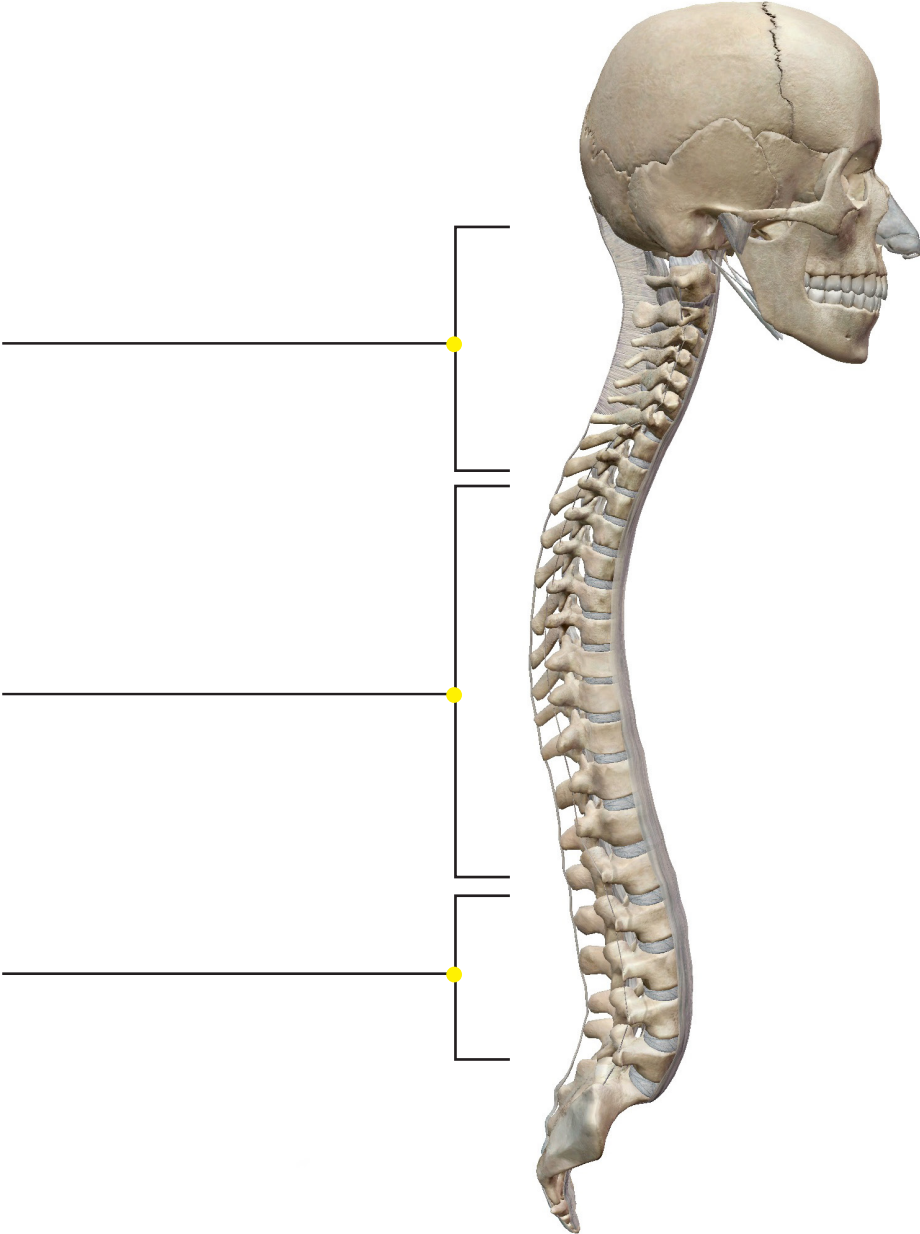
Source: Skeletal System Views: View 2. Skull



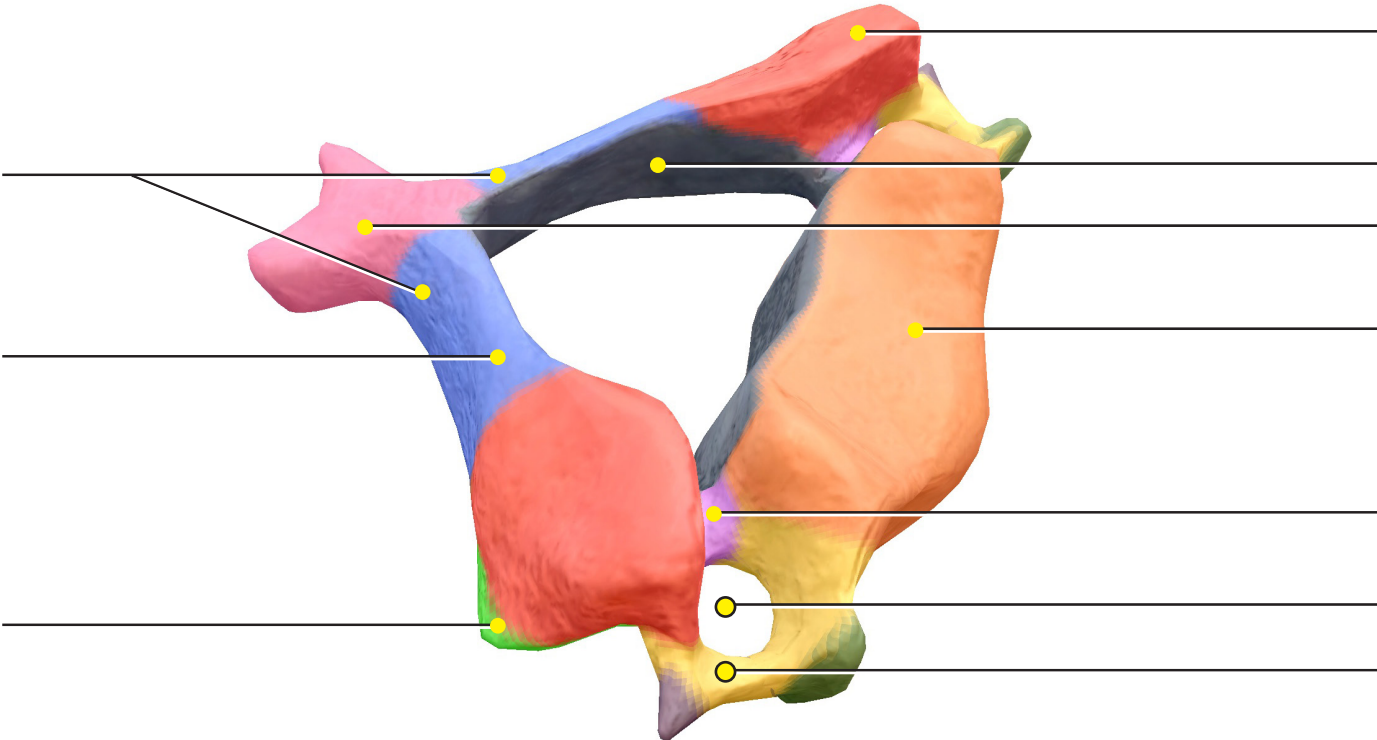
Source: Microanatomy Views: View 3. Inner Ear



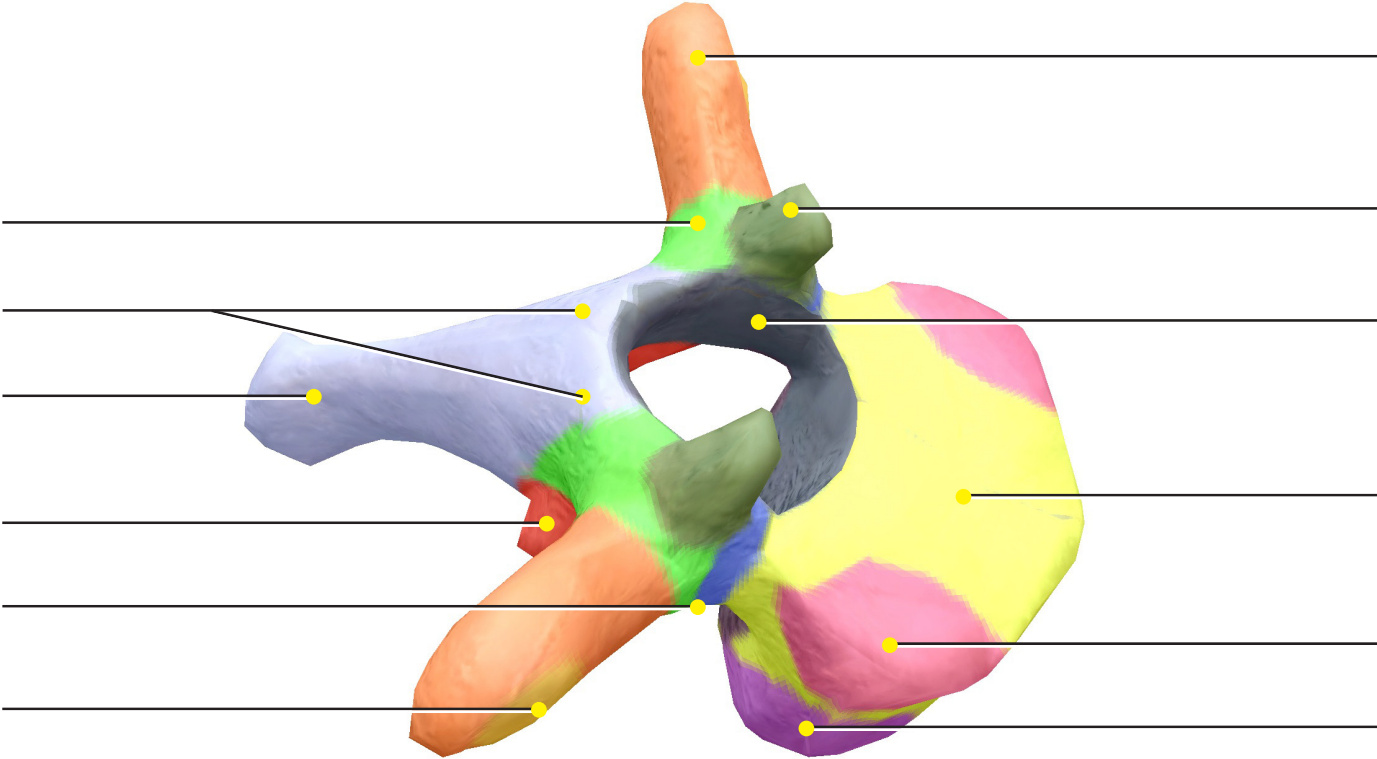
Source: Skeletal System Views: View 13. Spine, Lateral



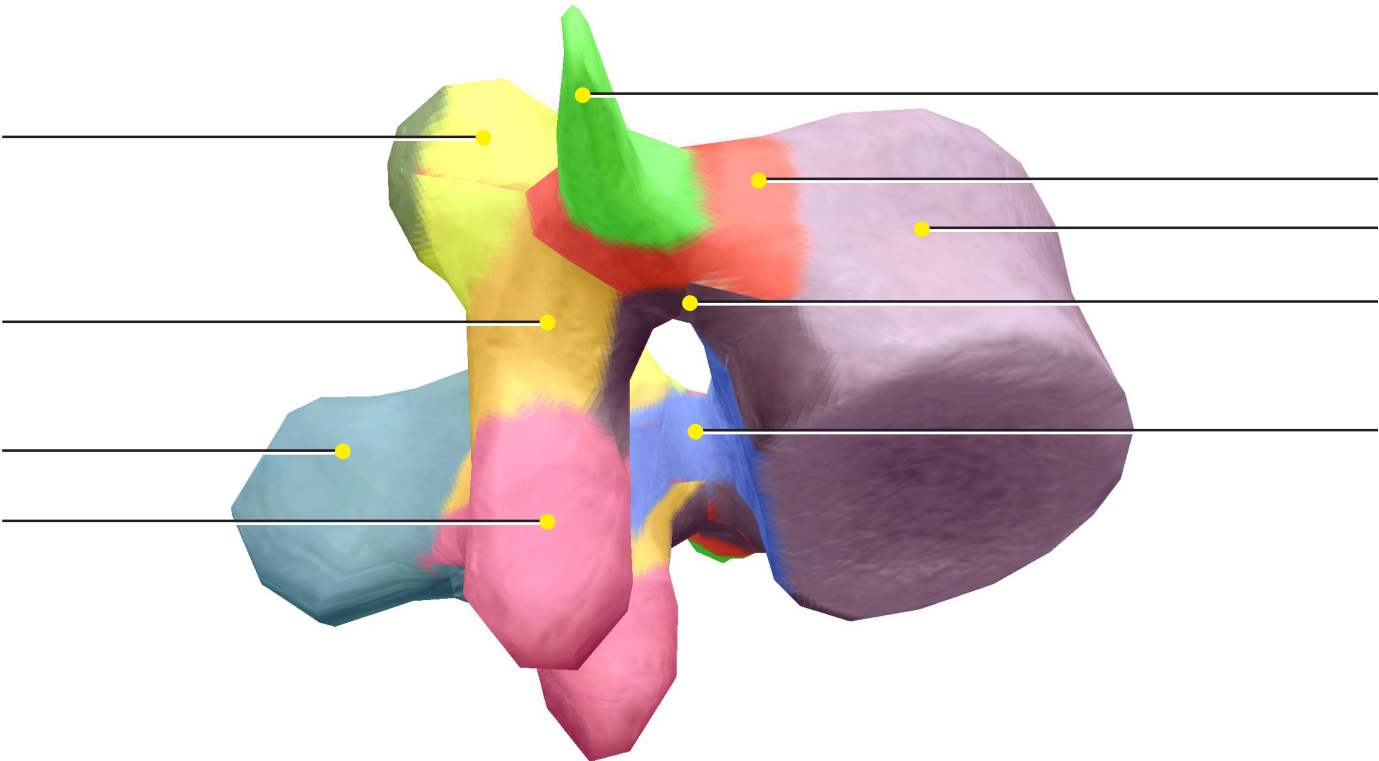
Source: Skeletal System Views: View 13. Spine, Lateral



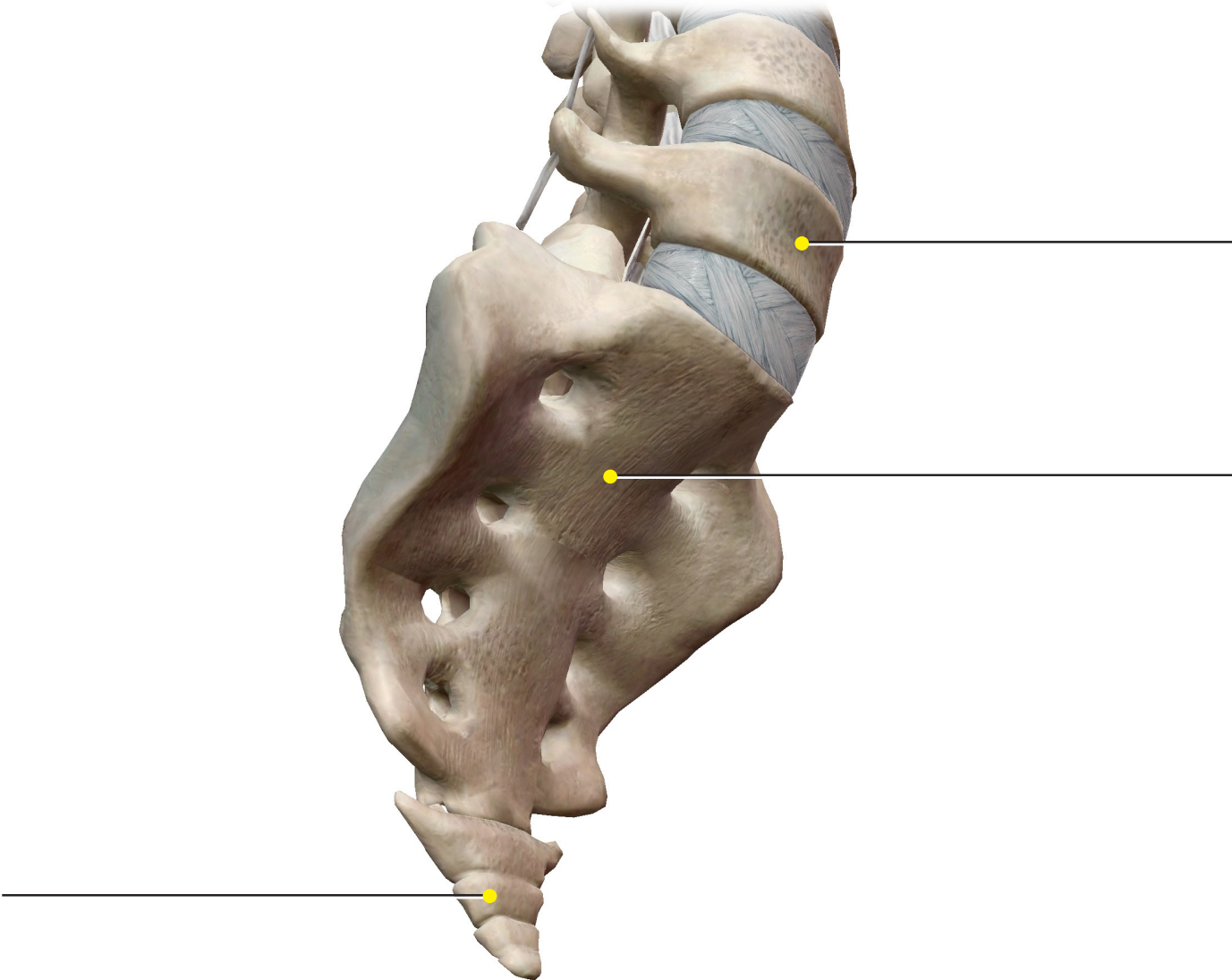
Source: Skeletal System Views: View 13. Spine, Lateral



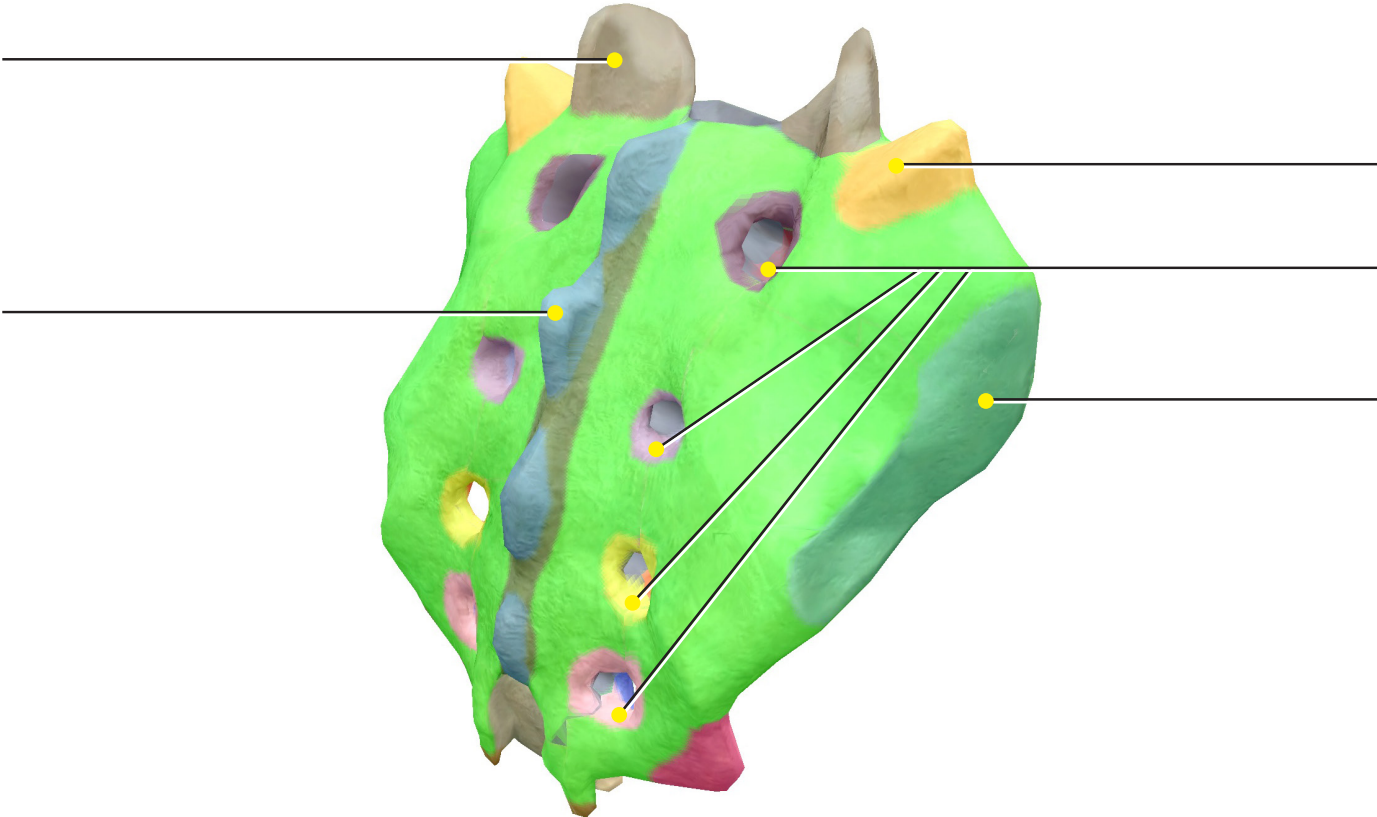
Source: Skeletal System Views: View 13. Spine, Lateral



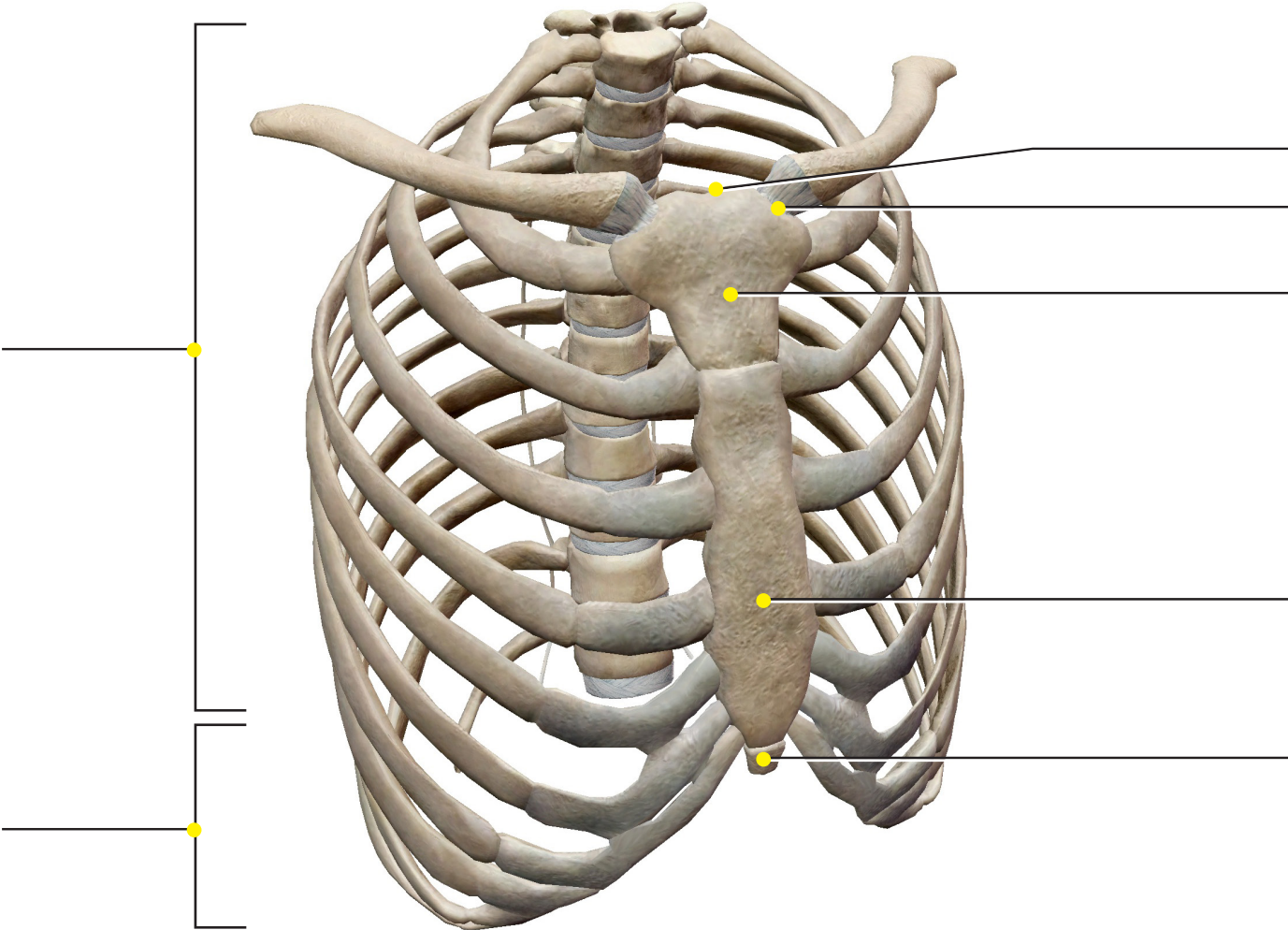
Source: Skeletal System Views: View 13. Spine, Lateral



Source: Skeletal System Views: View 13. Spine, Lateral



Source: Skeletal System Views: View 9. Thoracic Cage



Source: Skeletal System Views: View 13. Thoracic Cage

