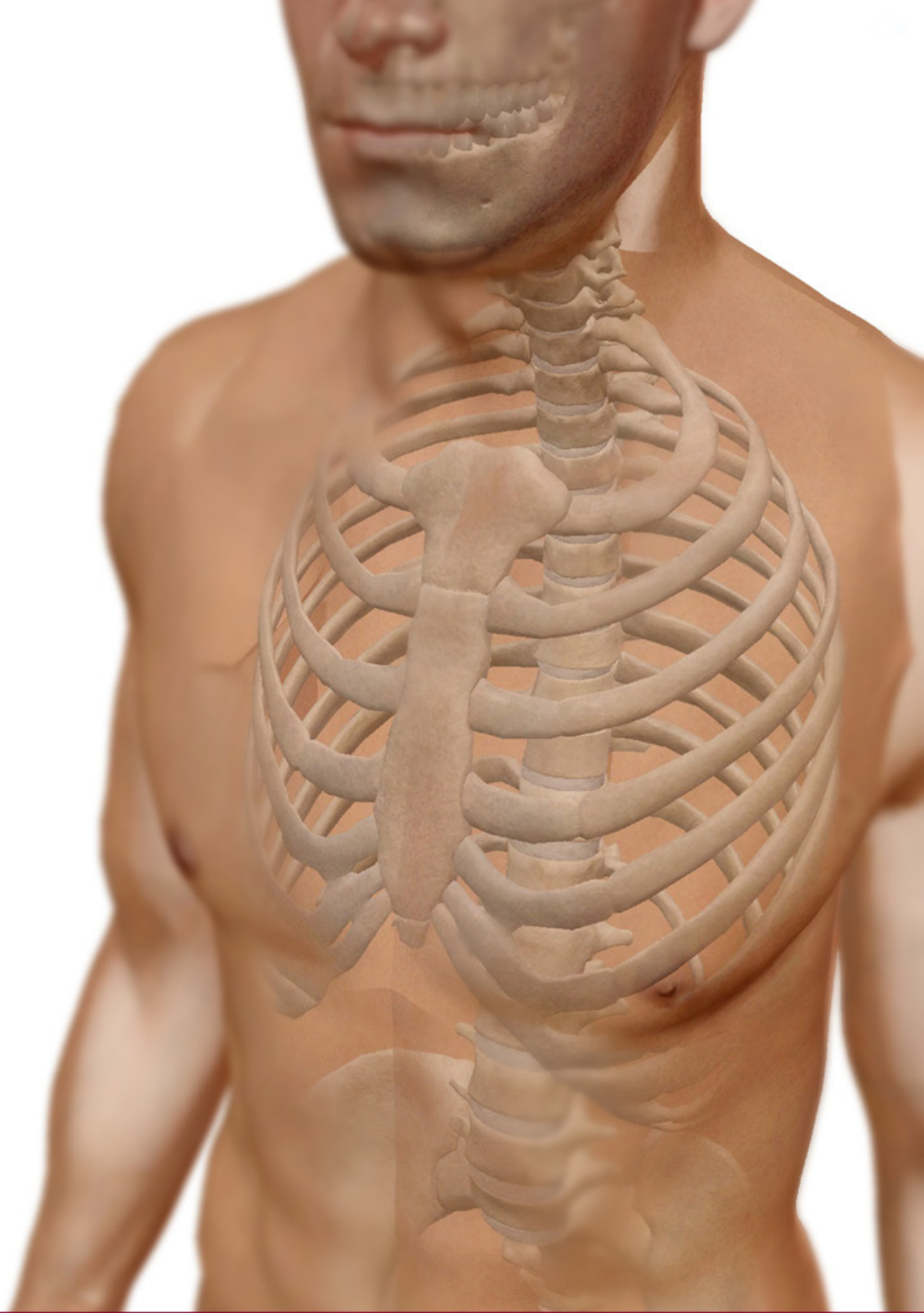

The Axial Skeleton

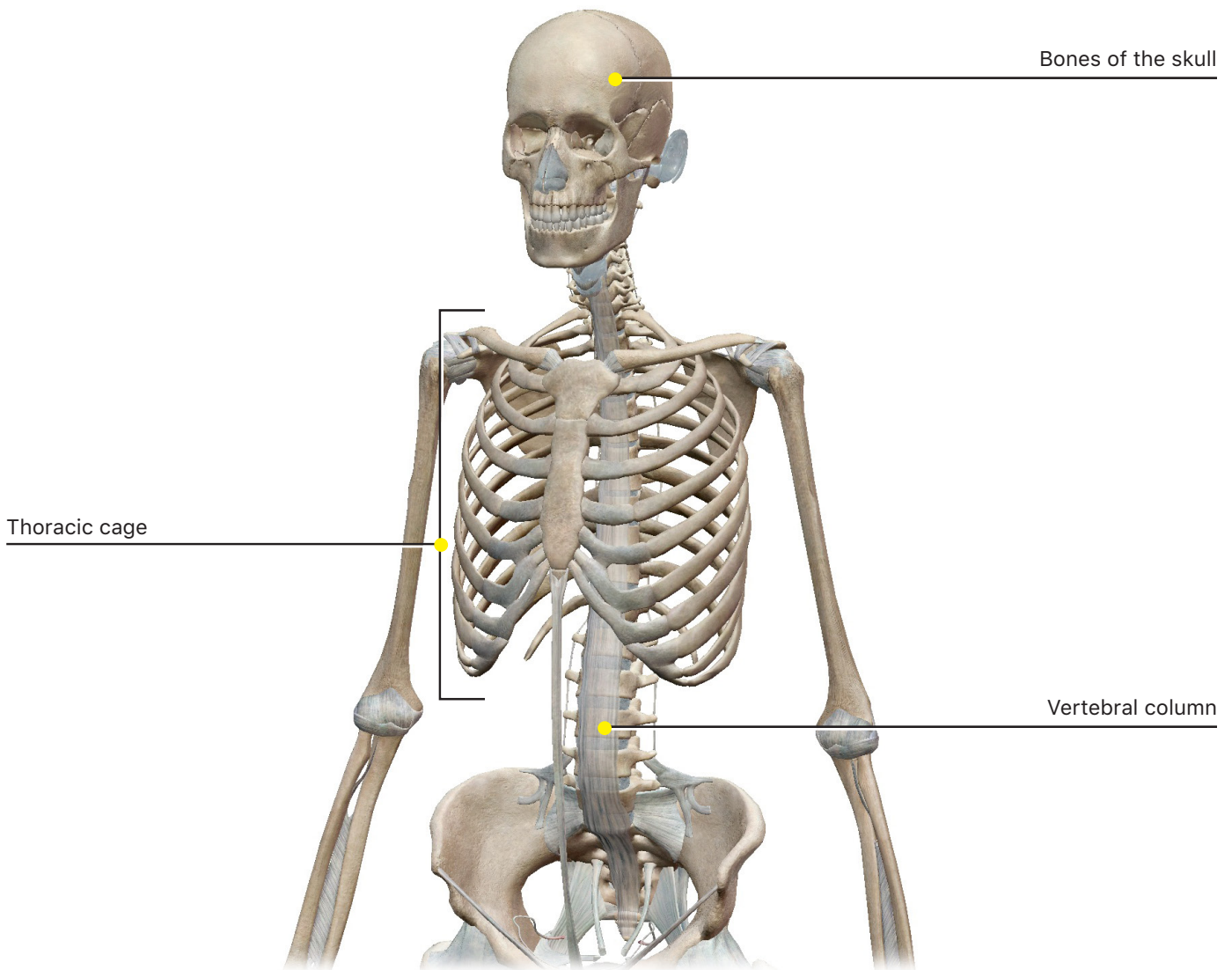
A skeletal system lab activity using Visible Body's Anatomy & Physiology

Stephanie Wallace, Instructor of Biology, TCU

PRE-LAB EXERCISES

When studying the skeletal system, the bones are often sorted into two broad categories: the axial skeleton and the appendicular skeleton. This lab focuses on the axial skeleton, which consists of the bones that form the axis of the body. The axial skeleton includes bones in the skull, vertebral column, and thoracic cage, as well as the auditory ossicles and hyoid bone. View Module 7.2 Axial and Appendicular Skeleton to highlight the bones of the axial skeleton and compare them to those of the appendicular skeleton. Examine Module 10.1 Axial Skeleton to view only the bones of the axial skeleton.

In addition to learning about all the bones of the axial skeleton, it is also important to identify some significant bone markings. Bone markings can have many shapes, including holes, round or sharp projections, and shallow or deep valleys, among others. These markings on the bones serve many purposes, including forming attachments to other bones or muscles and allowing passage of a blood vessel or nerve. It is helpful to understand the meanings of some of the more common bone marking terms.



Before we get started, look up the definitions of these common bone marking terms:

Canal:

Condyle:

Facet:

Fissure:

Foramen: (see Module 10.18 Foramina of Skull)

Fossa:

Margin:

Process:

Throughout this exercise, you will notice bold terms. This is meant to focus your attention on these important words. Make sure you pay attention to any bold words and know how to explain their definitions and/or where they are located.

Use the following modules to guide your exploration of the axial skeleton. As you explore these bones in Visible Body's app, also locate the bones and bone markings on any available charts, models, or specimens. You may also find it helpful to palpate bones on yourself or make drawings of the bones with the bone markings labeled. The drawings don't have to be perfect; just make sure the different bone markings are in the correct locations, relative to each other.

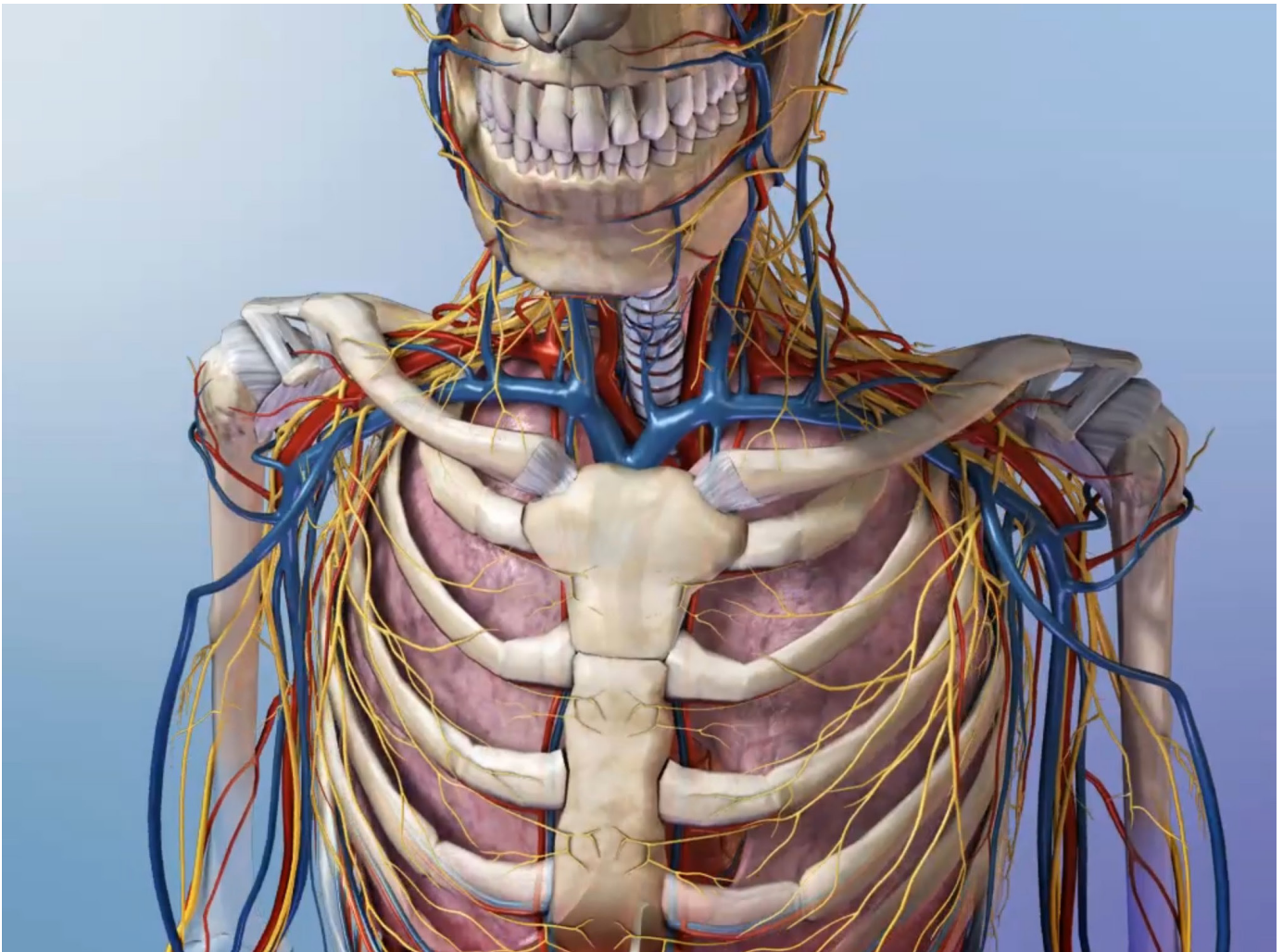
IN-LAB EXERCISES

Open the A&P app, and from the left-side menu, select the Skeletal System.

You are responsible for the identification of **all bold terms** and all answers to the questions.

A. Skeletal System Overview

Watch the video in Module 7.1 Skeletal System Overview, examine the 3D anatomical view in Module 7.3 Function of the Skeleton, and answer the following questions.



1. How does the skeletal system function to protect the body? Give a few examples.

a.

i.

ii.

iii.

2. In addition to providing structure and protection, what other functions does the skeletal system perform?

a.

b.

c.

B. Types of Bones

Bones have many different shapes, and the shape of a bone frequently correlates to its function.

View the following modules and use them to answer the questions.

8.1 Bone Types

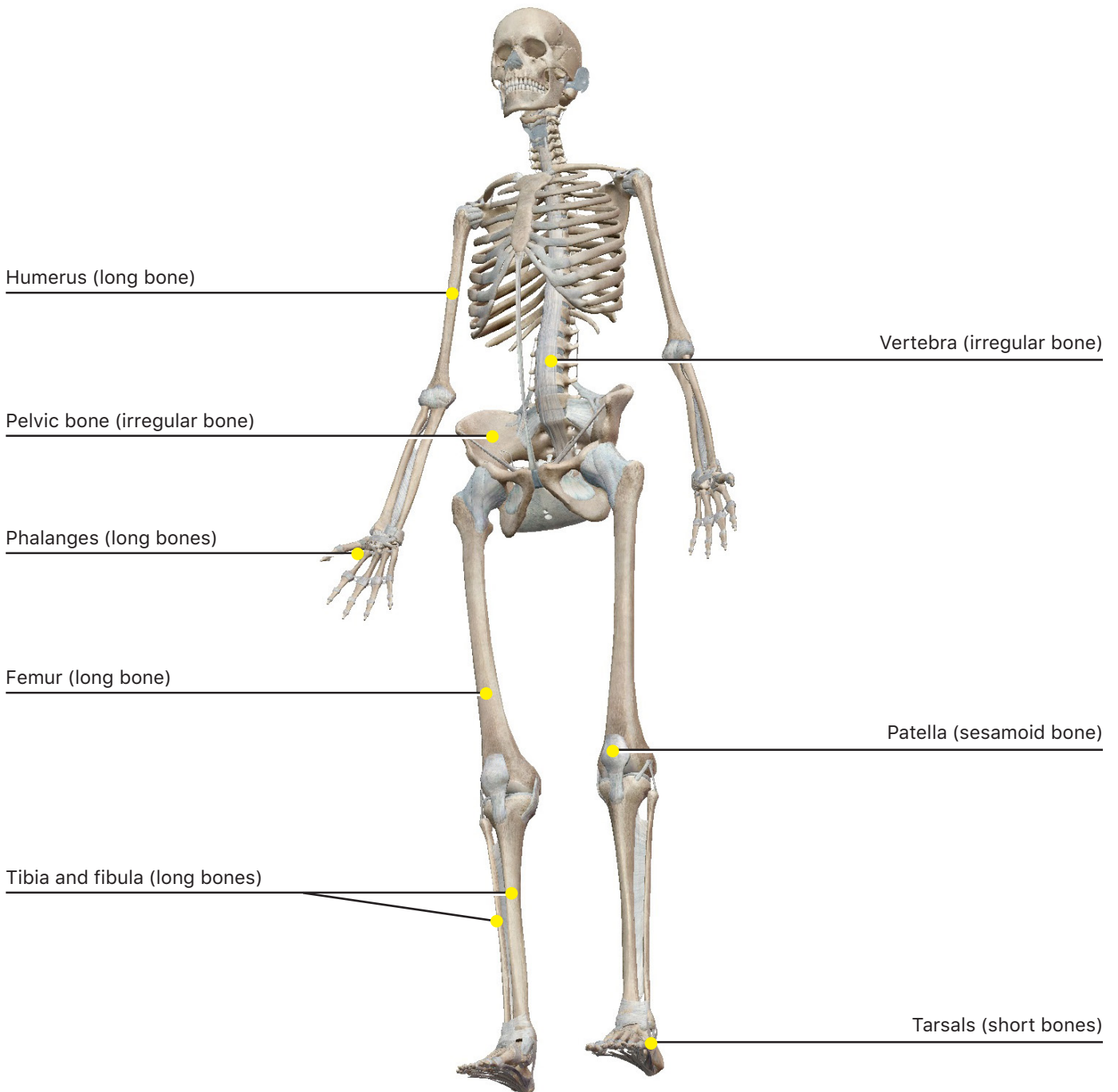
8.2 Flat Bones

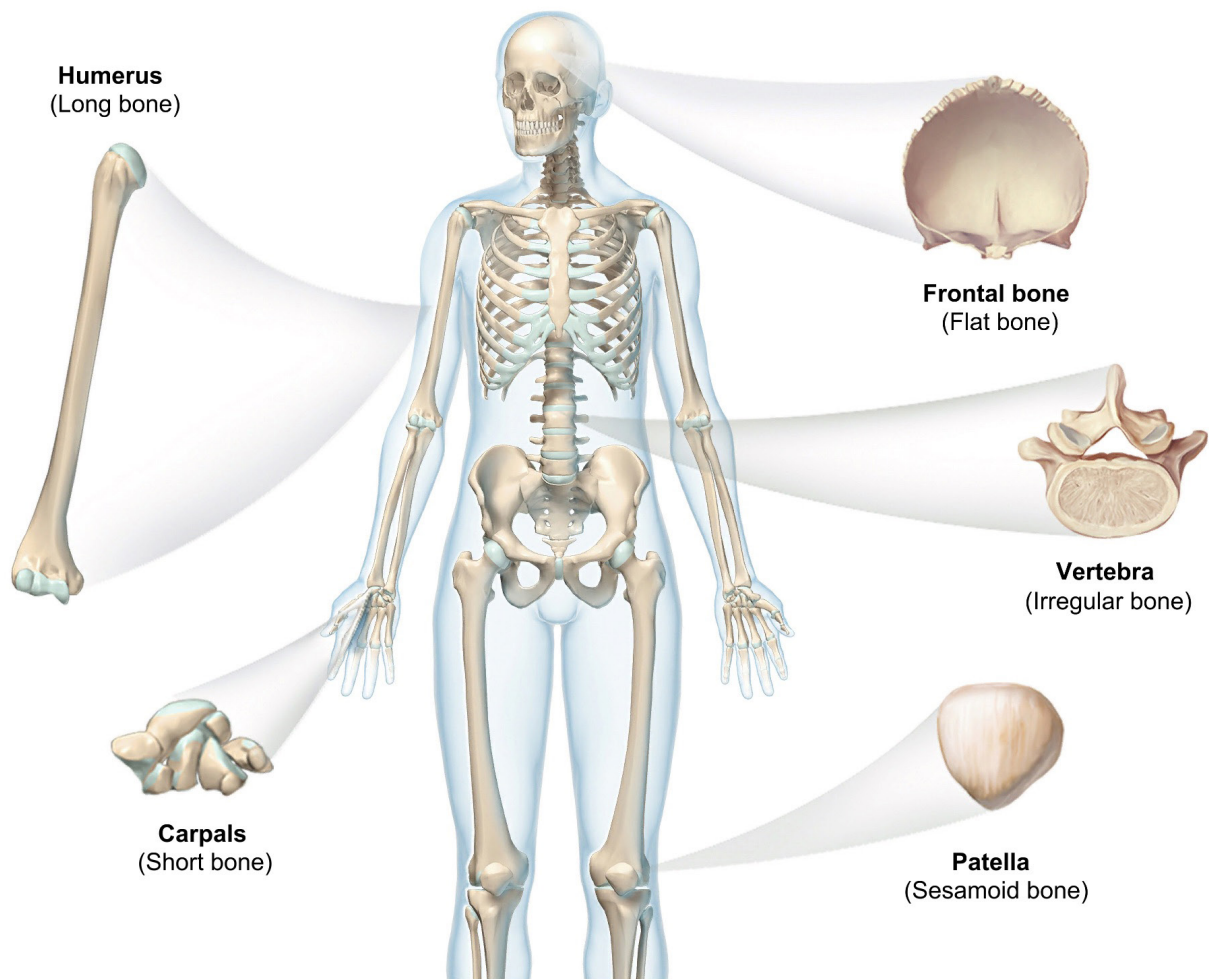
8.3 Long Bones

8.4 Short Bones

8.5 Irregular Bones

8.6 Sesamoid Bones





1. Which bone type is found in the wrist?

2. Which bone type reinforces tendons to protect them from wear?

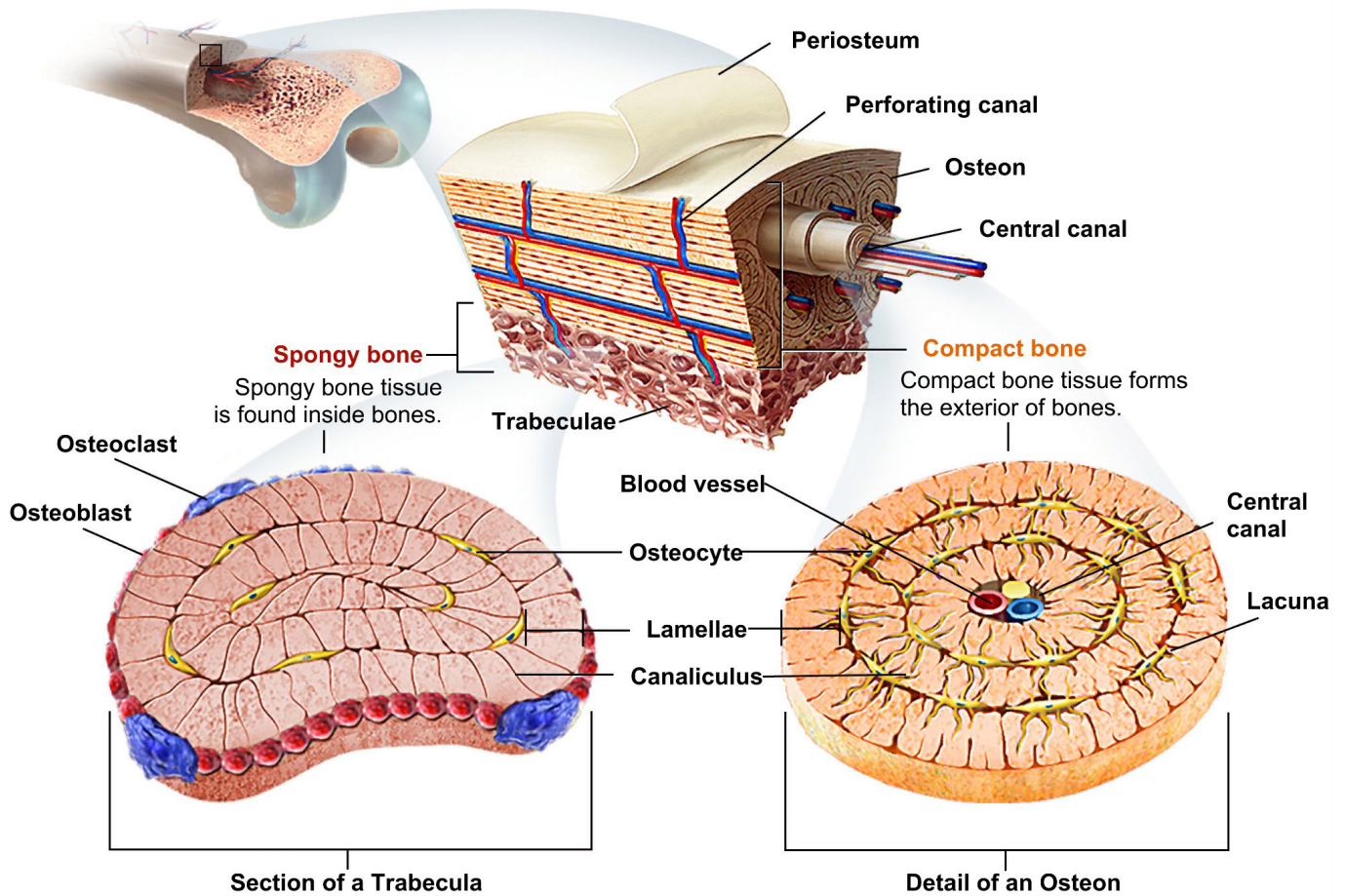
3. The humerus and femur are long bones that support weight and facilitate movement. What other bones are classified as long bones?

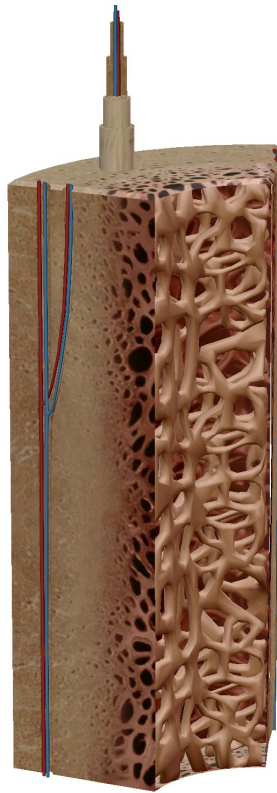
4. Which bone type protects internal organs? Give two examples.

C. Bone tissue

Bone tissue serves important functions in the body. In addition to facilitating movement and providing attachments for muscles, bones are important sources of calcium and phosphate in the body, since these minerals are stored in the extracellular matrix of bone tissue.

View Modules 9.4 Compact and Spongy Bone Tissue, 9.5 Osteon, and 9.6 Bone Cells and use them to answer the following questions.





Osteoclasts

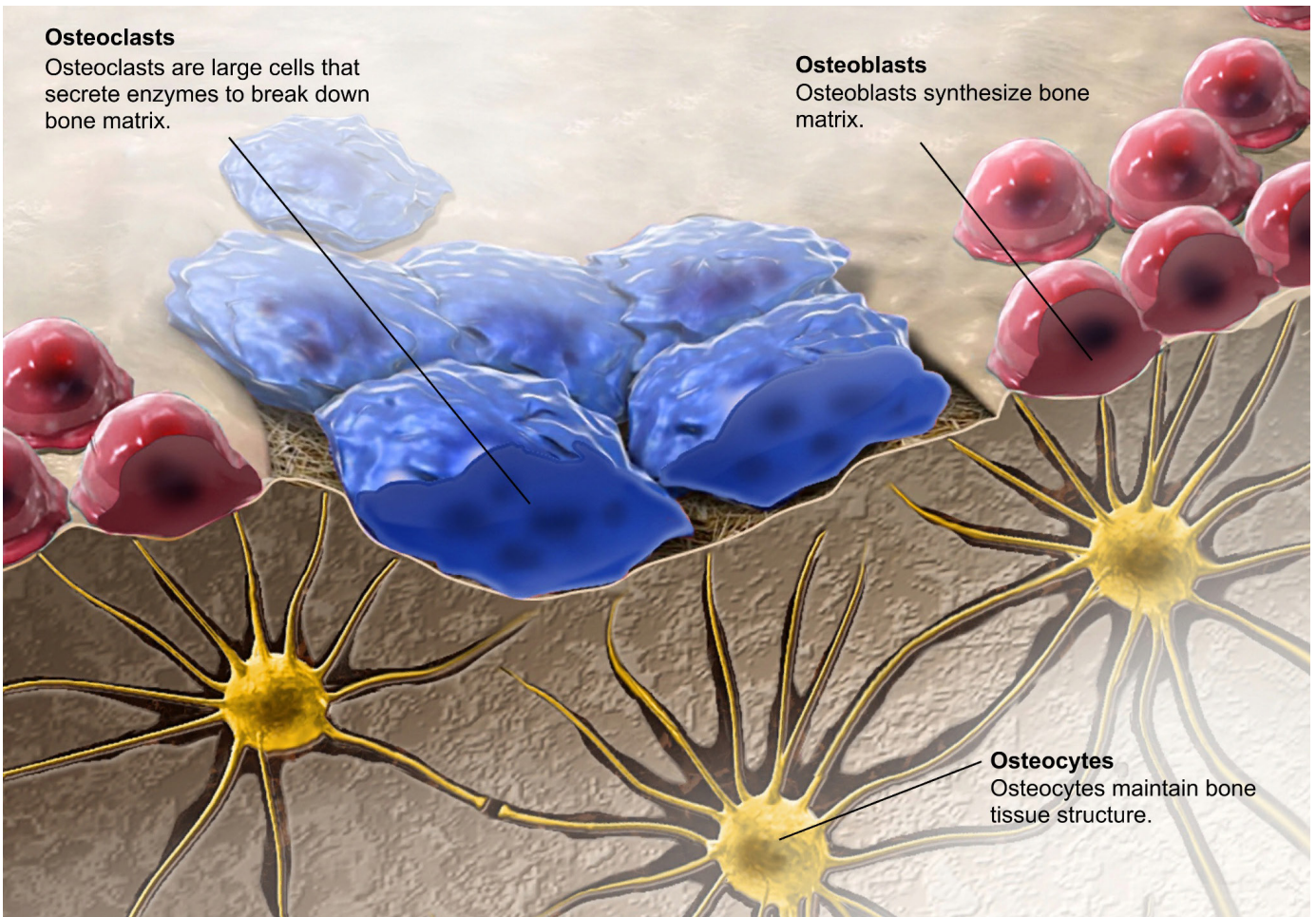
Osteoclasts are large cells that secrete enzymes to break down bone matrix.

Osteoblasts

Osteoblasts synthesize bone matrix.

Osteocytes

Osteocytes maintain bone tissue structure.



1. What is the basic functional unit of **compact bone**?

2. What are some differences between spongy and compact bone?

3. What is the purpose of the **central canal** in **osteons**?

4. Regarding bone cells:
 - a. What is connective tissue? (Review Module 4.3 Connective Tissue, if needed.)

 - b. What is the extracellular matrix?

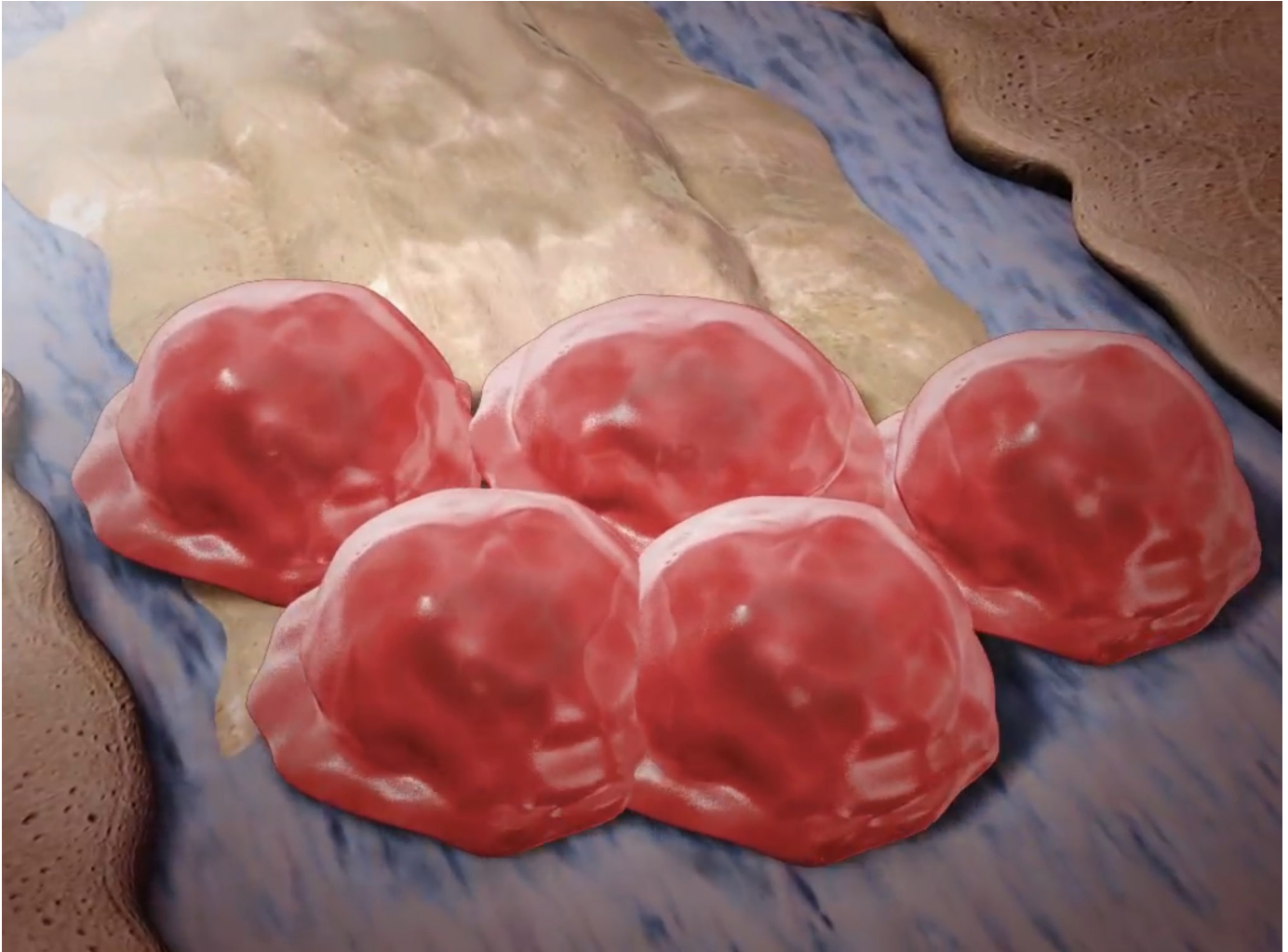
 - c. Which bone cells are responsible for synthesizing new bone matrix?

 - d. Which bone cells break down bone matrix?

 - e. Which bone cells maintain the bone matrix around them?

D. Flat bone formation

Watch the video in Module 9.7 Flat Bone Formation and explore the 3D anatomical view in Module 9.8 Flat Bones in the Skull to see how flat bones are formed in the skull.

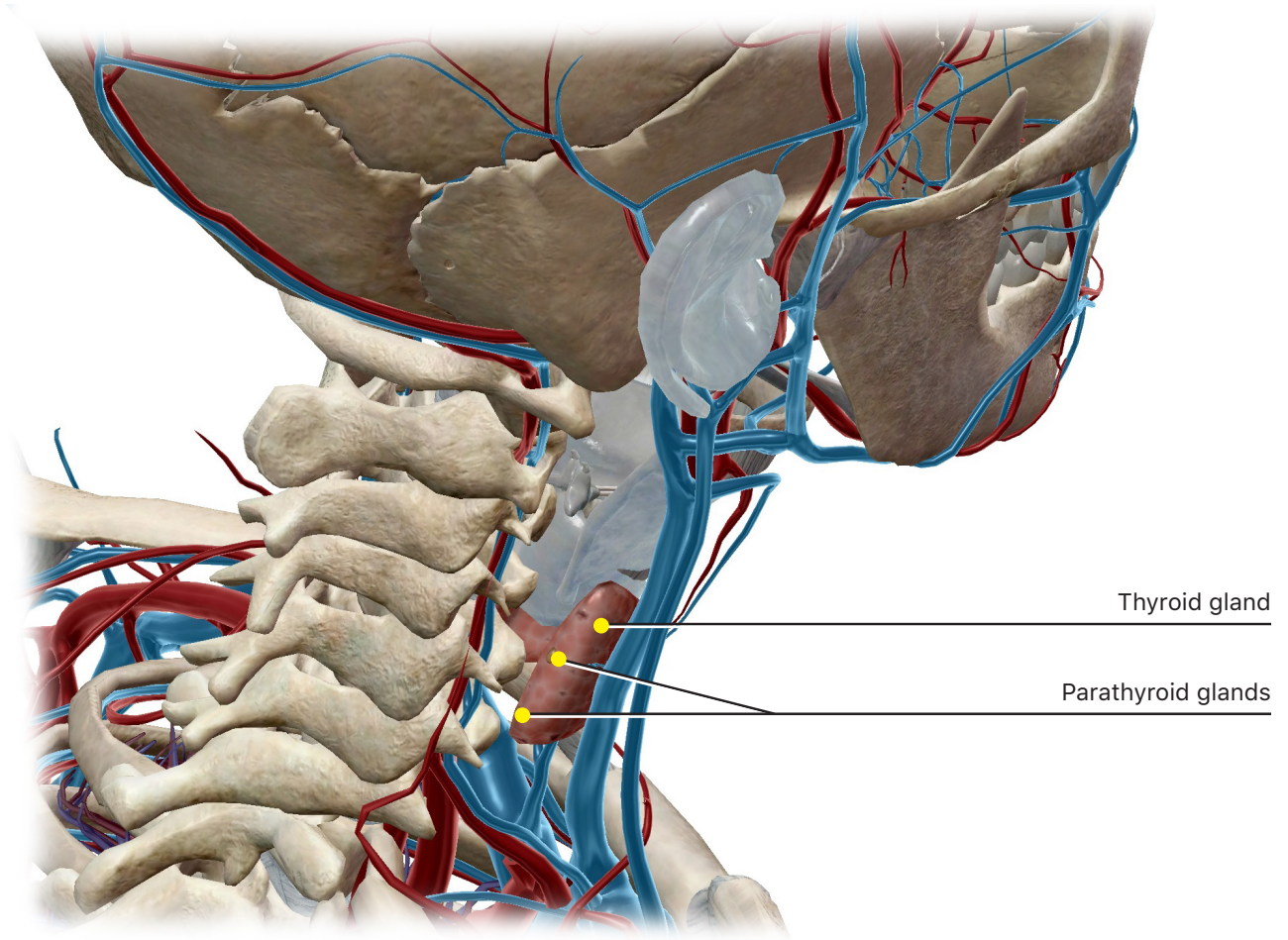


1. What is the basic structure of flat bones once they are created?
2. What structure covers the bone?
3. What is the process of flat bone formation called?

E. Calcium Homeostasis

Examine the 3D anatomical views in Modules 9.13 Calcium in the Skeleton and 9.15 Healthy and Osteoporotic Bone, watch the video in Module 9.14 Osteoporosis, and answer the following questions.

Module 9.13 Calcium in the Skeleton



1. Why is calcium necessary in our bodies?
2. What glands are responsible for secreting hormones that maintain calcium homeostasis?
3. Normally, bone is broken down at about the same rate as it is synthesized. What happens when bone resorption (breakdown) outpaces bone deposition (synthesis)?
4. What are some symptoms of **osteoporosis**?

IN-LAB EXERCISES

Open the A&P app, and from the left-side menu, select the Skeletal System.

You are responsible for the identification of **all bold terms** and all answers to the questions.

A. The Skull

The **skull** is composed of two parts: the **cranium** and the **facial bones**. The cranium is responsible for protecting the brain, while the facial bones form the framework of the face and support for the special senses (sight, smell, and taste).

After observing the following modules, identify the bone markings and answer the questions.

10.2 Skull

10.3 Cranial Bones

10.4 Occipital Bone Landmarks

10.5 Temporal Bone Landmarks

10.6 Frontal Bone Landmarks

10.7 Sphenoid Bone Landmarks

10.8 Ethmoid Bone Landmarks

10.9 Skull Sutures

10.10 Fontanelles

10.11 Facial Skeleton I

10.12 Maxilla Landmarks

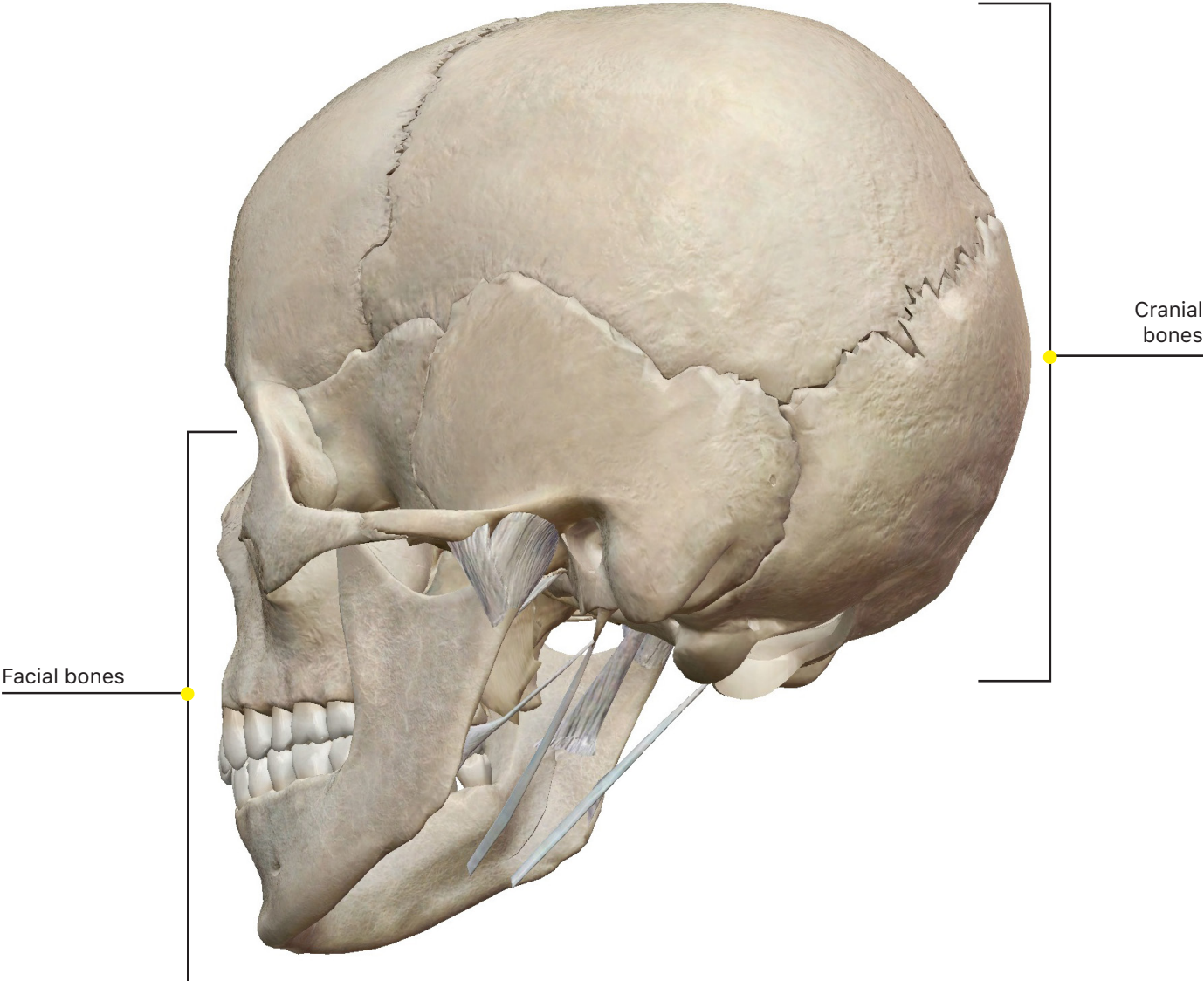
10.13 Mandible Landmarks

10.14 Facial Skeleton II

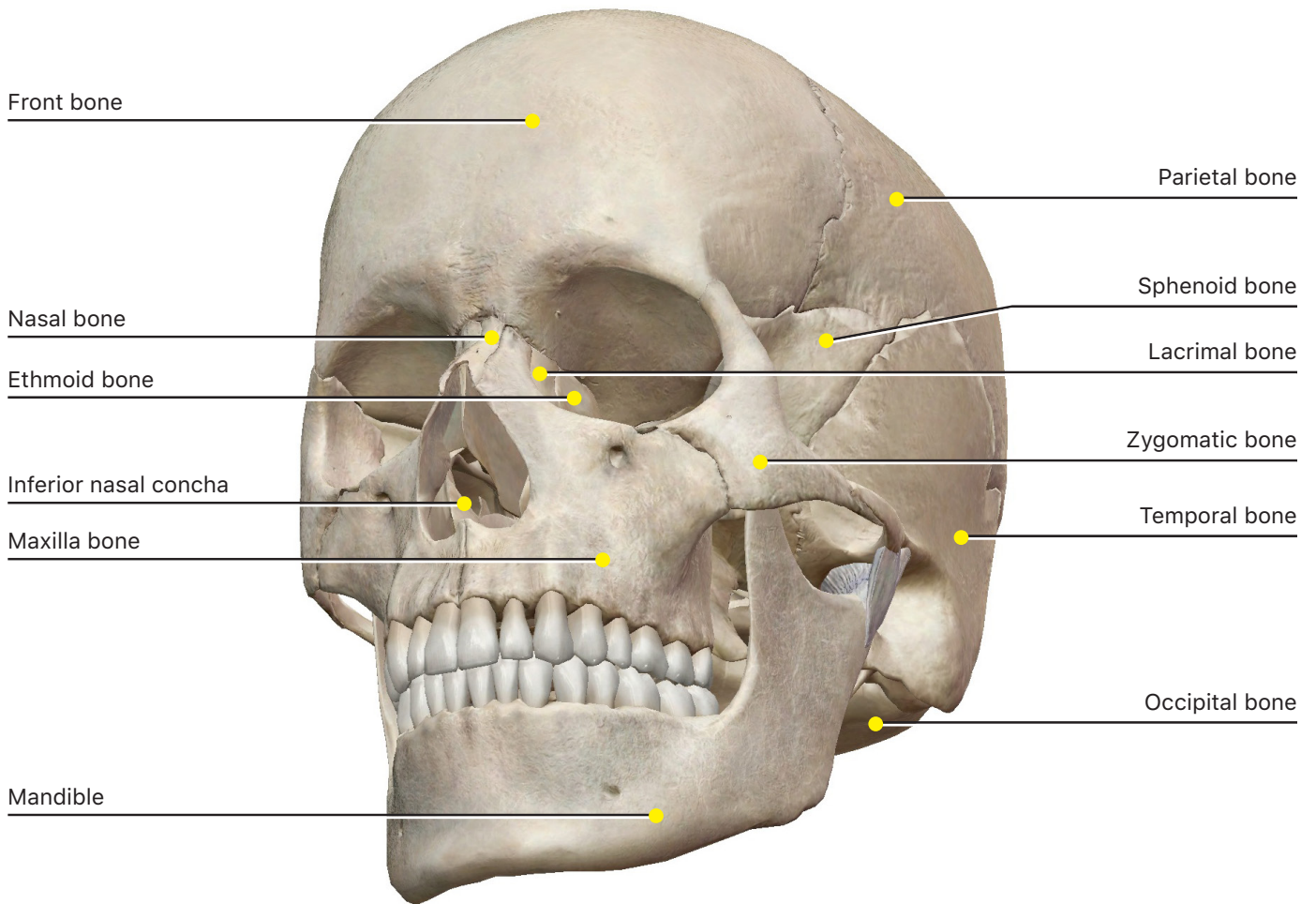
10.15 Palatine Bone Landmarks

10.16 Lacrimal Bone Landmarks

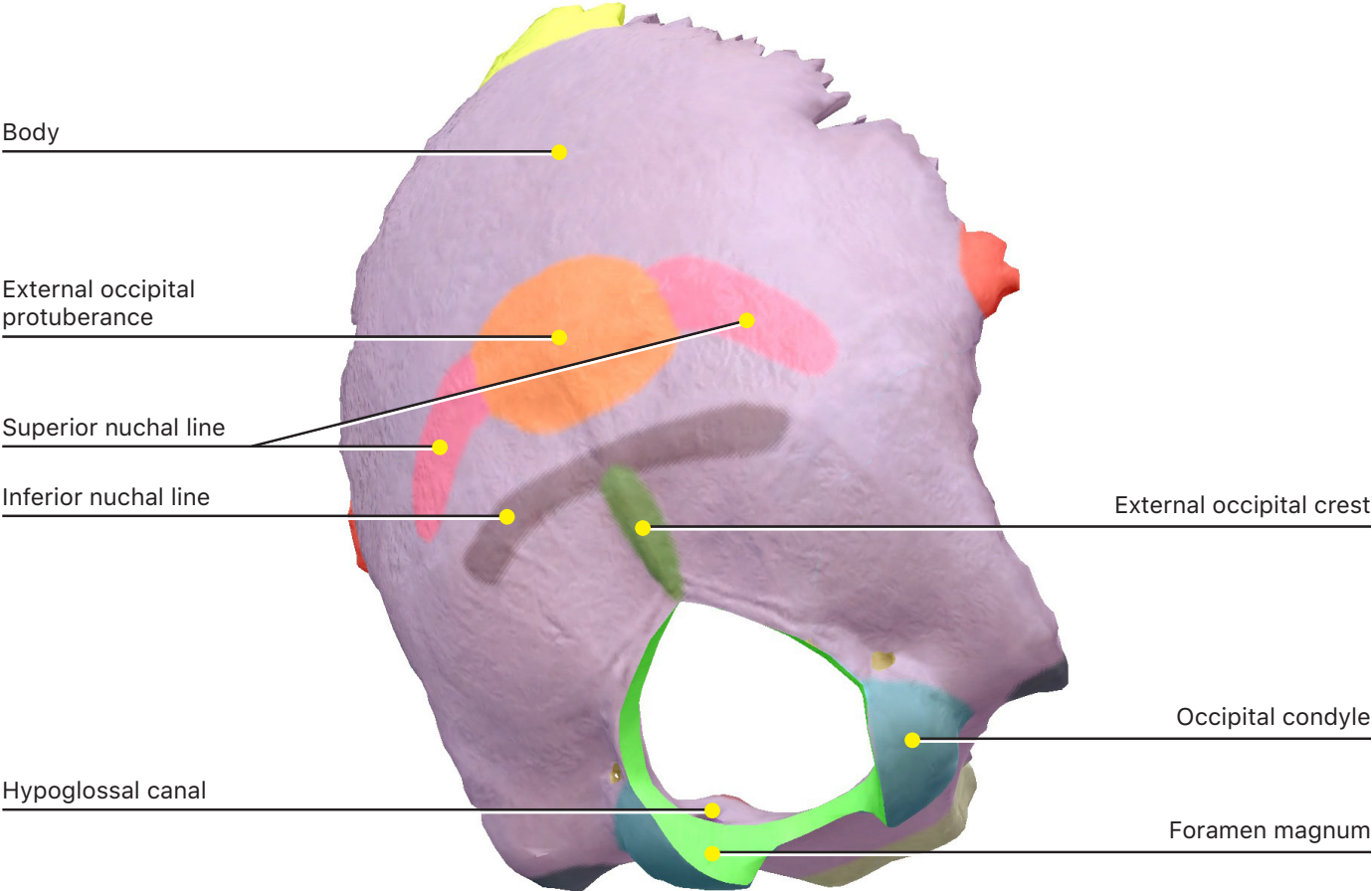
Module 10.2 Skull (Part 1)



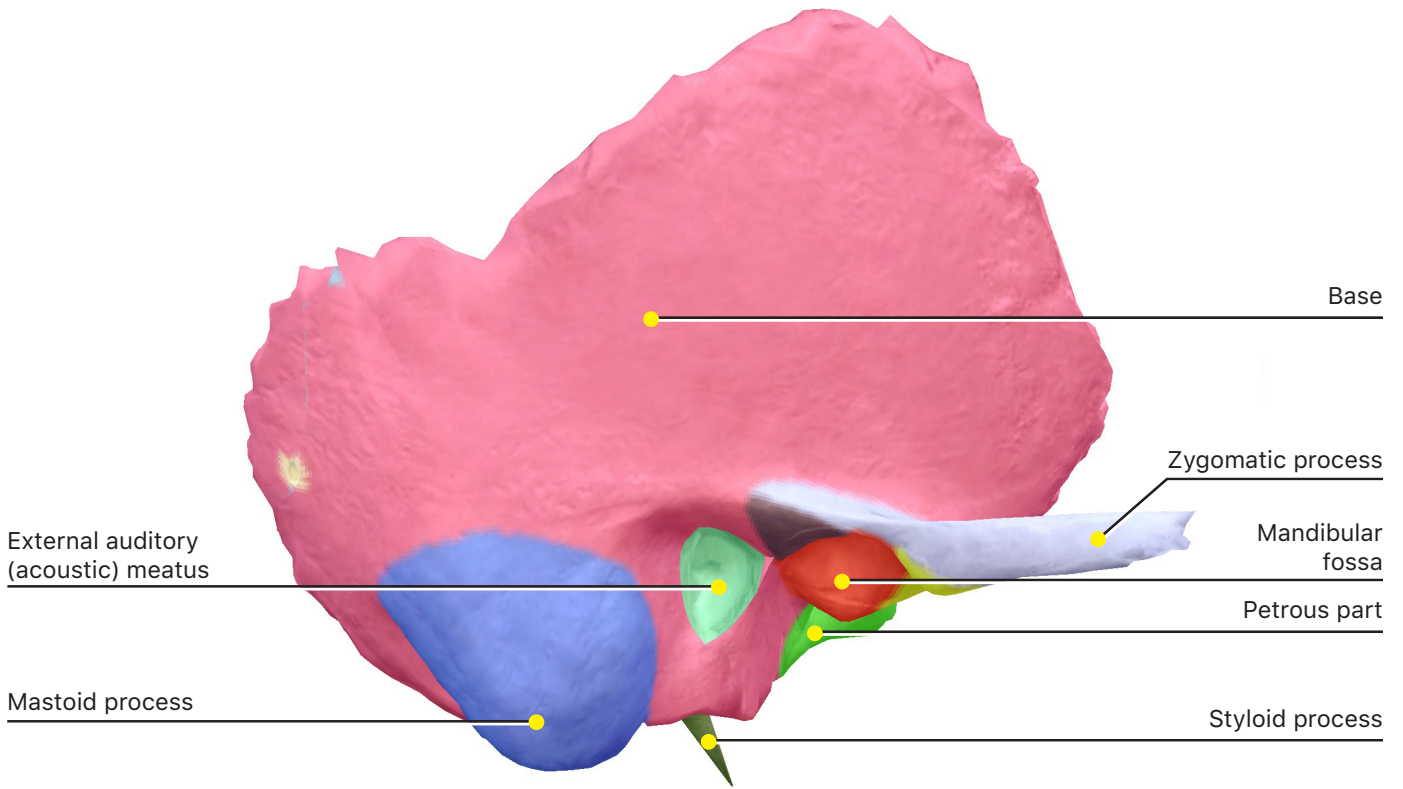
Module 10.2 Skull (Part 2)



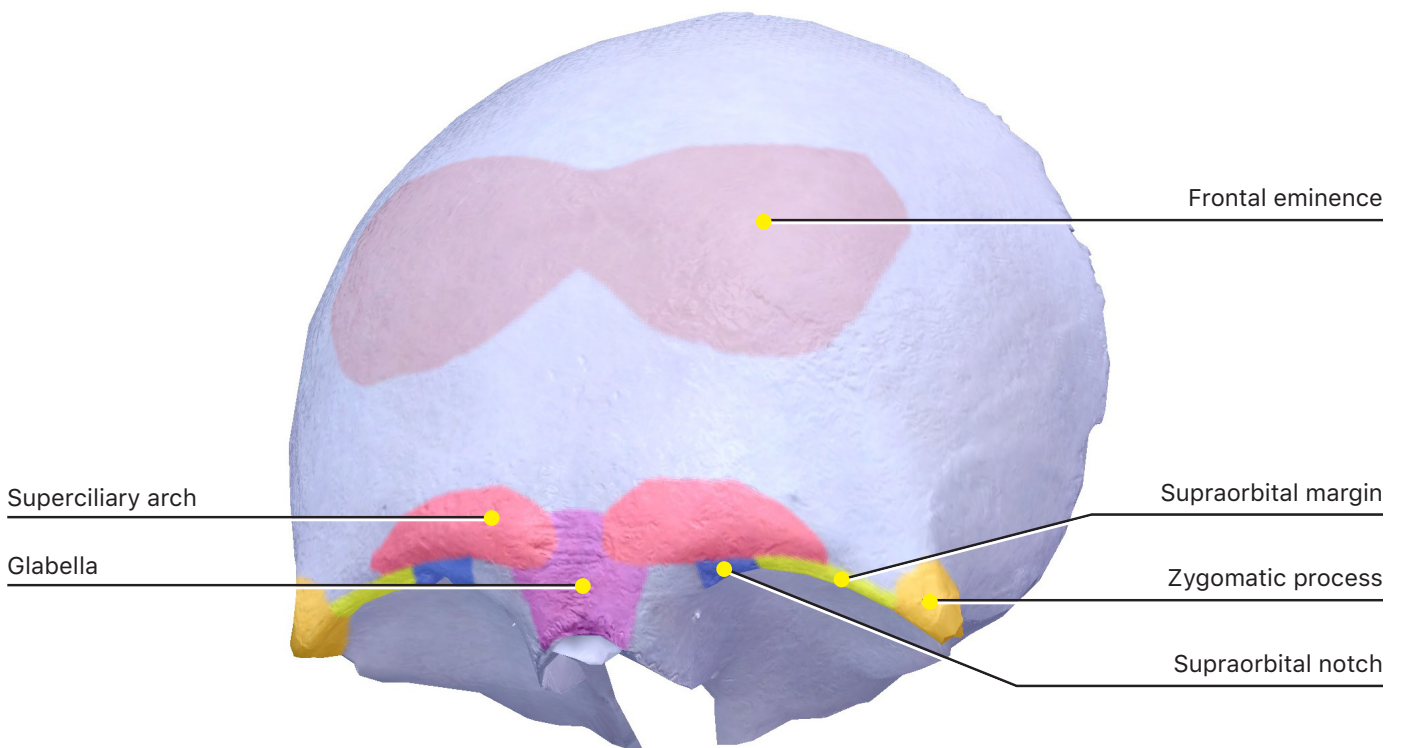
Module 10.4 Occipital Bone Landmarks



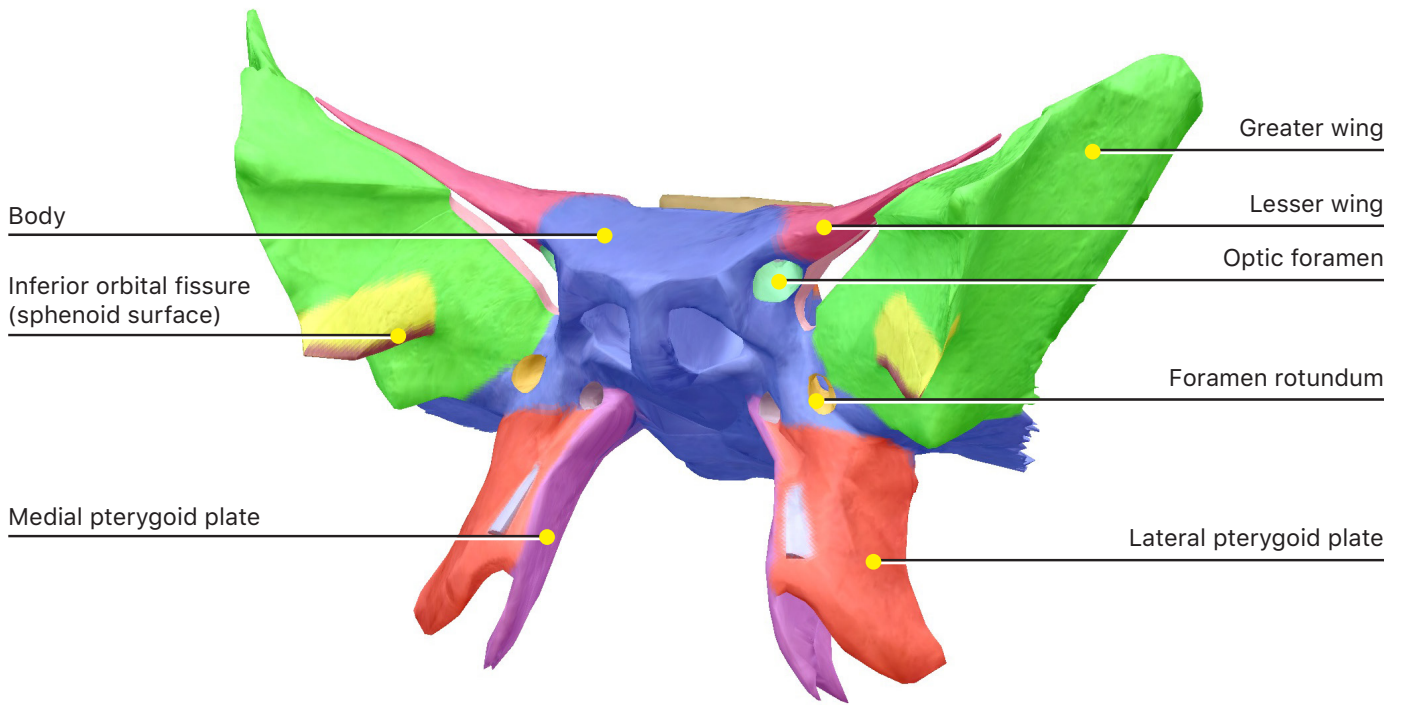
Module 10.5 Temporal Bone Landmarks



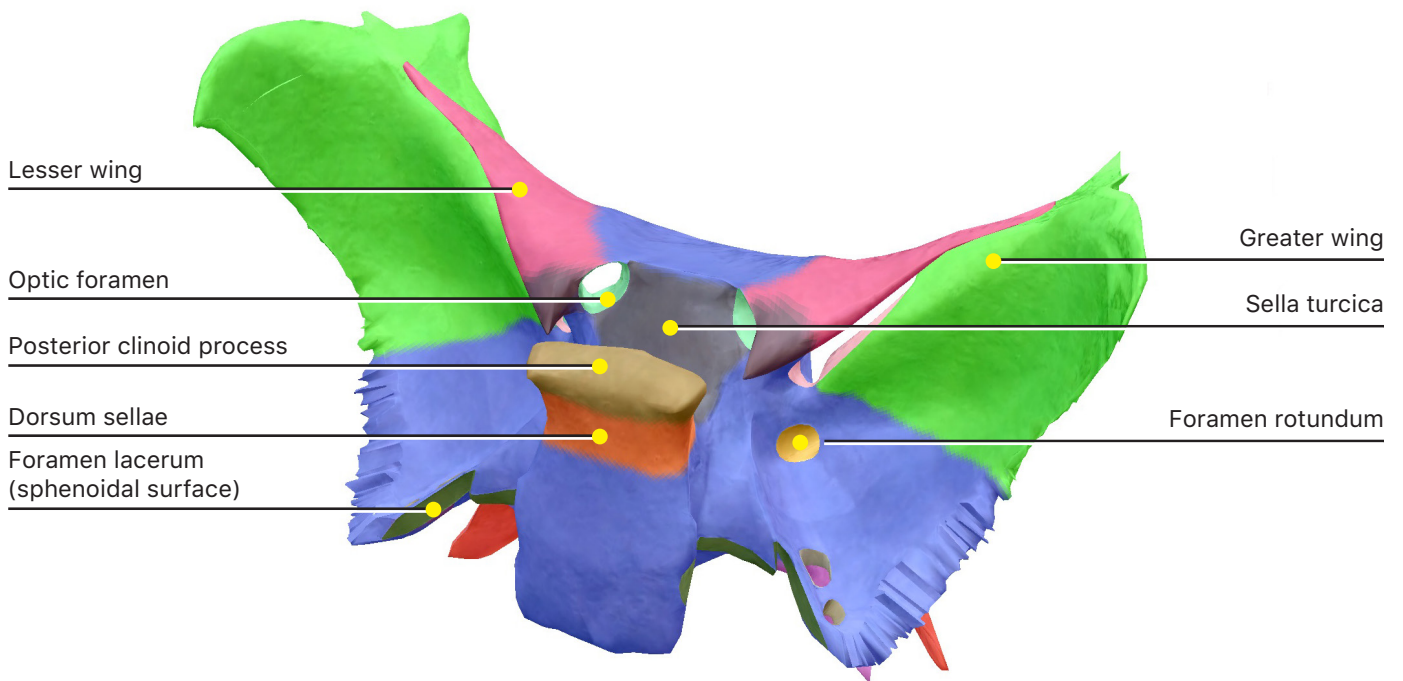
Module 10.6 Frontal Bone Landmarks



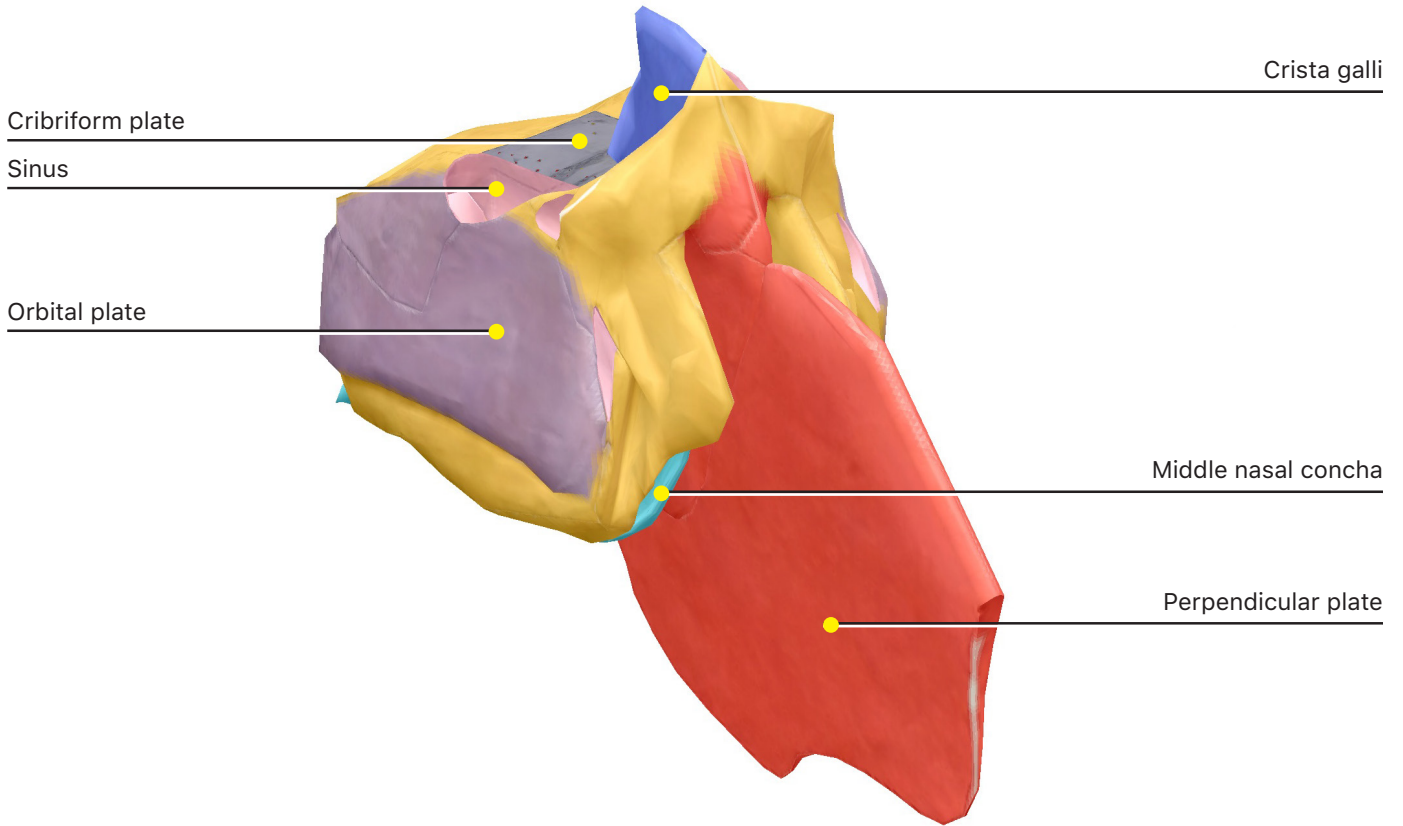
Module 10.7 Sphenoid Bone Landmarks (Part 1)



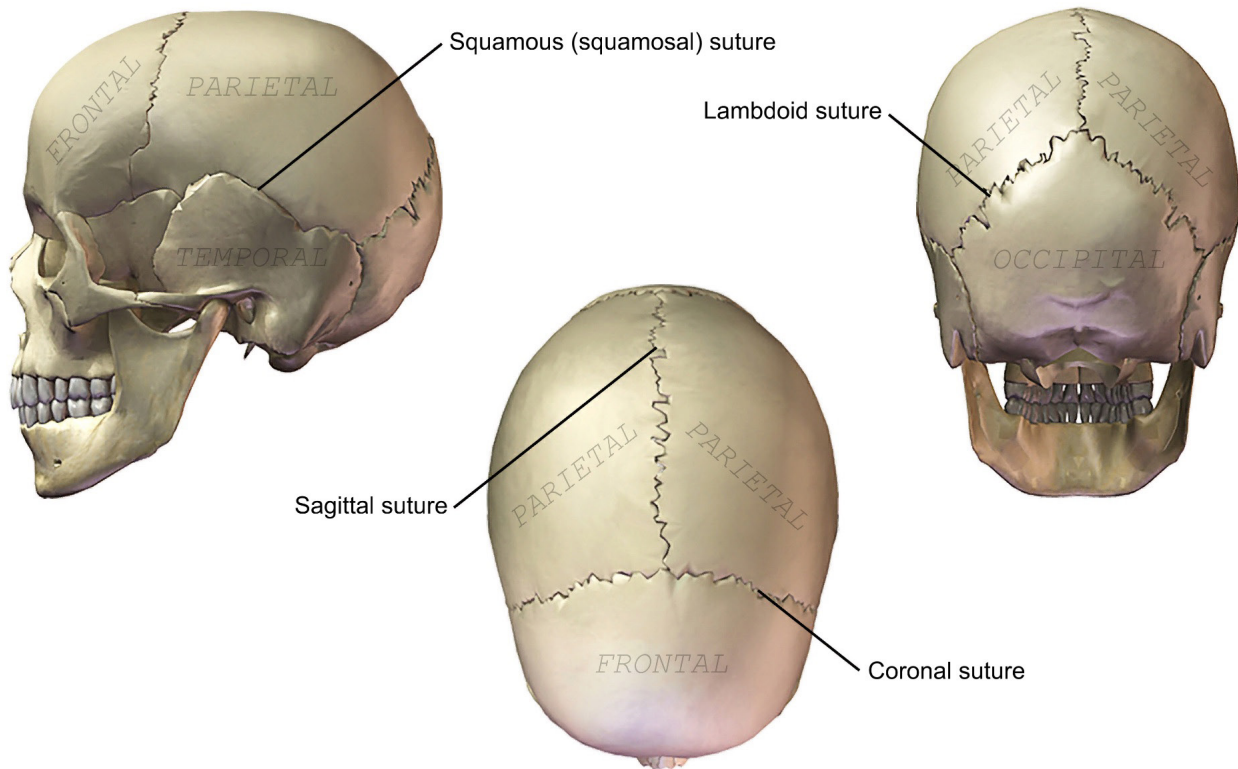
Module 10.7 Sphenoid Bone Landmarks (Part 2)



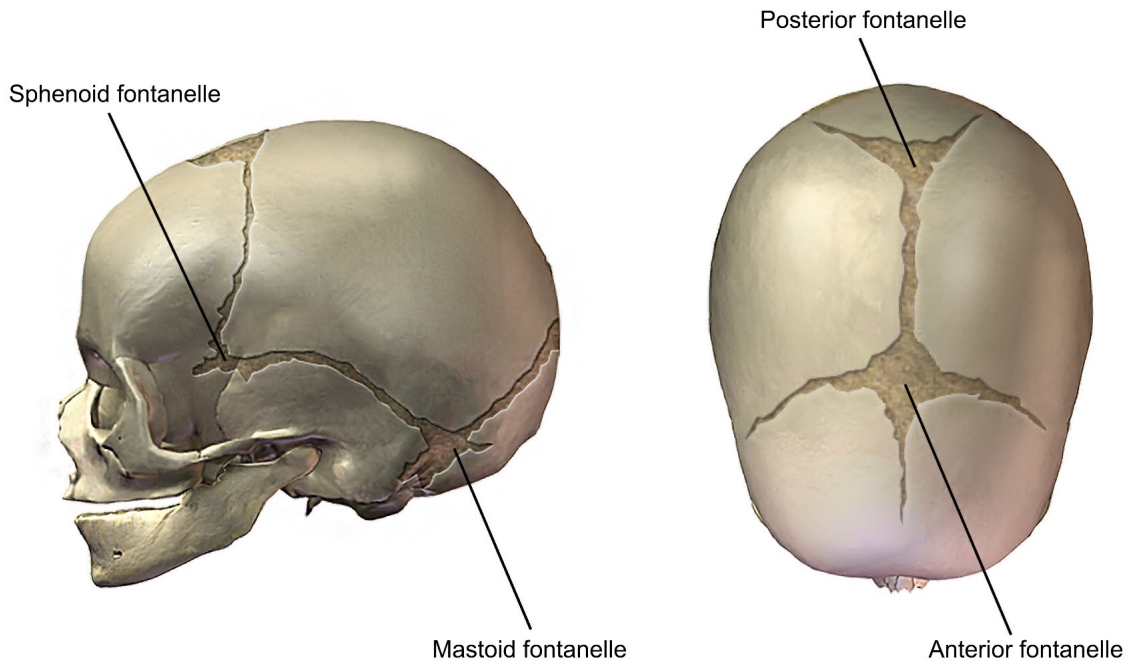
Module 10.8 Ethmoid Bone Landmarks



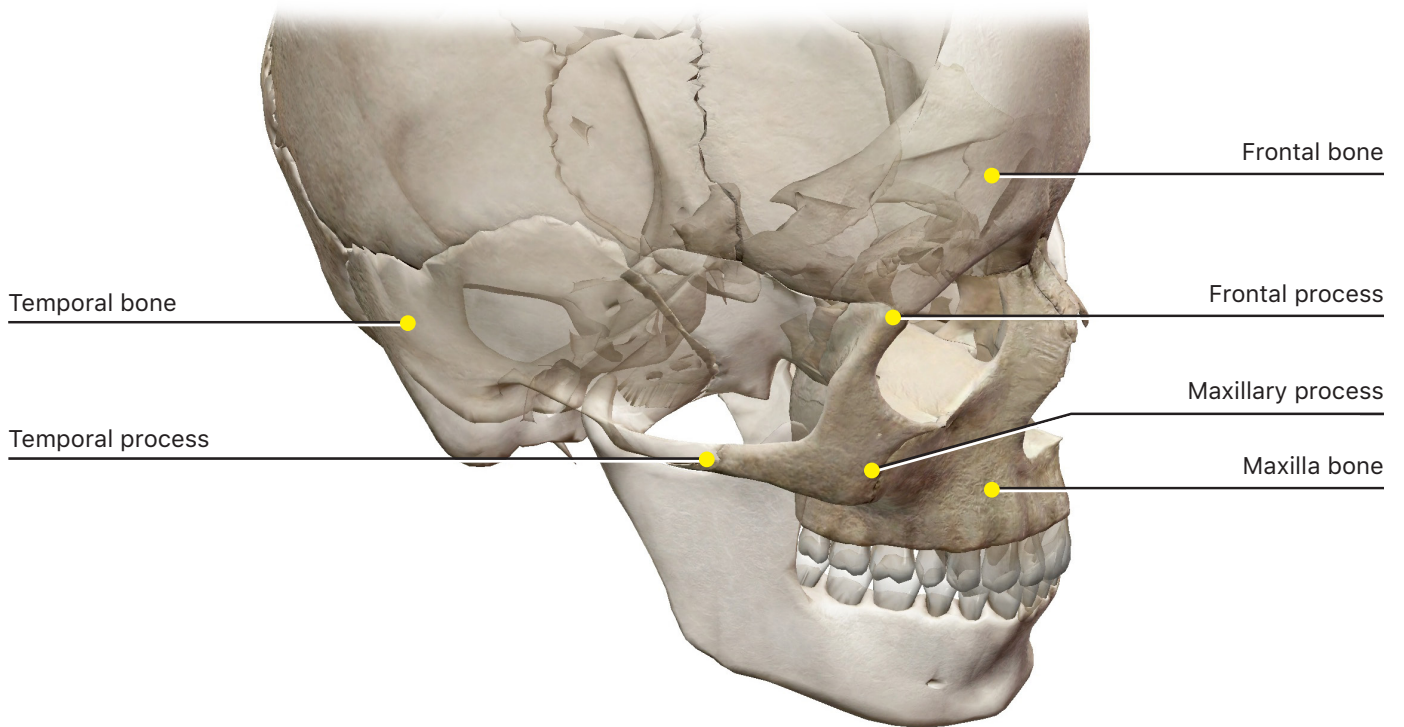
Module 10.9 Skull Sutures



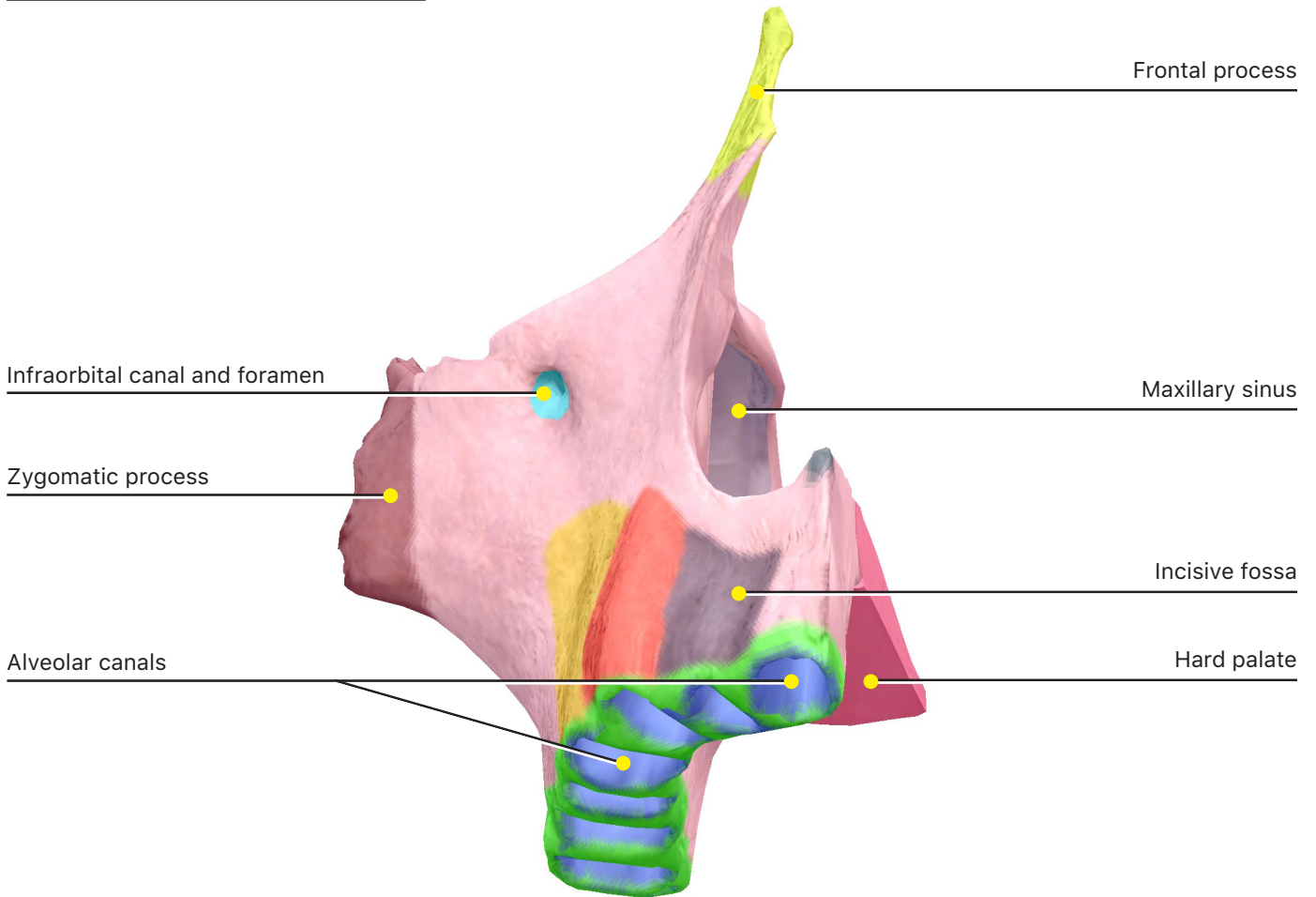
Module 10.10 Fontanelles



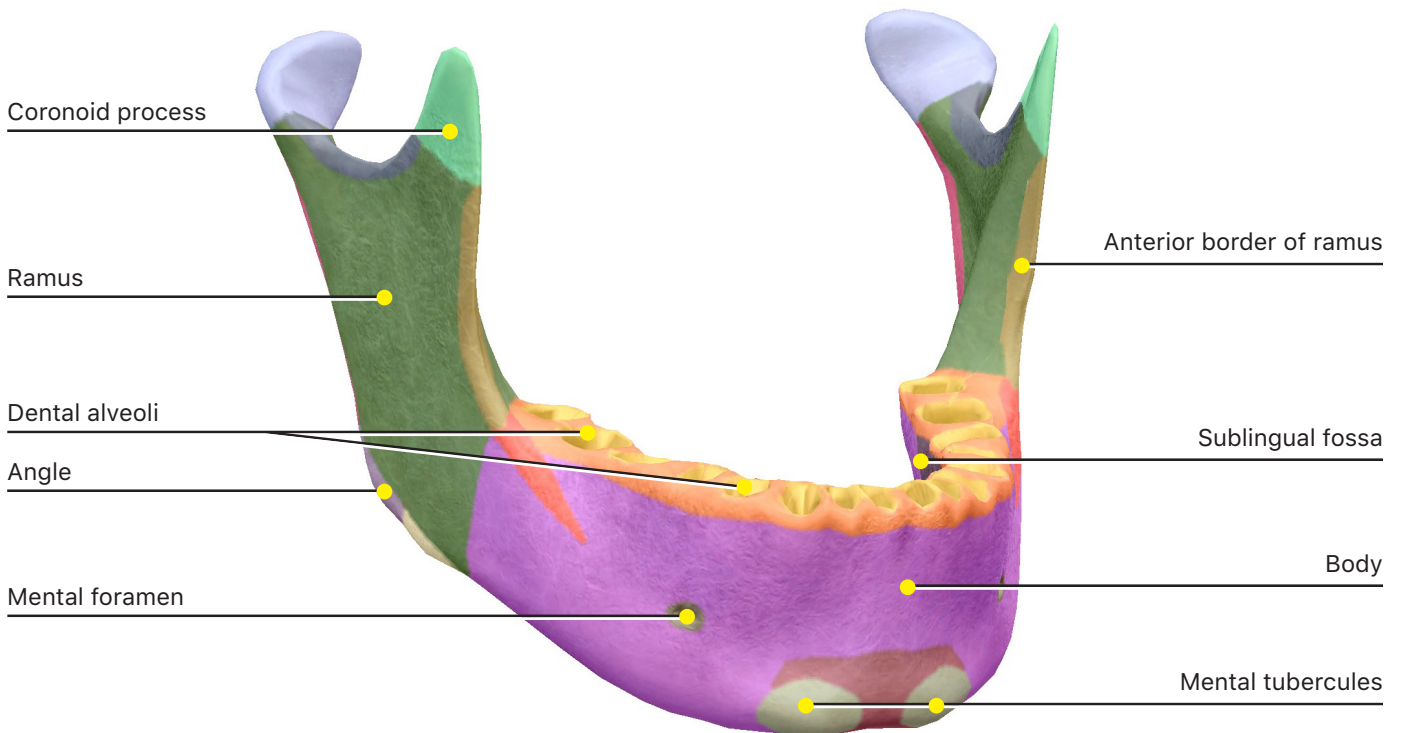
Module 10.11 Facial Skeleton I



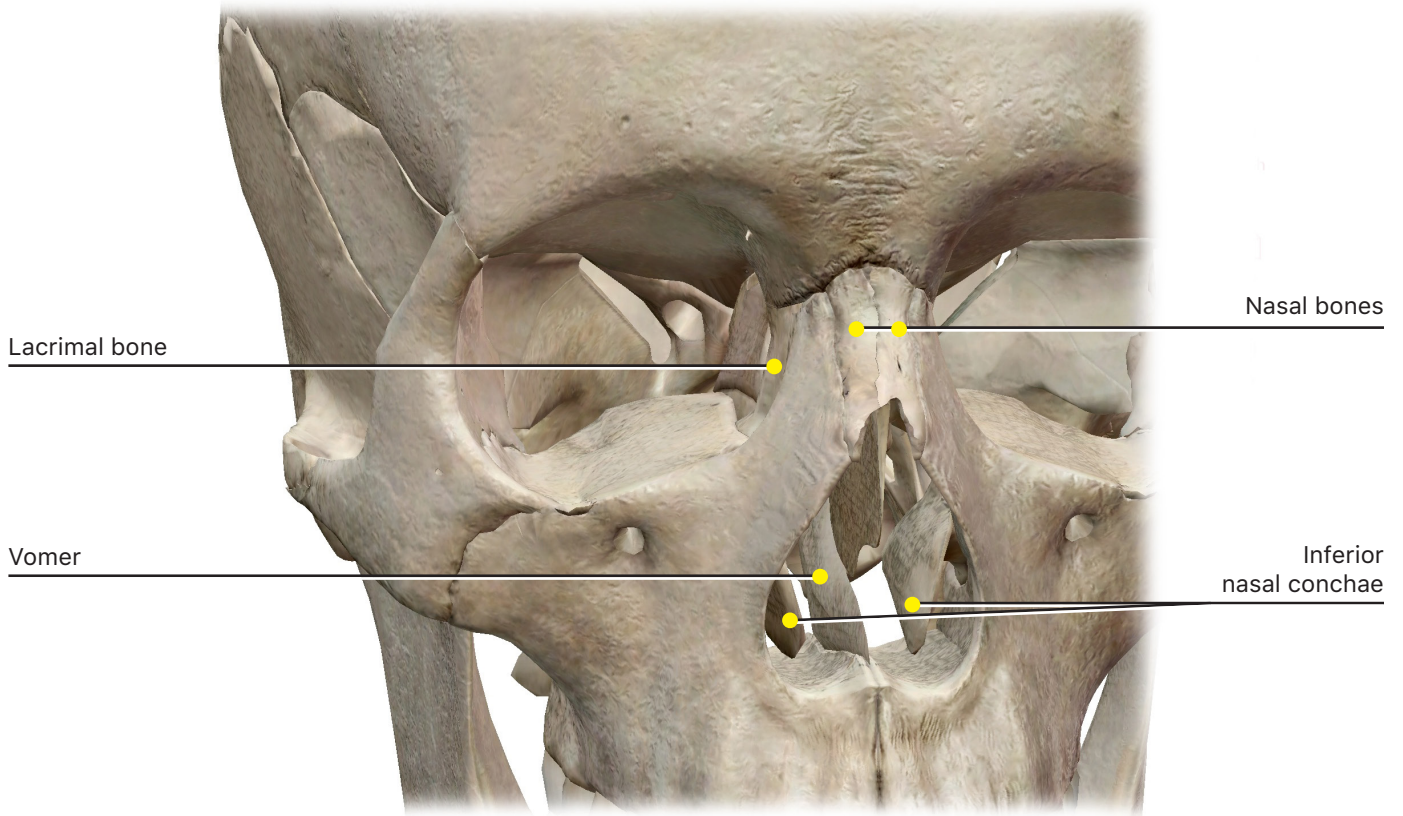
Module 10.12 Maxilla Landmarks



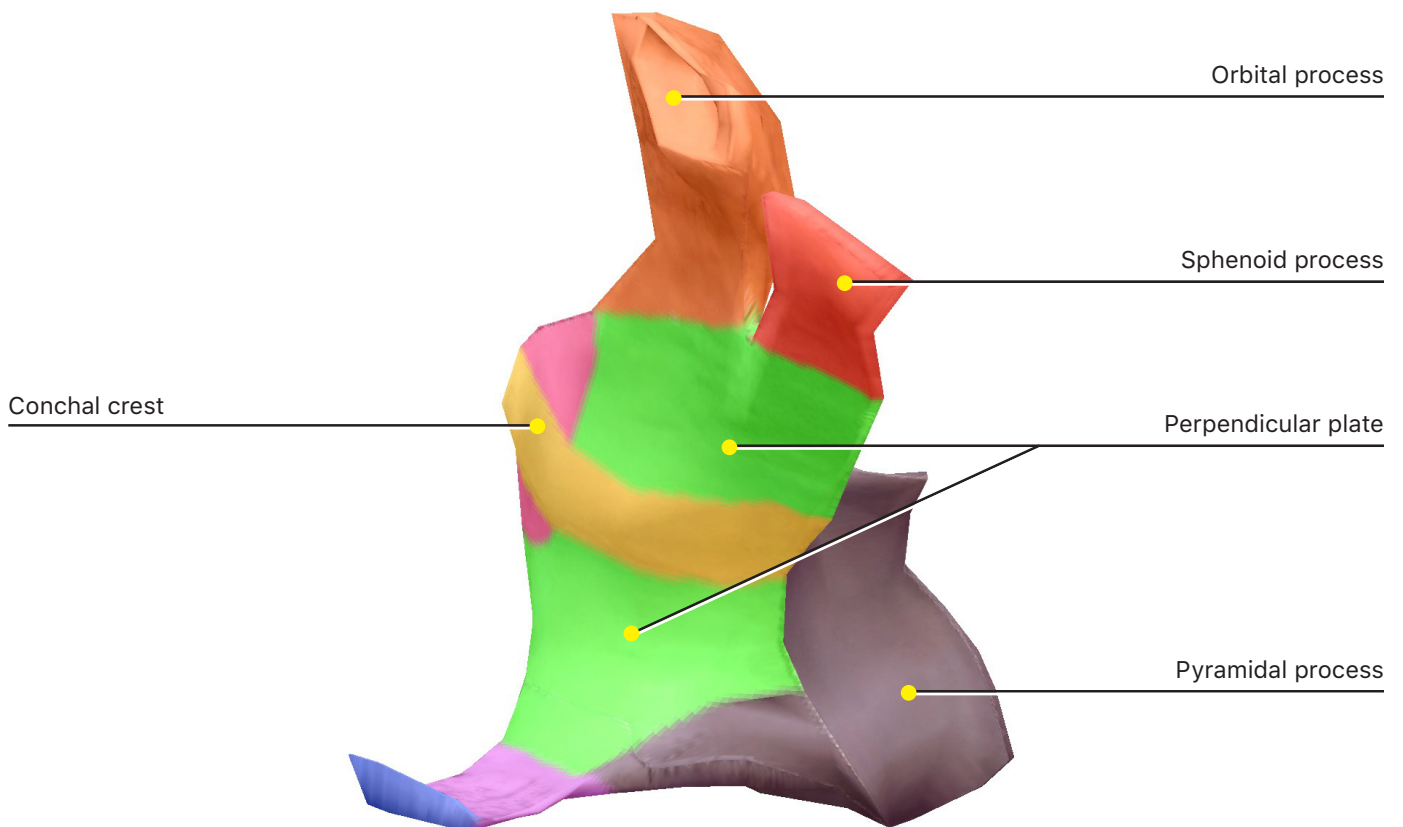
Module 10.13 Mandible Landmarks



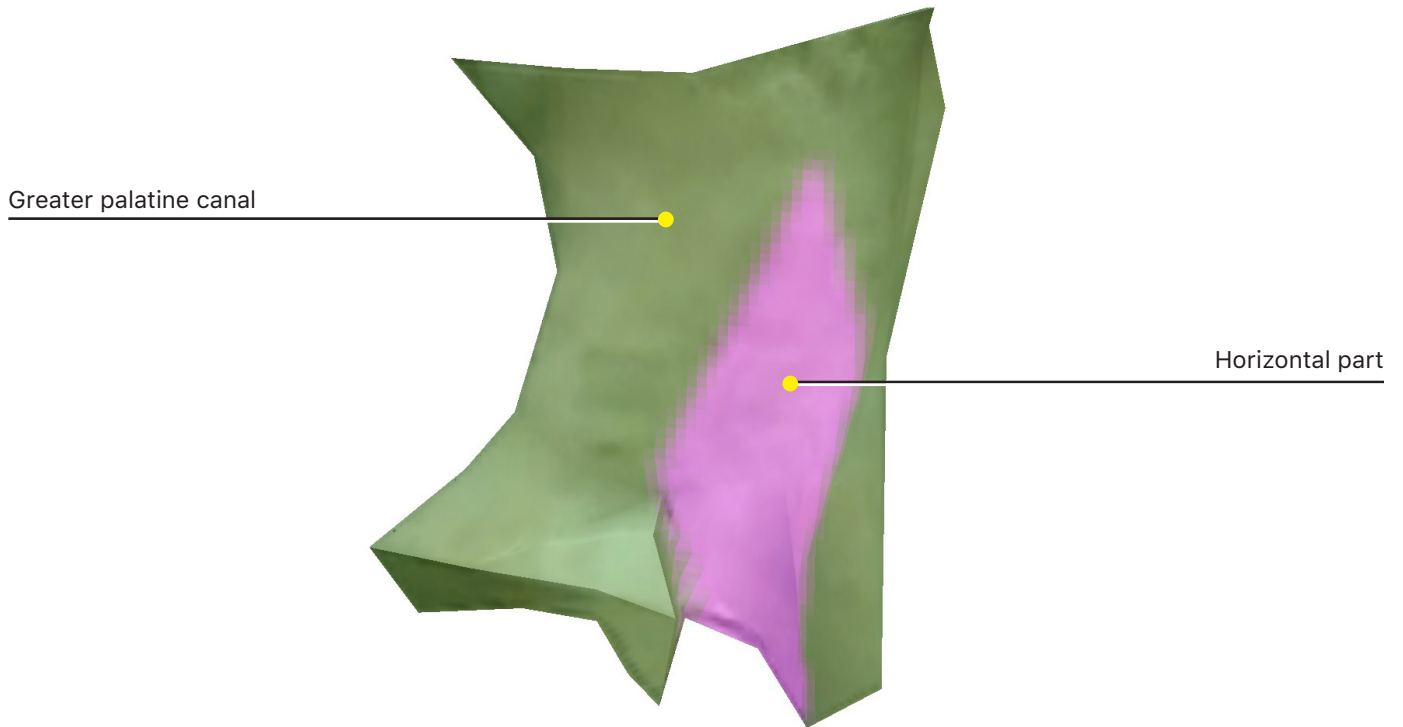
Module 10.14 Facial Skeleton II



Module 10.15 Palatine Bone Landmarks



Module 10.16 Lacrimal Bone Landmarks



1. Which bones compose the cranium?
2. Which bones are classified as facial bones?
3. Examine Module 10.4 Occipital Bone Landmarks to learn about the **occipital bone**.
 - a. Identify the following bone markings:
 - i. **Foramen magnum**
 - ii. **Hypoglossal canal**
 - iii. **Occipital condyles**
 - iv. **Condylod foramen**
 - v. **External occipital protuberance**
 - vi. **Inferior nuchal line**

- vii. **Superior nuchal line**
- viii. **Jugular foramen (occipital surface)**
- ix. **Foramen lacerum (occipital surface)**

b. What structure passes through the foramen magnum?

c. What structure is responsible for articulating with the vertebral column?

4. Examine Module 10.3 Cranial Bones to learn about the **parietal bones**.

5. Examine Module 10.5 Temporal Bone Landmarks to learn about the **temporal bones**.

a. Identify the following bone markings:

i. **Petrous part**

ii. **Zygomatic process** (note how the zygomatic process of the temporal bone is different from the zygomatic process of the frontal bone)

iii. **Mandibular fossa**

iv. **External auditory (acoustic) meatus**

v. **Internal auditory (acoustic) meatus** (turn the view around to the medial side of the bone to find this)

vi. **Styloid process**

vii. **Mastoid process**

viii. **Carotid canal**

ix. **Jugular foramen (temporal surface)**

x. **Foramen lacerum (temporal surface)**

b. Where does the lower jaw attach to the skull?

c. Where do sound waves enter the ear?

6. Examine Module 10.6 Frontal Bone Landmarks to learn about the frontal bone.

a. Identify the following bone markings:

i. **Supraorbital notch**

ii. **Supraorbital margin**

iii. **Glabella**

iv. **Zygomatic process** (note how the zygomatic process of the frontal bone is different from the zygomatic process of the temporal bone)

7. Examine Module 10.7 Sphenoid Bone Landmarks to learn about the **sphenoid bone**.

a. Identify the following bone markings:

i. **Greater wing**

ii. **Lesser wing**

iii. **Sella turcica**

iv. **Dorsum sellae** (on the ridge posterior to the sella turcica)

v. **Optic foramen**

vi. **Superior orbital fissure**

vii. **Inferior orbital fissure** (sphenoid surface)

viii. **Foramen rotundum**

ix. **Foramen ovale**

x. **Foramen spinosum**

xi. **Foramen lacerum (sphenoidal surface)**

xii. **Medial pterygoid plate**

xiii. **Lateral pterygoid plate**

b. The pituitary gland is nicknamed the “master gland” of the body because it secretes many hormones that have widespread effects in the body. Which part of the sphenoid bone houses it?

8. Examine Module 10.8 Ethmoid Bone Landmarks to learn about the **ethmoid bone**.

a. Identify the following bone markings:

- i. **Crista galli**
- ii. **Cribriform plate**
- iii. **Middle nasal concha**
- iv. **Superior nasal concha**
- v. **Perpendicular plate**

b. Olfactory nerves need to pass through which structure in order to detect odors in the nose?

9. Examine Modules 10.9 Skull Sutures and 10.10 Fontanelles to learn about **sutures** and **fontanelles**.

a. Sutures are immovable joints between bones that are connected by short fibers. Identify the following sutures found on the skull:

- i. **Coronal suture**
- ii. **Sagittal suture**
- iii. **Lambdoid suture**
- iv. **Squamous suture**

b. During fetal development, the skull bones initially form as plates with spaces between the bones, called fontanelles. Over time, these spaces will close completely to be replaced by sutures. Identify the following fontanelles found on the skull:

- i. **Anterior fontanelle**
- ii. **Posterior fontanelle**
- iii. **Sphenoid fontanelle**
- iv. **Mastoid fontanelle**

10. Examine Modules 10.11 Facial Skeleton I and 10.12 Maxilla Landmarks to learn about the **maxillae**.

a. Identify the following bone markings:

- i. **Alveolar canal**
- ii. **Alveolar process**
- iii. **Zygomatic process** (note how this is different from the zygomatic processes of the frontal and temporal bones, but all point toward the zygomatic bone)

- iv. **Frontal process**
- v. **Hard palate**
- vi. **Incisive fossa**
- vii. **Inferior orbital fissure (maxillary surface)**
- viii. **Infraorbital canal and foramen**
- ix. **Maxillary sinus**

b. What structures insert into the alveolar canal?

c. What structure forms the roof of the mouth?

11. Examine Modules 10.11 Facial Skeleton I and 10.13 Mandible Landmarks to learn about the **mandible**.

a. Identify the following bone markings:

- i. **Body**
- ii. **Ramus**
- iii. **Angle**
- vi. **Condyle**
- vii. **Dental alveoli**
- viii. **Mandibular foramen**
- ix. **Mental foramen**

b. Which part of the mandible attaches to the cranium? Where does it articulate?

12. Examine Module 10.11 Facial Skeleton I to learn about the **zygomatic bones**. The zygomatic bones are shaped roughly like triangles, with each vertex pointing toward a different bone: the temporal bone, maxilla, or frontal bone.

a. Identify the following bone markings:

- i. **Temporal process**

ii. **Maxillary process**

iii. **Frontal process**

13. Examine Modules 10.14 Facial Skeleton II and 10.15 Palatine Bone Landmarks to learn about the **palatine bones**.

14. Examine Modules 10.14 Facial Skeleton II and 10.16 Lacrimal Bone Landmarks to learn about the **lacrimal bones** and identify each **lacrimal fossa**.

15. Examine Module 10.14 Facial Skeleton II to learn about the **nasal bones, inferior nasal conchae bones**, and **vomer**.

B. Cavities of the Skull

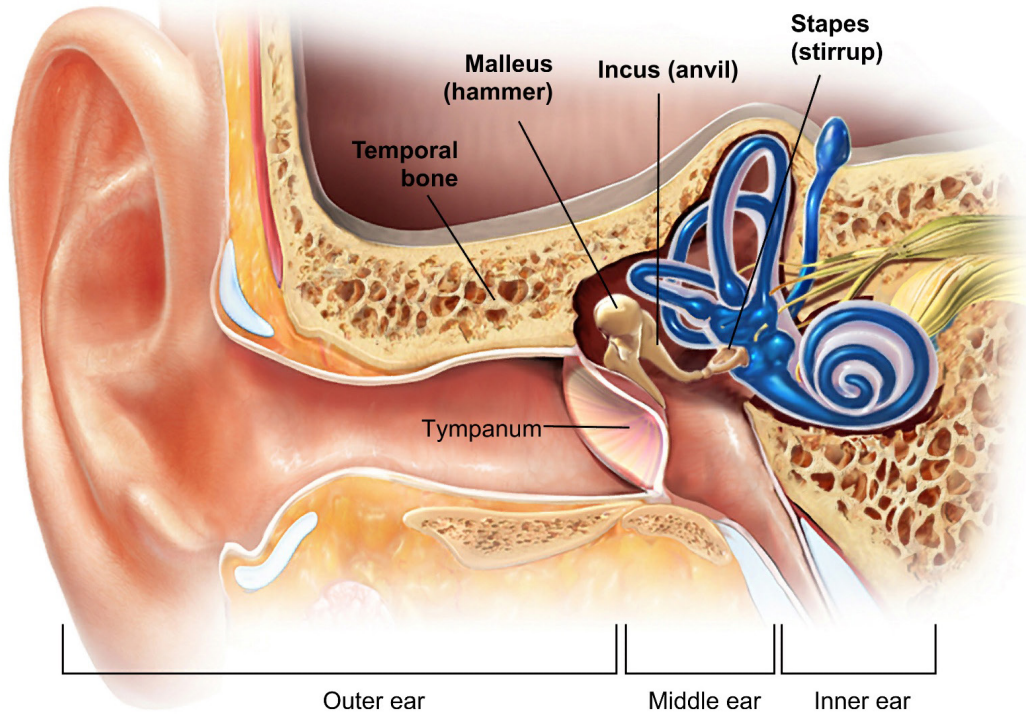
View Modules 10.19 Bones of the Orbit and 10.20 Nasal Septum and use them to answer the following questions.

1. Which bones compose the **orbit**?
2. Which bones and cartilages compose the **nasal septum**?
3. Which bones compose the **oral cavity**?
4. Which bones compose the **nasal cavity**?

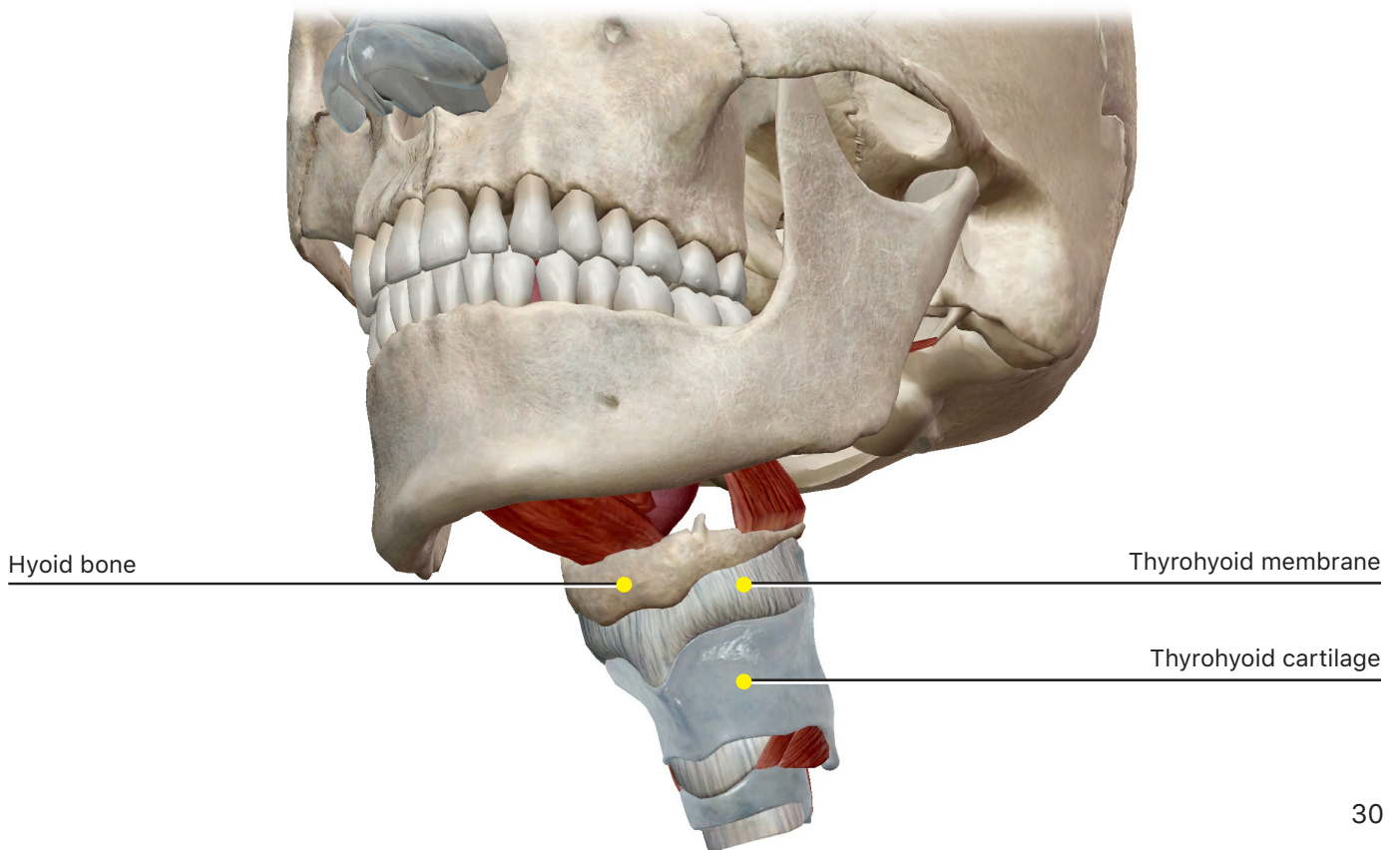
C. The Auditory Ossicles and Hyoid

View Modules 10.17 Auditory Ossicles and 10.21 Hyoid.

Module 10.17 Auditory Ossicles



Module 10.21 Hyoid



1. As the **auditory ossicles** vibrate, they conduct sound to your hearing receptors. Which bones comprise the auditory ossicles?

2. As sound waves come in through the external auditory meatus, which auditory ossicle would the sound waves arrive at first?

3. What is the function of the **hyoid** bone?

D. The Vertebral Column

The **vertebral column** consists of 24 vertebrae of different sizes and shapes. The primary function of the **vertebrae** is to protect the spinal cord. They are classified in groups based on their location. As you look at the different vertebrae, compare and contrast vertebrae from different regions in the body. Take note of the bone markings that are found in each type of vertebrae.

Students often confuse processes and facets that have the same name. Remember the definitions for these terms: **processes** are bony projections, while **facets** are flat surfaces.

After examining the following modules, identify the bone markings and answer the questions.

10.22 Vertebral Column

10.23 Vertebra

10.26 Cervical Spine

10.27 Cervical Spine Landmarks

10.28 Thoracic Spine

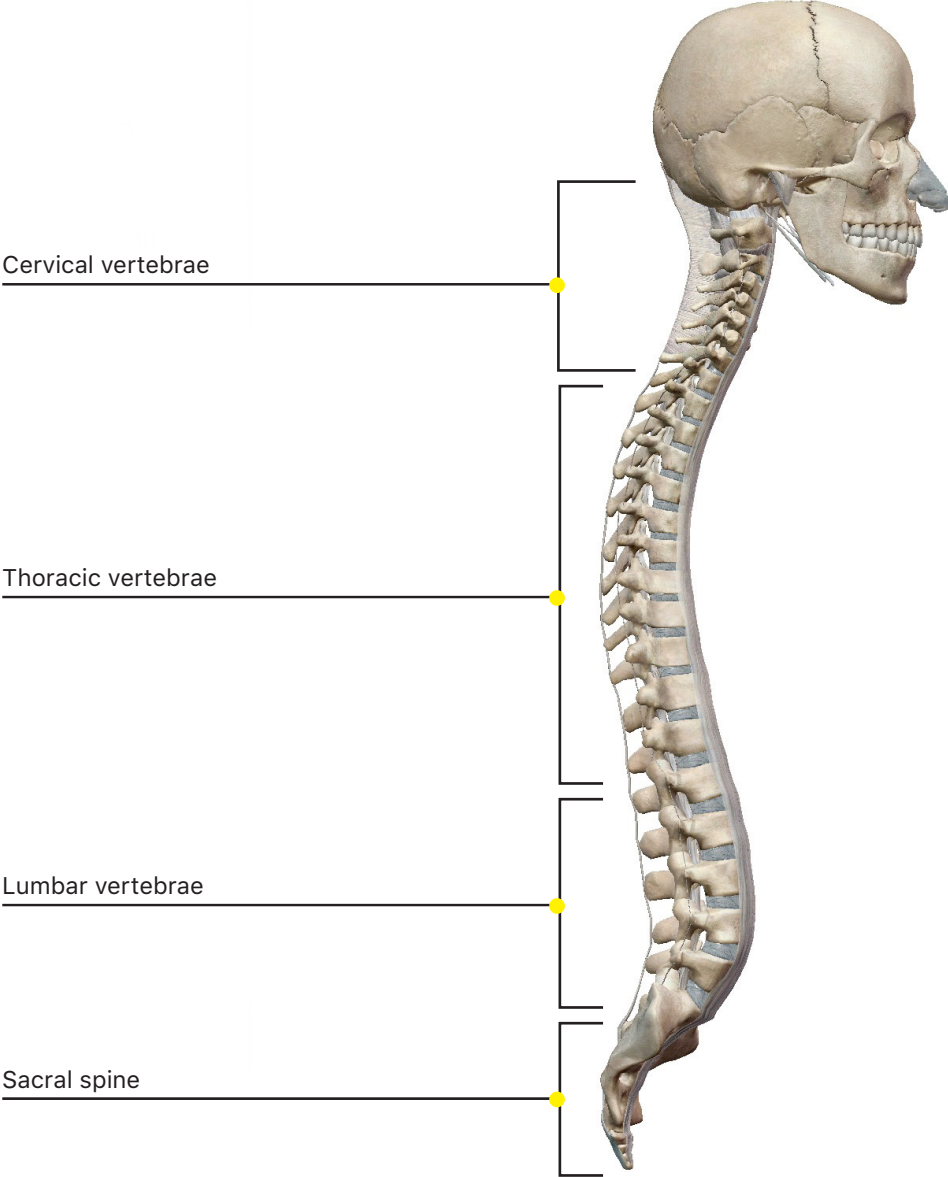
10.29 Thoracic Spine Landmarks

10.30 Lumbar Spine

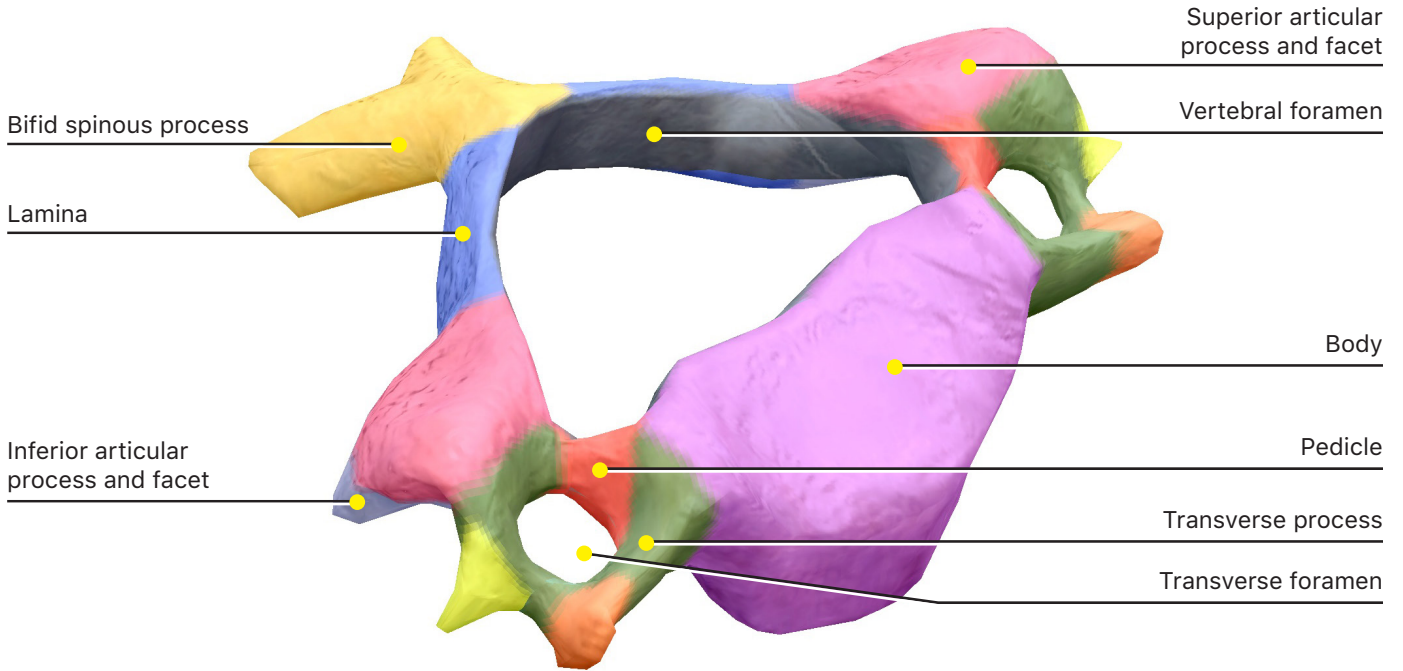
10.31 Lumbar Spine Landmarks

10.32 Sacral Spine

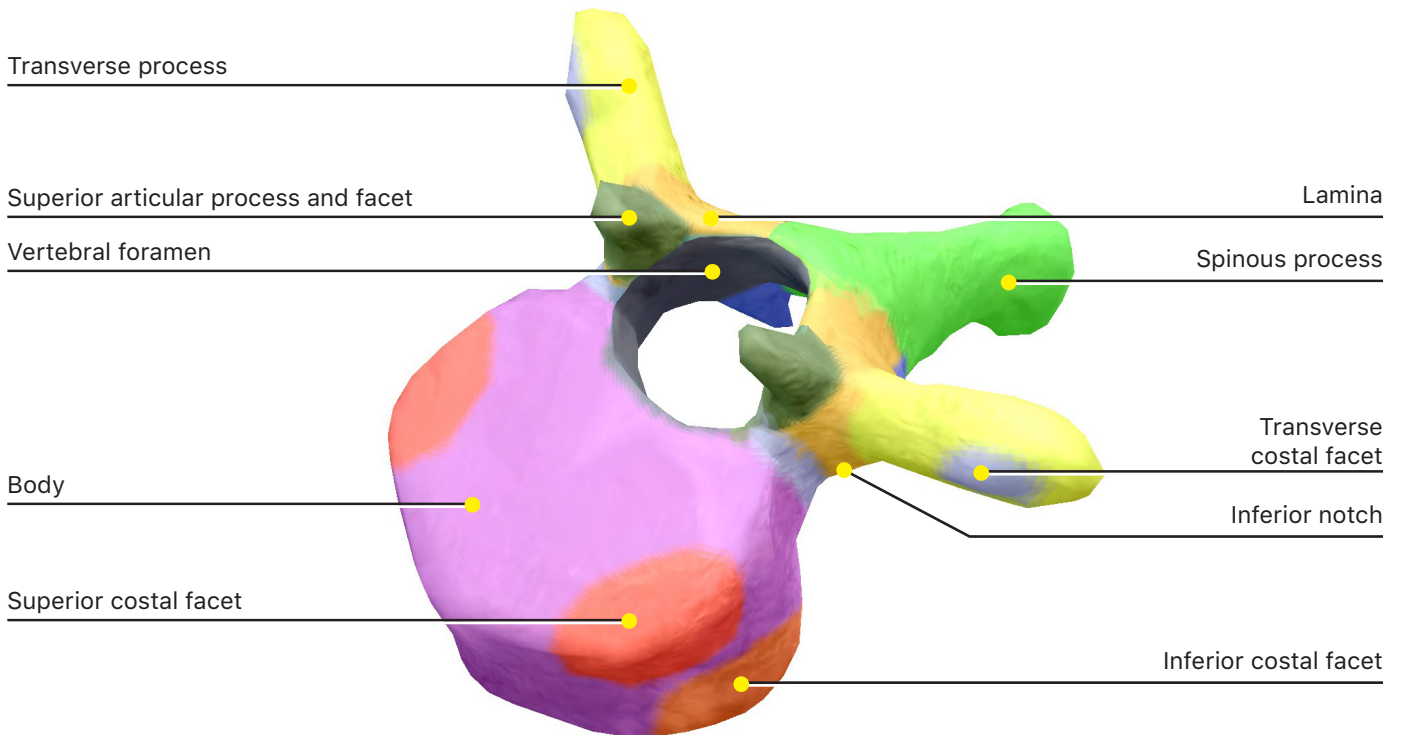
Module 10.22 Vertebral Column



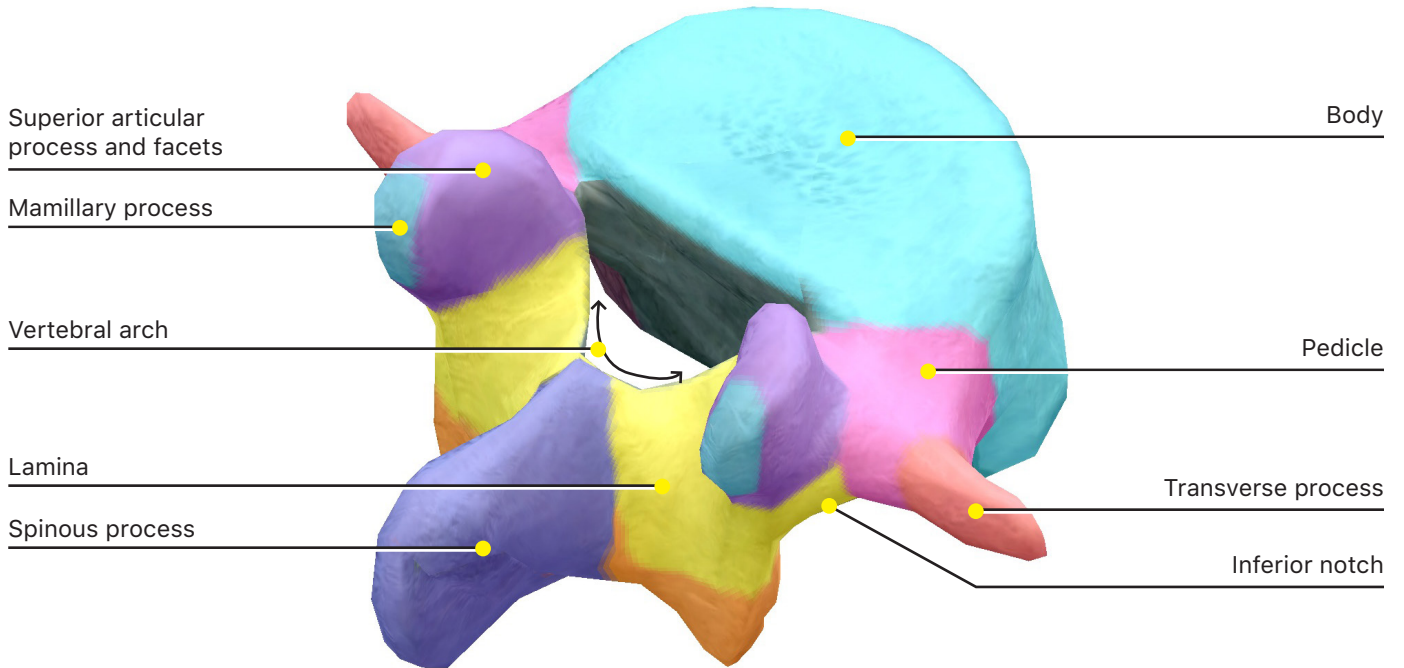
Module 10.27 Cervical Spine Landmarks



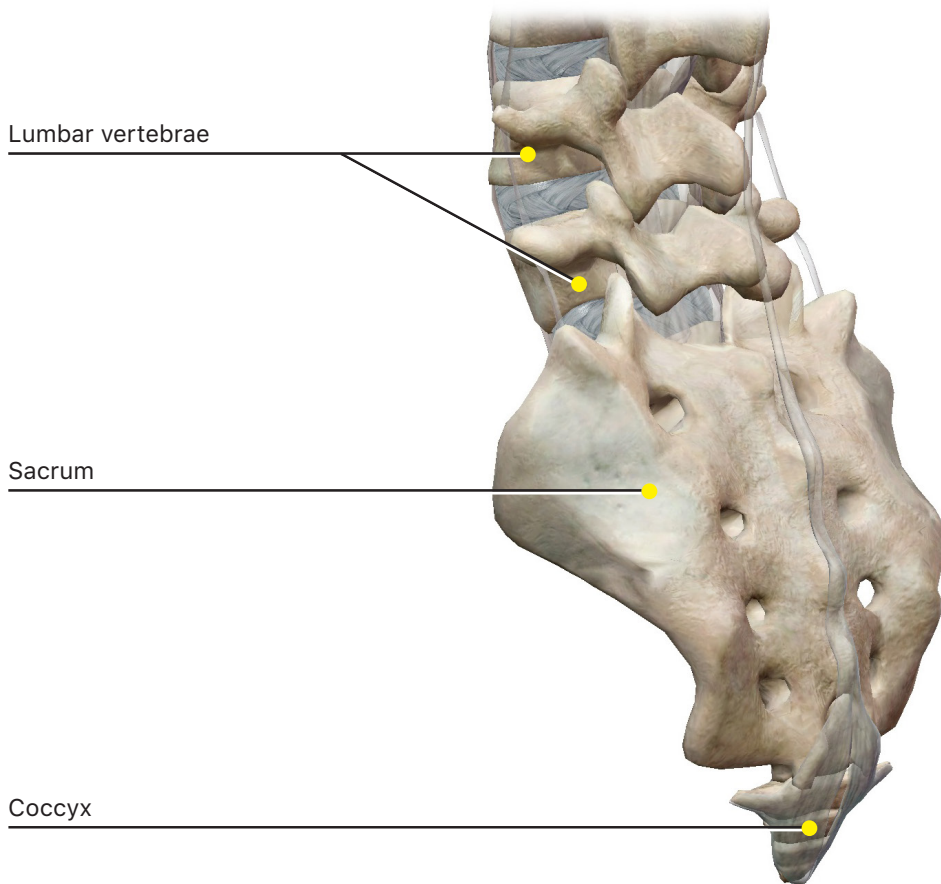
Module 10.29 Thoracic Spine Landmarks



Module 10.31 Lumbar Spine Landmarks



Module 10.32 Sacral Spine



1. **Cervical vertebrae** are in the neck area, **thoracic vertebrae** are in the chest area on the back of the ribs, and **lumbar vertebrae** are in the small of the back. Identify the bone markings found in these different types of vertebrae. While all vertebrae share common characteristics, there are also markings that distinguish them from each other. Pay attention to these distinguishing characteristics so you can tell the difference between cervical, thoracic, and lumbar vertebrae just by looking at them.

a. Examine Modules 10.26 Cervical Spine and 10.27 Cervical Spine Landmarks to learn about the cervical vertebrae. Identify the **atlas (C1)** and **axis (C2)**, as well as the following bone markings:

- i. **Body**
- ii. **Vertebral arch**
- iii. **Pedicle**
- iv. **Lamina**
- v. **Inferior notch**
- vi. **Transverse process**
- vii. **Superior articular process and facet**
- viii. **Inferior articular process and facet**
- ix. **Bifid spinous process**
- x. **Transverse foramen**
- xi. **Vertebral foramen**

b. Examine Modules 10.28 Thoracic Spine and 10.29 Thoracic Spine Landmarks to learn about the thoracic vertebrae. Identify the following bone markings:

- i. **Body**
- ii. **Vertebral arch**
- iii. **Pedicle**
- v. **Vertebral foramen**
- vi. **Inferior notch**
- vii. **Spinous process**
- viii. **Transverse process**
- ix. **Transverse costal facet**
- x. **Superior costal facet**
- xi. **Inferior costal facet**

xii. **Superior articular process and facet**

xiii. **Inferior articular process and facet**

c. Examine Modules 10.30 Lumbar Spine and 10.31 Lumbar Spine Landmarks to learn about the lumbar vertebrae. Identify the following bone markings:

i. **Body**

ii. **Vertebral arch**

iii. **Pedicle**

iv. **Lamina**

v. **Vertebral foramen**

vi. **Spinous process**

vii. **Transverse process**

viii. **Superior articular process and facet**

ix. **Inferior articular process and facet**

x. **Inferior notch**

d. How many cervical, thoracic, and lumbar vertebrae are there?

e. Which bone markings enclose the spinal cord?

f. What is the function of the costal facets of the thoracic vertebrae?

g. What is the significance of the size of the body in lumbar vertebrae?

h. What are the distinguishing characteristics of cervical vertebrae?

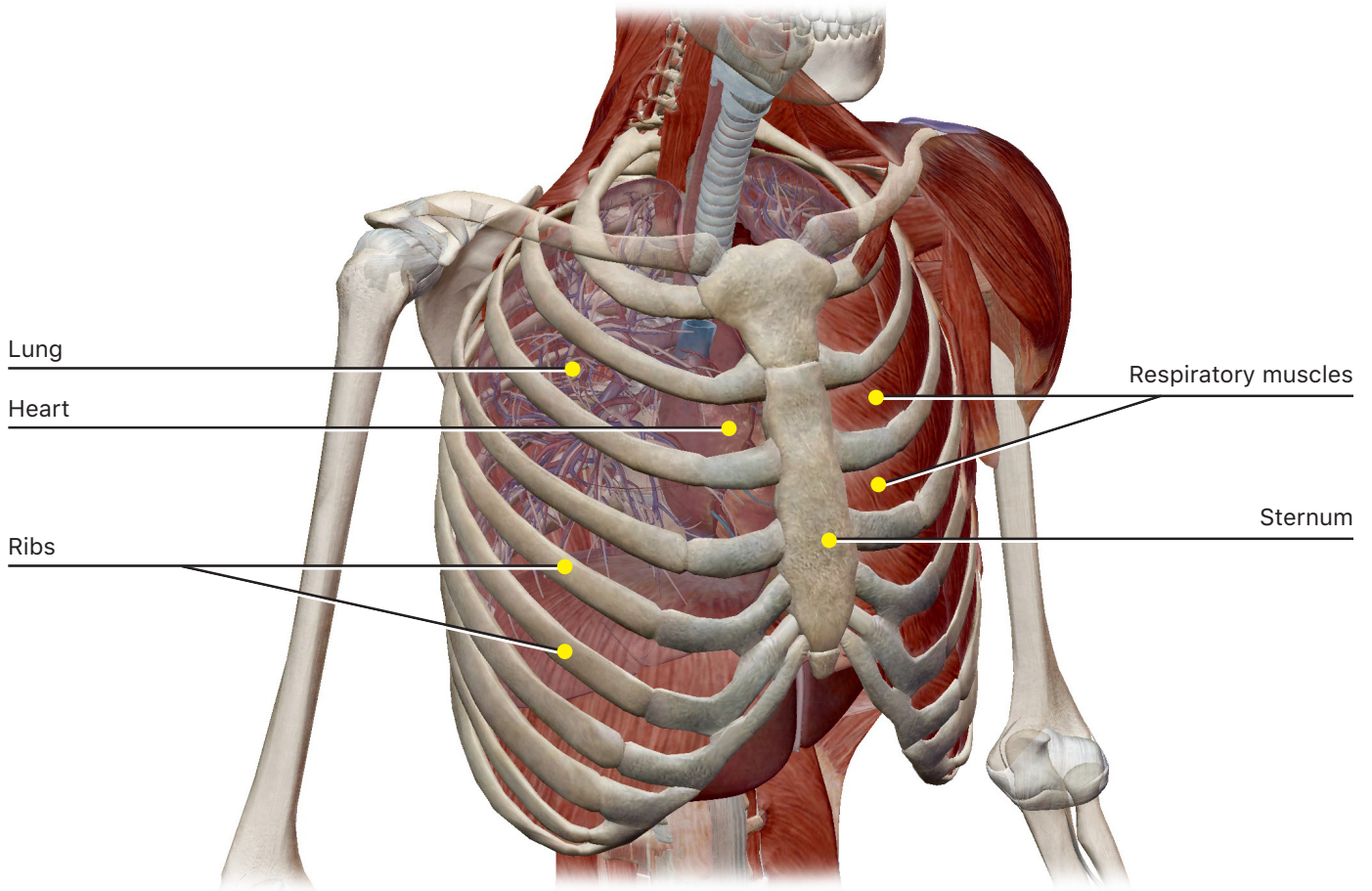
2. Examine Module 10.32 Sacral Spine to learn about the **sacrum** and **coccyx**, which are found in the pelvis in the inferior part of the vertebral column.

E. Thoracic Cage

The **thoracic cage** protects important underlying organs, such as the heart and lungs. The bones also serve as attachment points for respiratory muscles.

View Modules 10.33 Thoracic Cage, 10.34 Sternum, and 10.35 Ribs and answer the following questions.

Module 10.33 Thoracic Cage

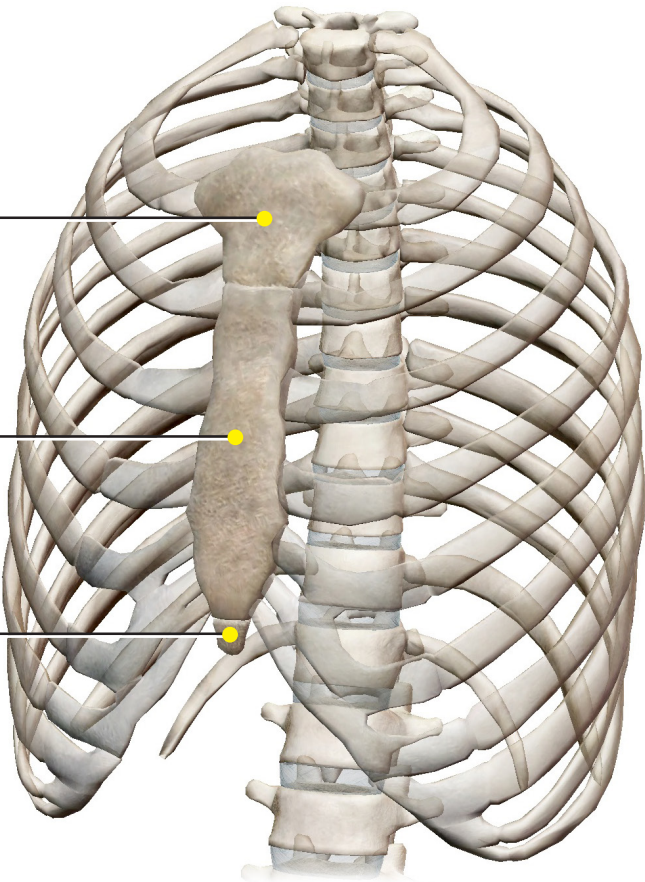


Module 10.34 Sternum

Manubrium

Body of sternum

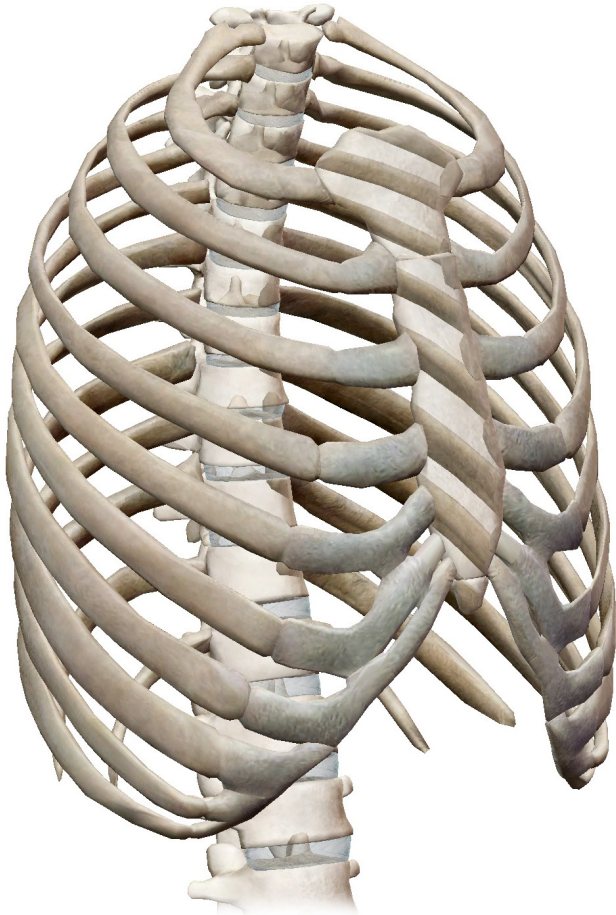Xiphoid process



Module 10.35 Ribs

True ribs (1-7)

False ribs (8-12)



1. Identify the following parts of the **sternum**:

- a. **Manubrium**
- b. **Body of the sternum**
- c. **Xiphoid process**

2. Identify the **ribs**

- a. Which ribs are **true ribs**? Why are they classified as true ribs?

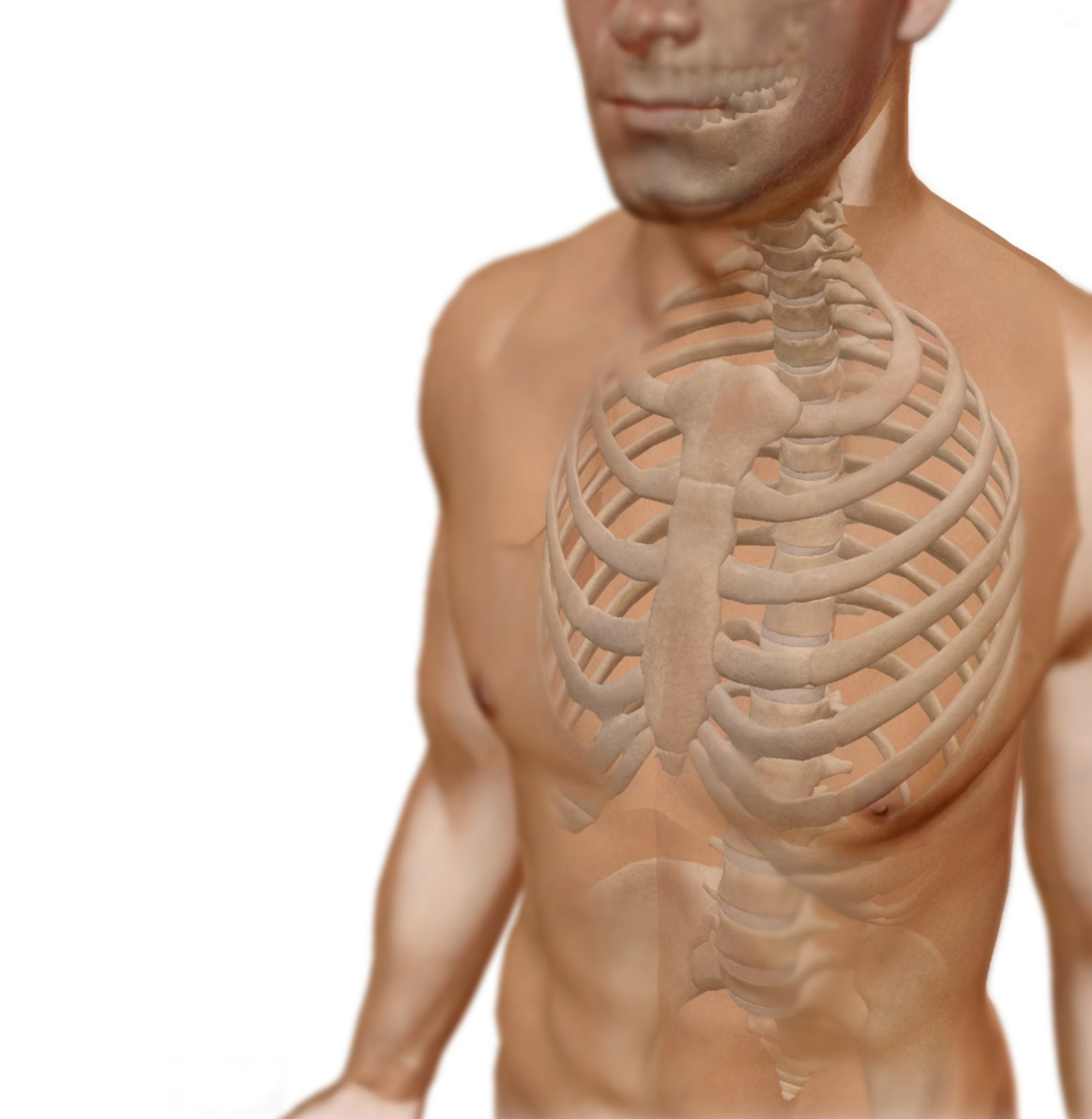
- b. Which ribs are **false ribs**? Why are these classified as false ribs?

PUTTING IT ALL TOGETHER

1. What kinds of treatments would be effective for osteoporosis?
2. What is the purpose of fontanelles?
3. You identified the hard palate of the maxilla. Why was the soft palate not included in this exercise?
4. Where would be a good place for a lidocaine injection prior to dental work? You would want easy access to a blood vessel in the jaw.
5. If you have high cheekbones, to which bones does this refer?
6. Imagine that you are working as a medical examiner and a new body is brought in. The body appears to be healthy, except for a broken hyoid bone. What do you suspect is the cause of death?
7. Why does the thoracic cage need to be slightly flexible?
8. What are the four different places where ribs attach?

TIME TO PRACTICE!

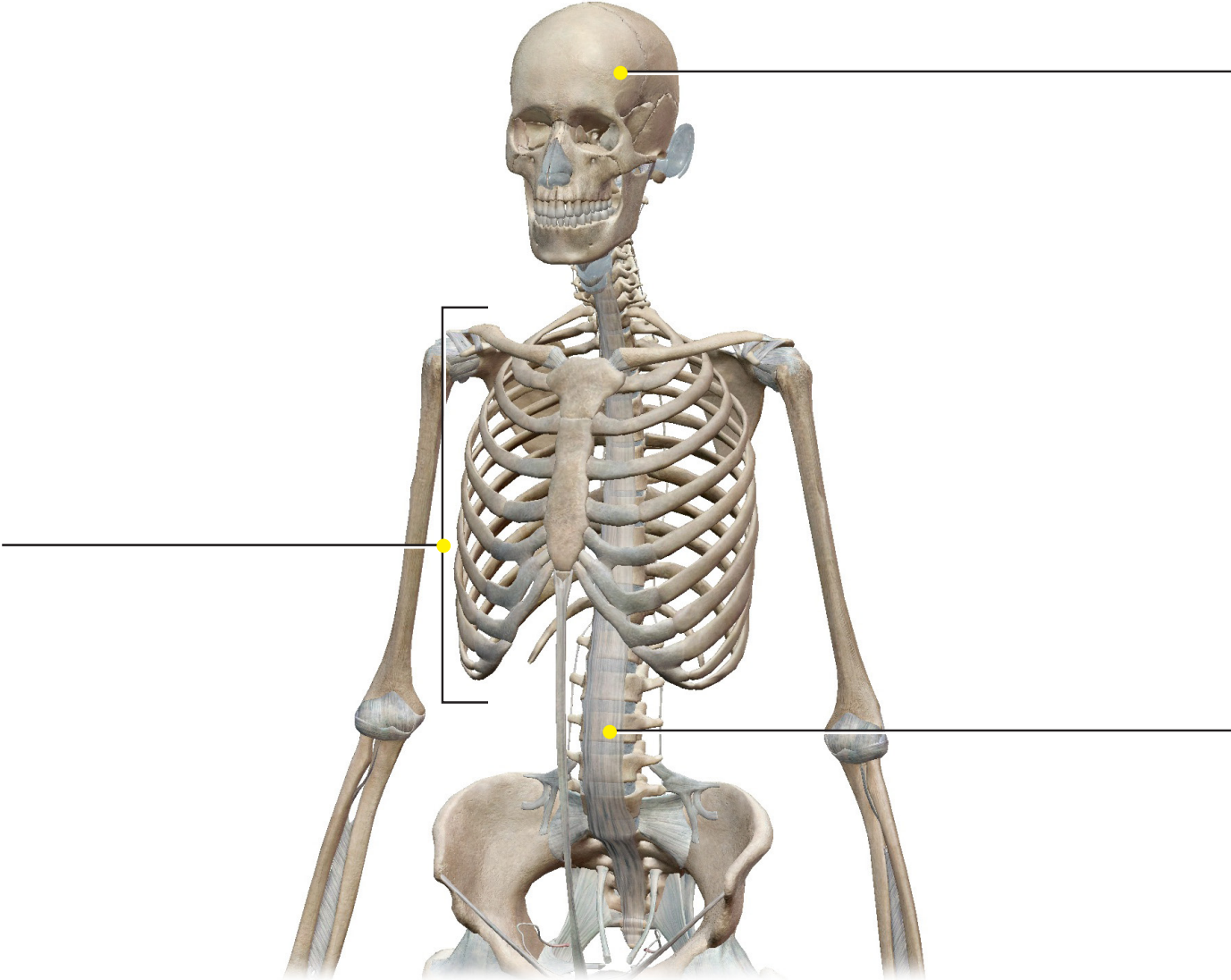
[GO TO THE QUIZZES MENU AND COMPLETE SKELETAL SYSTEM QUIZZES 8.A, 9.A, 10.A, AND 10.B.](#)



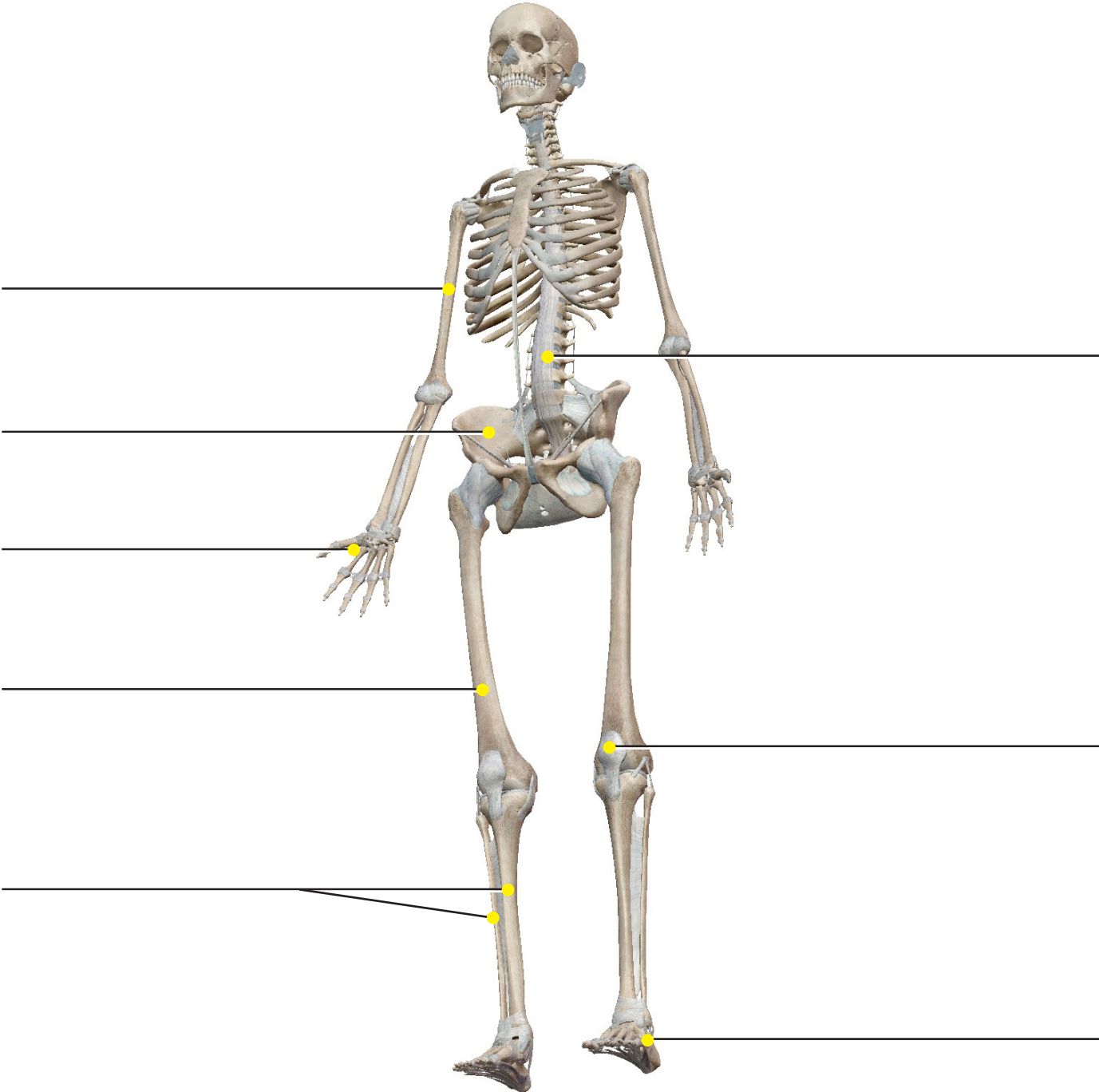
Student Practice

Label all the structures on the following images.

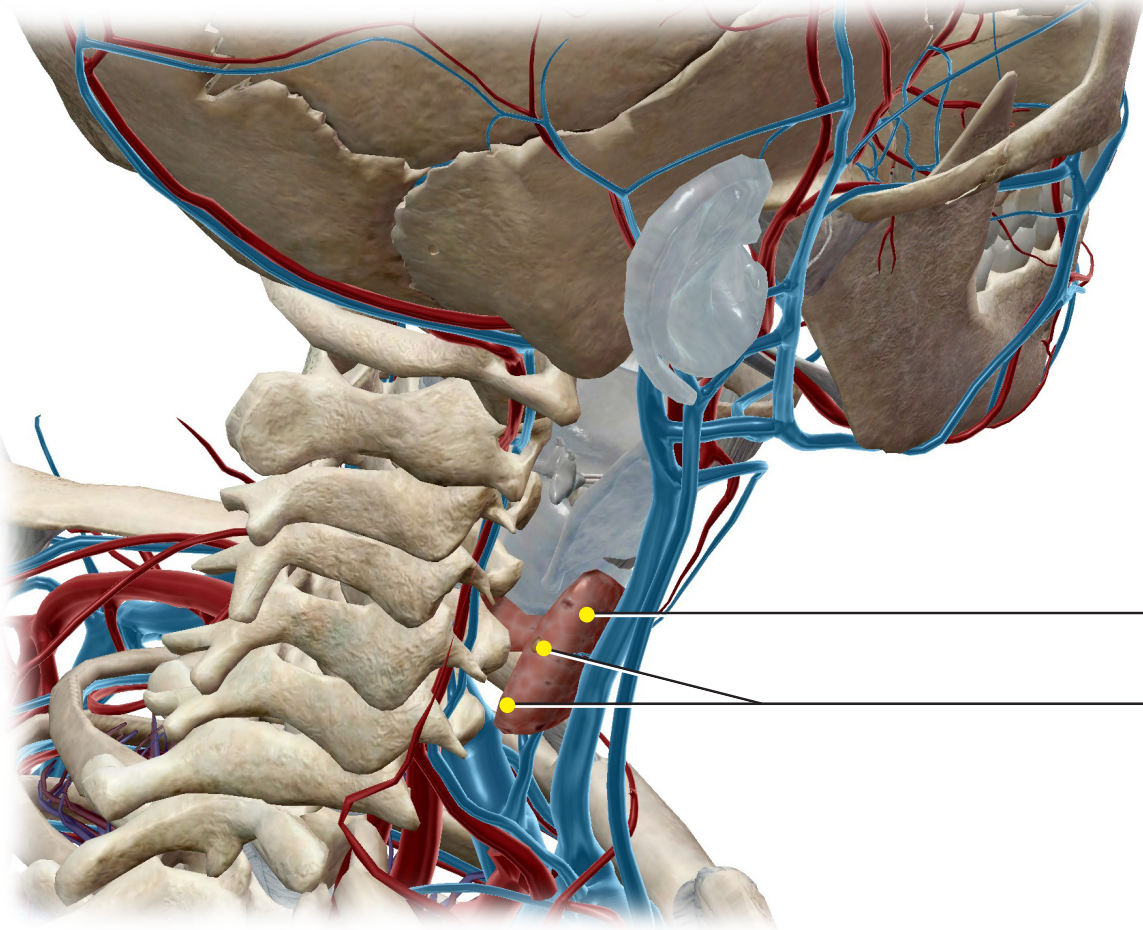
Module 7.2 Axial and Appendicular Skeleton



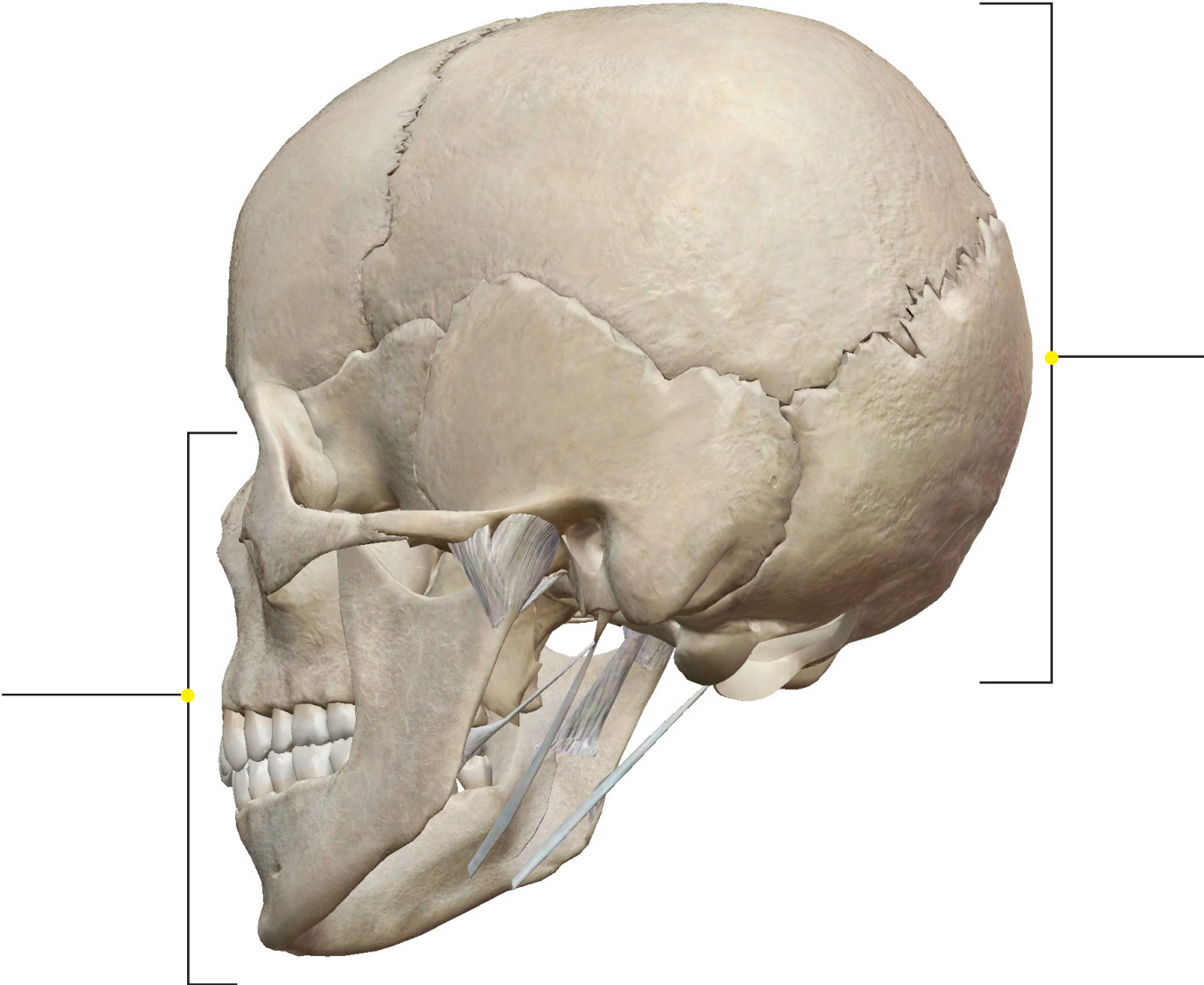
Module 8.1 Bone Types



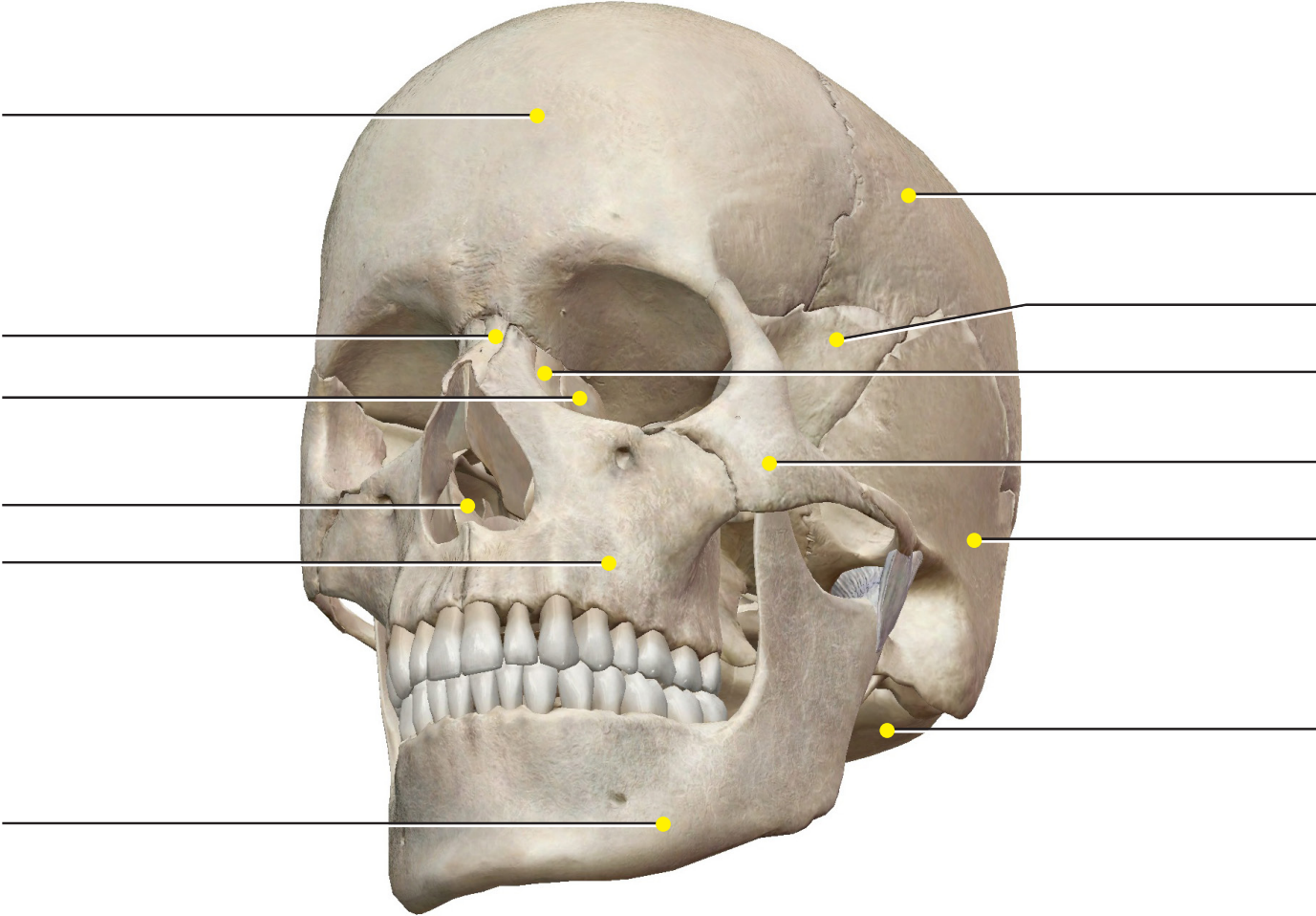
Module 9.13 Calcium in the Skeleton



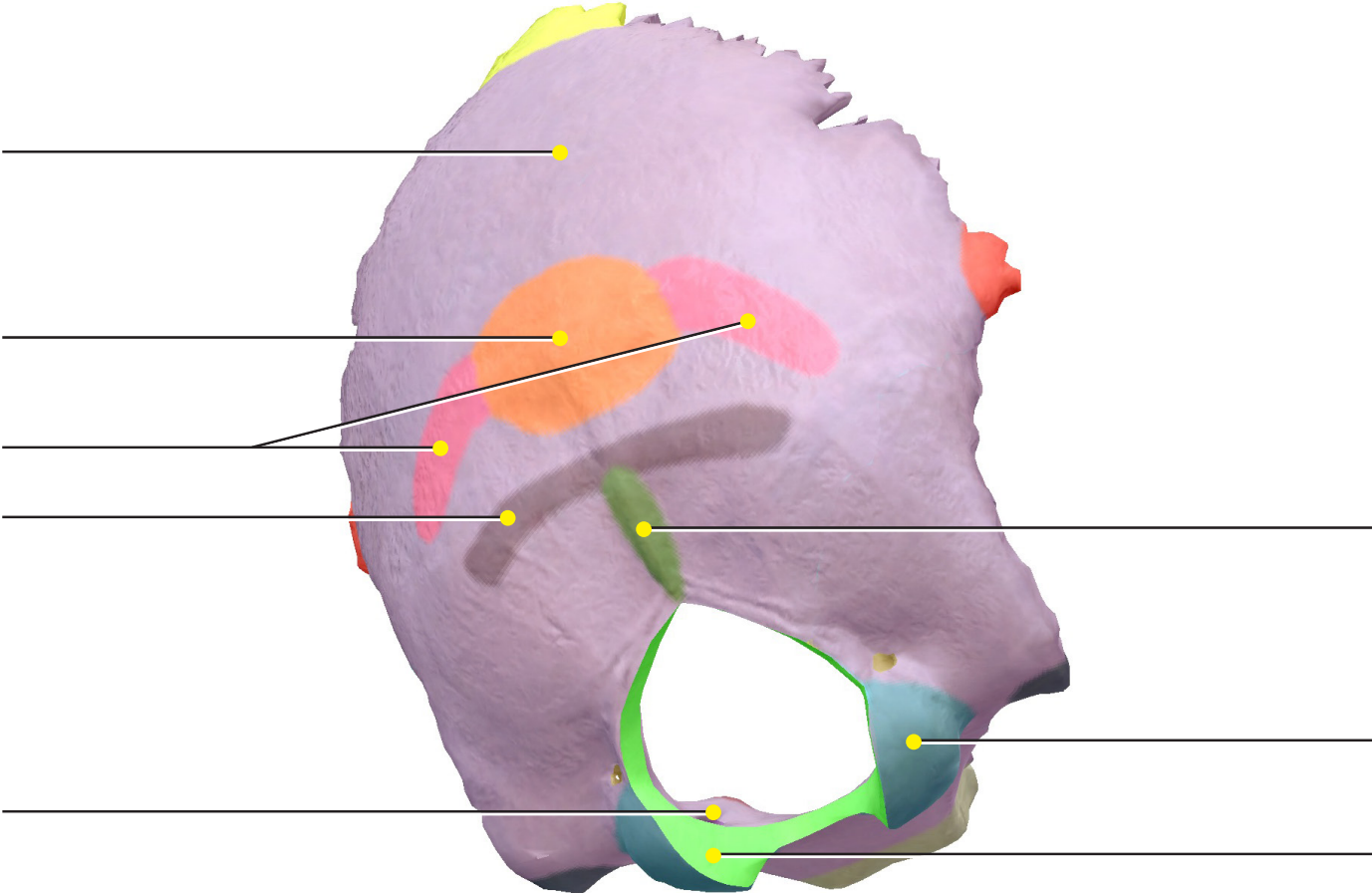
Module 10.2 Skull (Part 1)



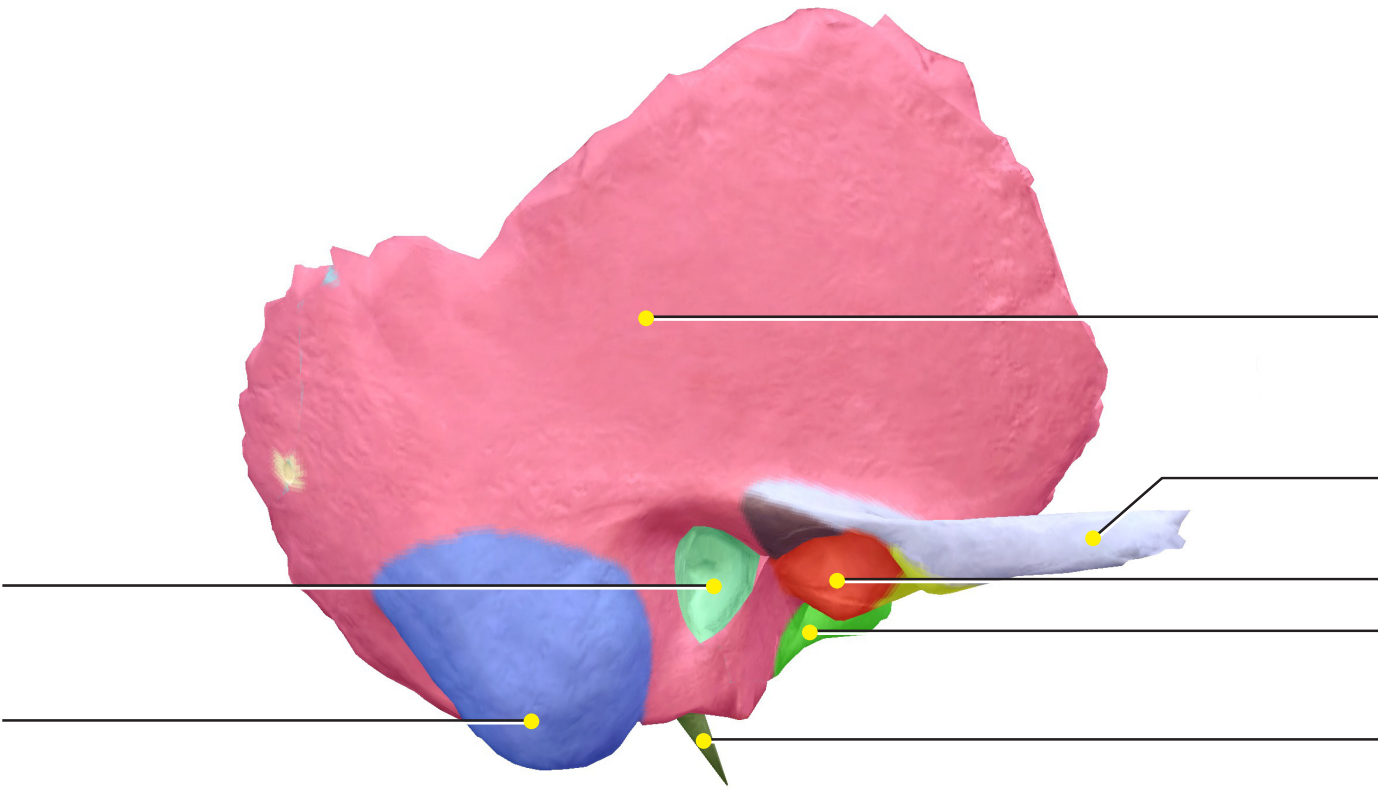
Module 10.2 Skull (Part 2)



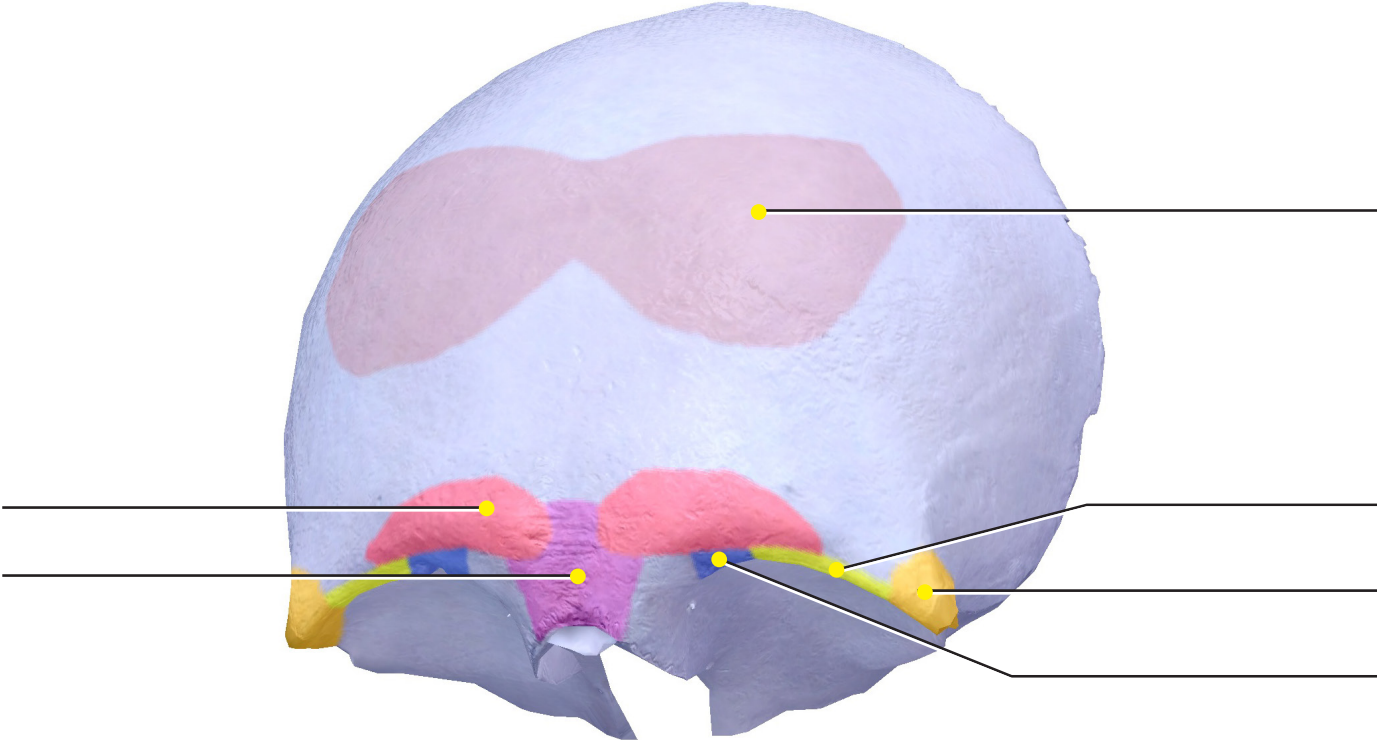
Module 10.4 Occipital Bone Landmarks



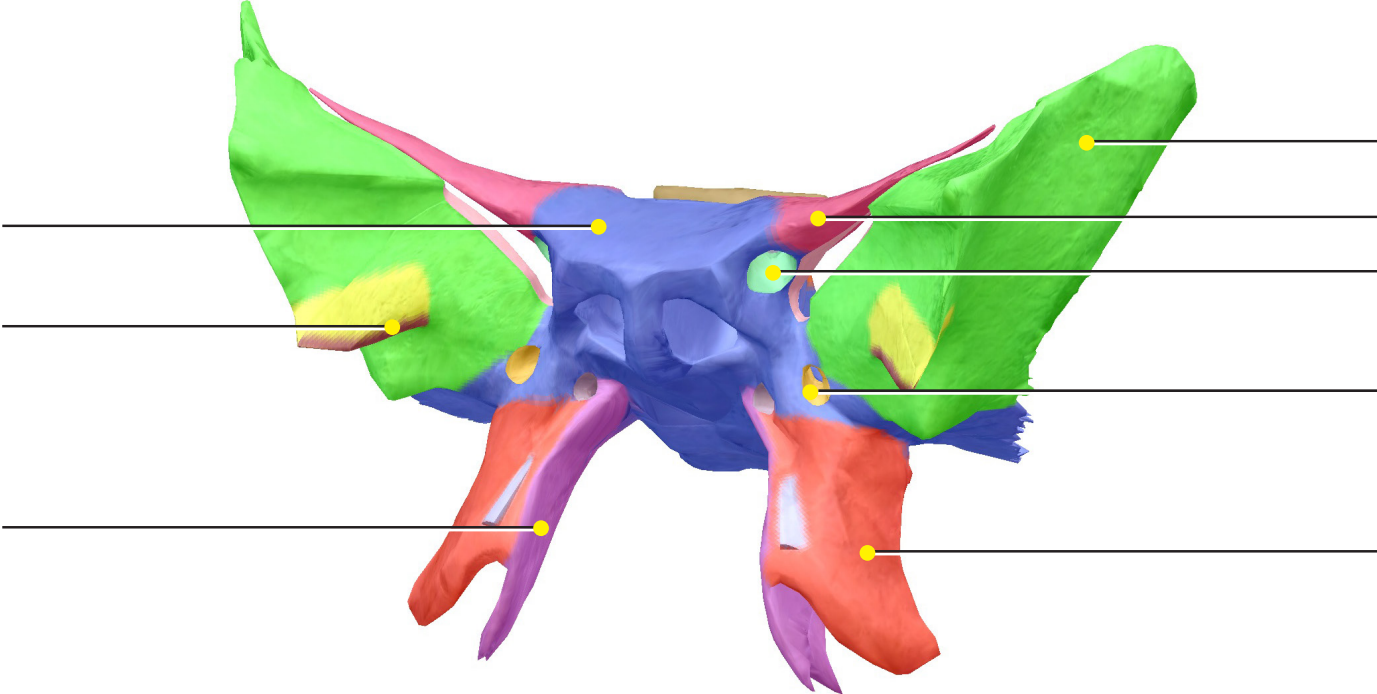
Module 10.5 Temporal Bone Landmarks



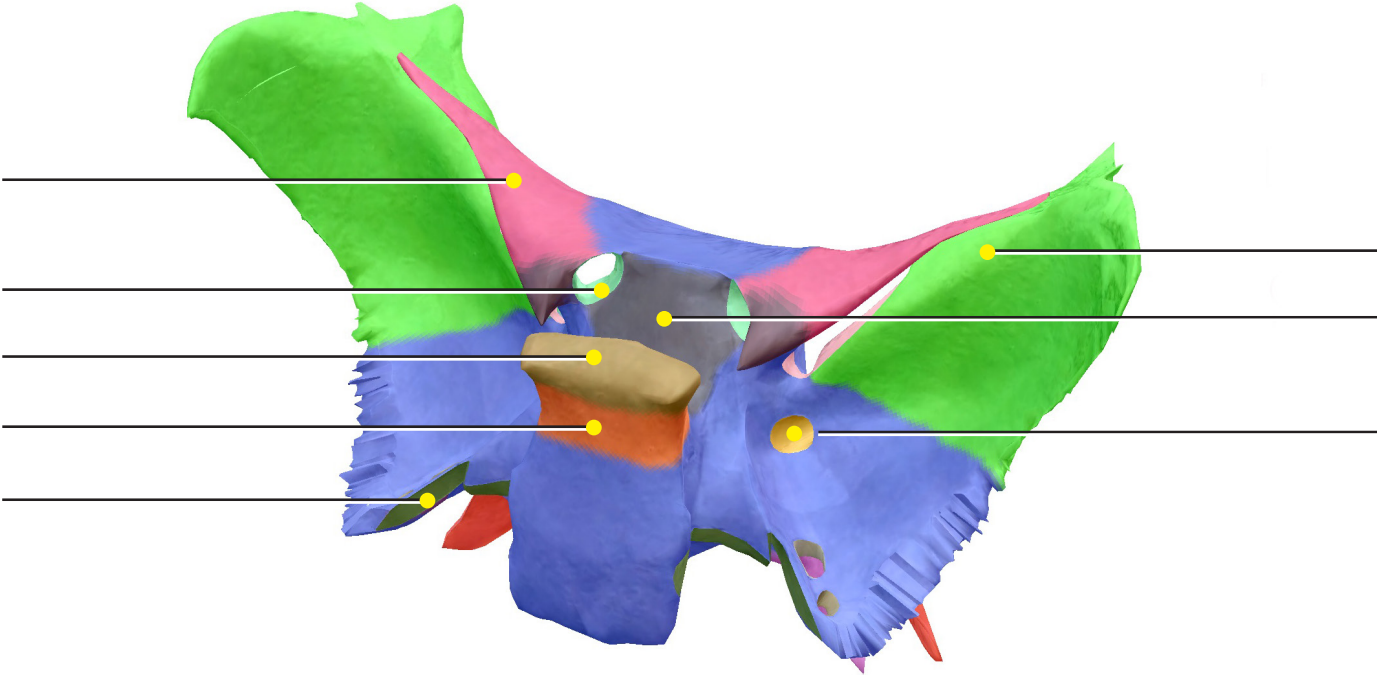
Module 10.6 Frontal Bone Landmarks



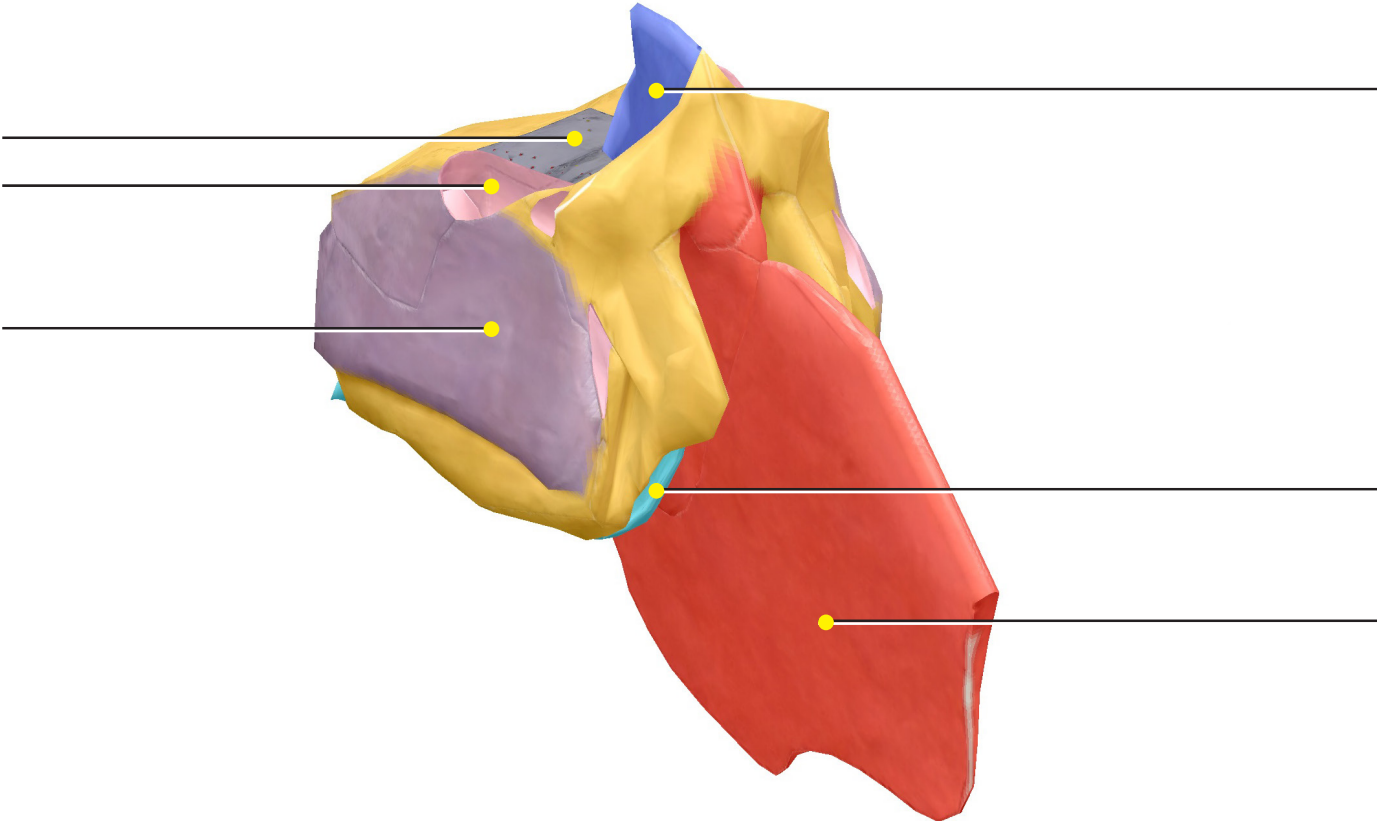
Module 10.7 Sphenoid Bone Landmarks (Part 1)



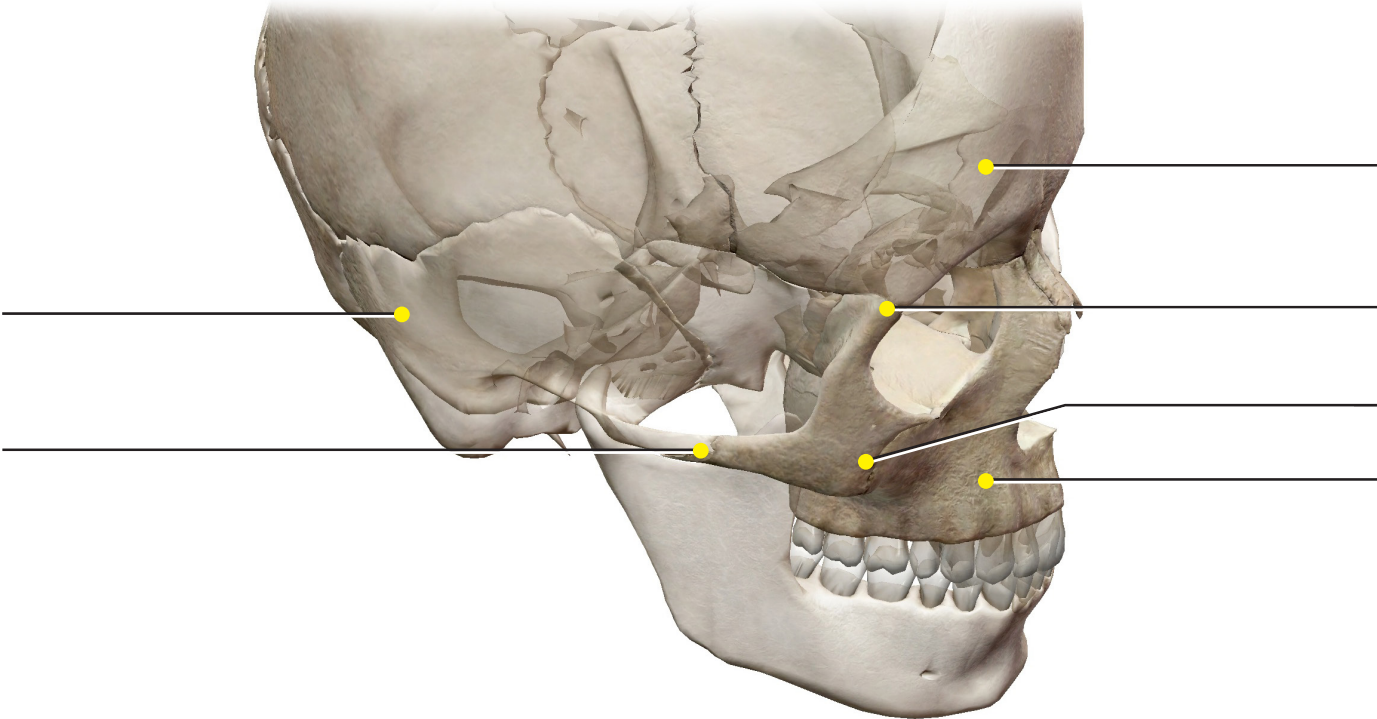
Module 10.7 Sphenoid Bone Landmarks (Part 2)



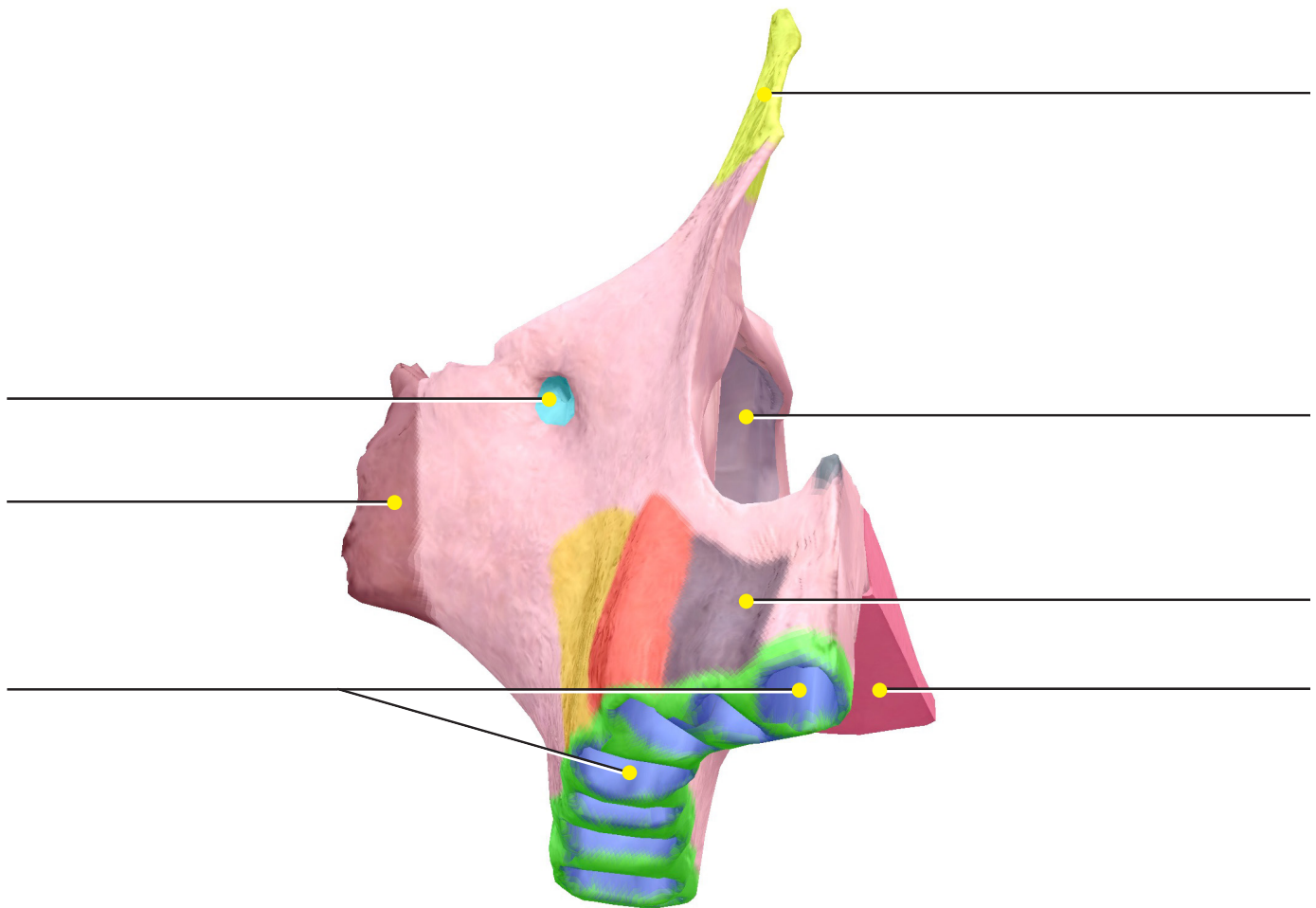
Module 10.8 Ethmoid Bone Landmarks



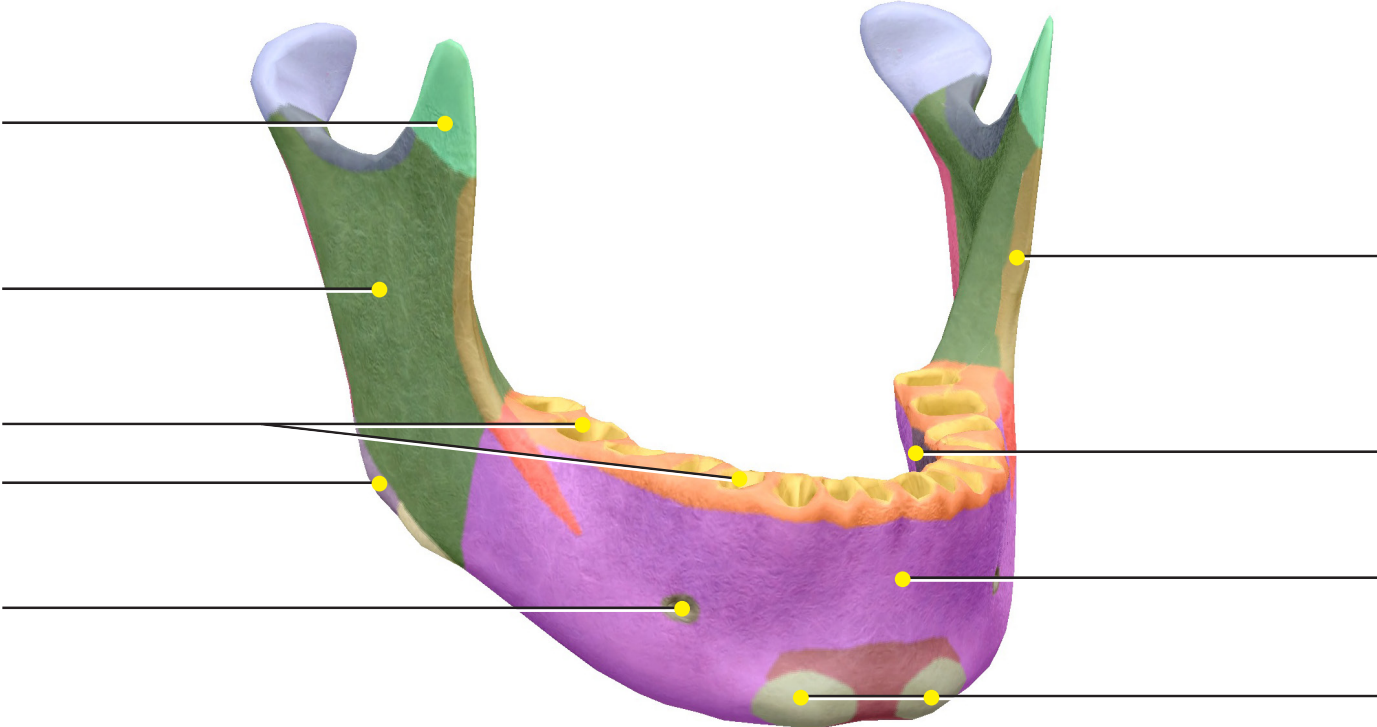
Module 10.11 Facial Skeleton I



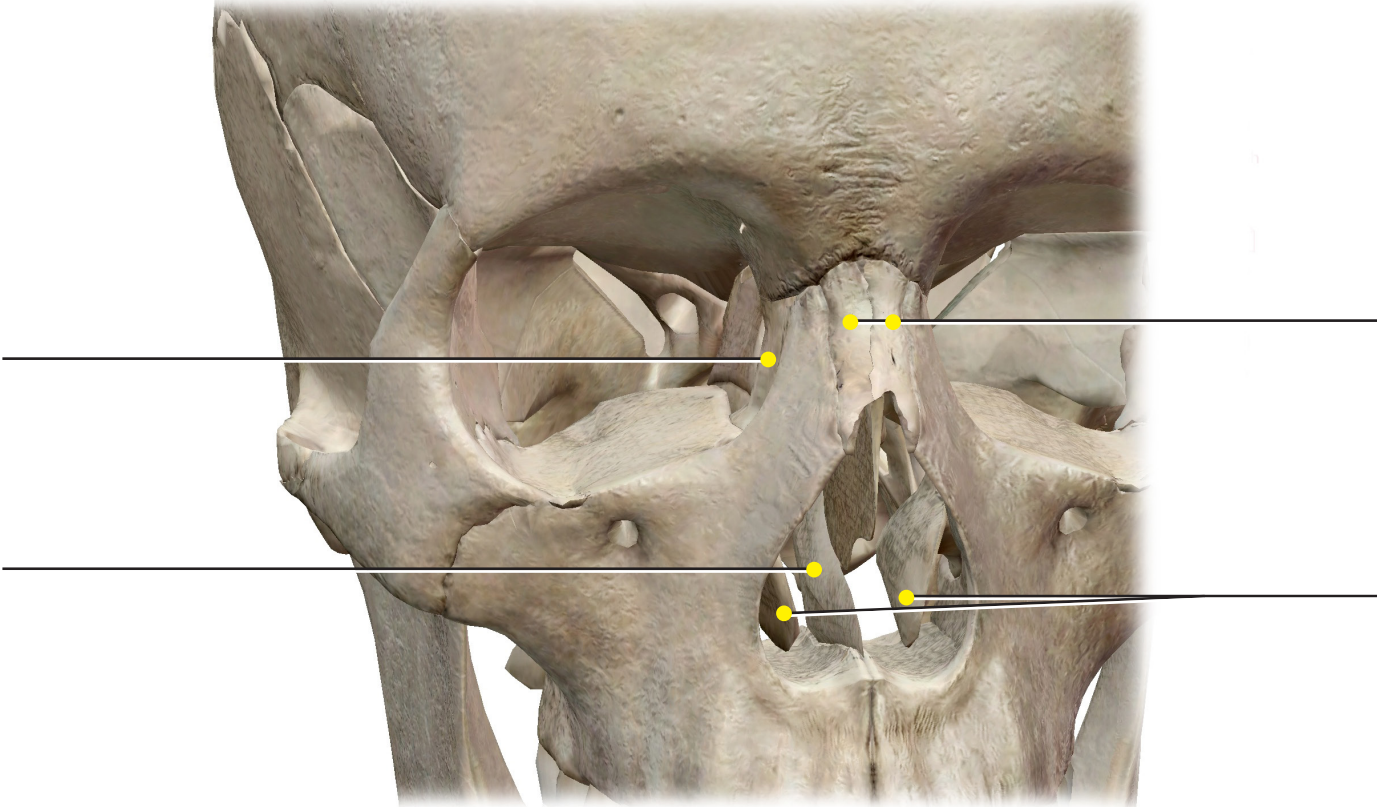
Module 10.12 Maxilla Landmarks



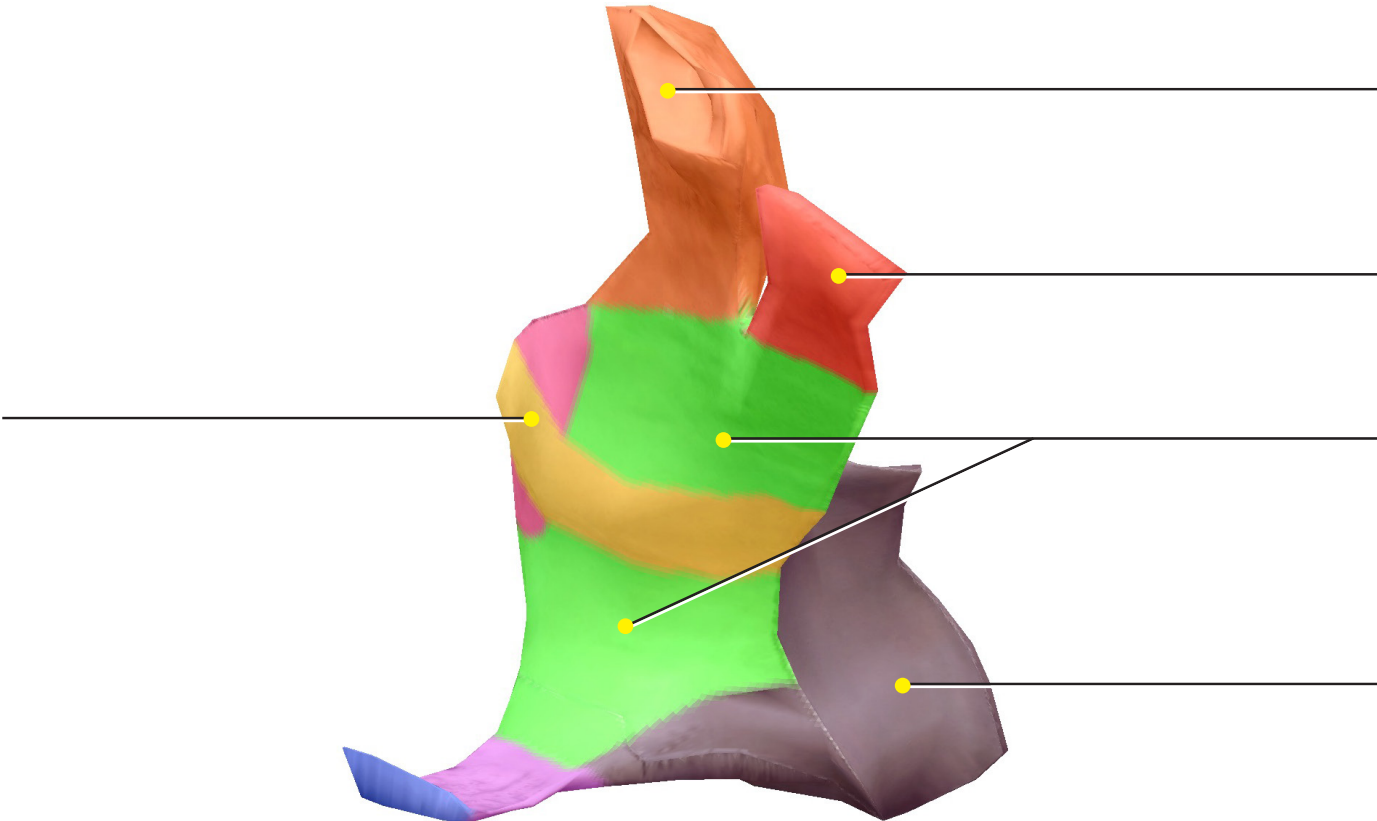
Module 10.13 Mandible Landmarks



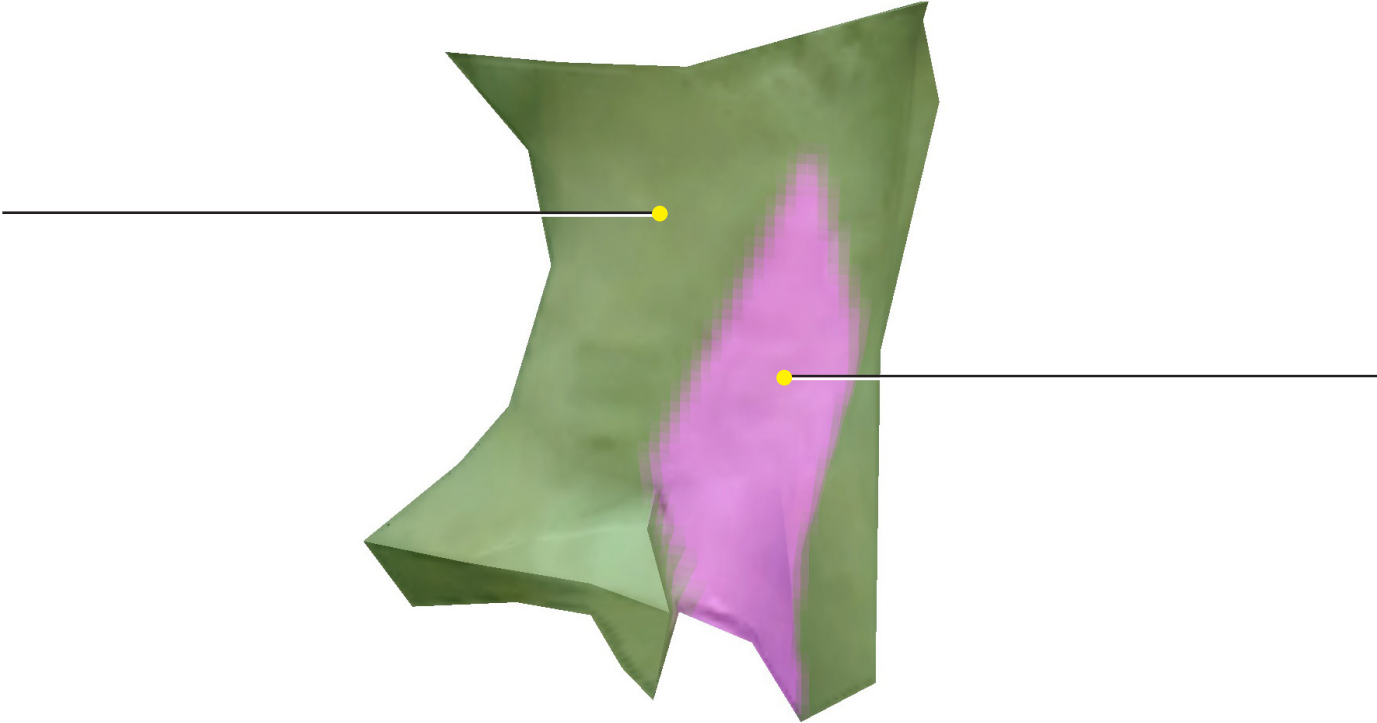
Module 10.14 Facial Skeleton II



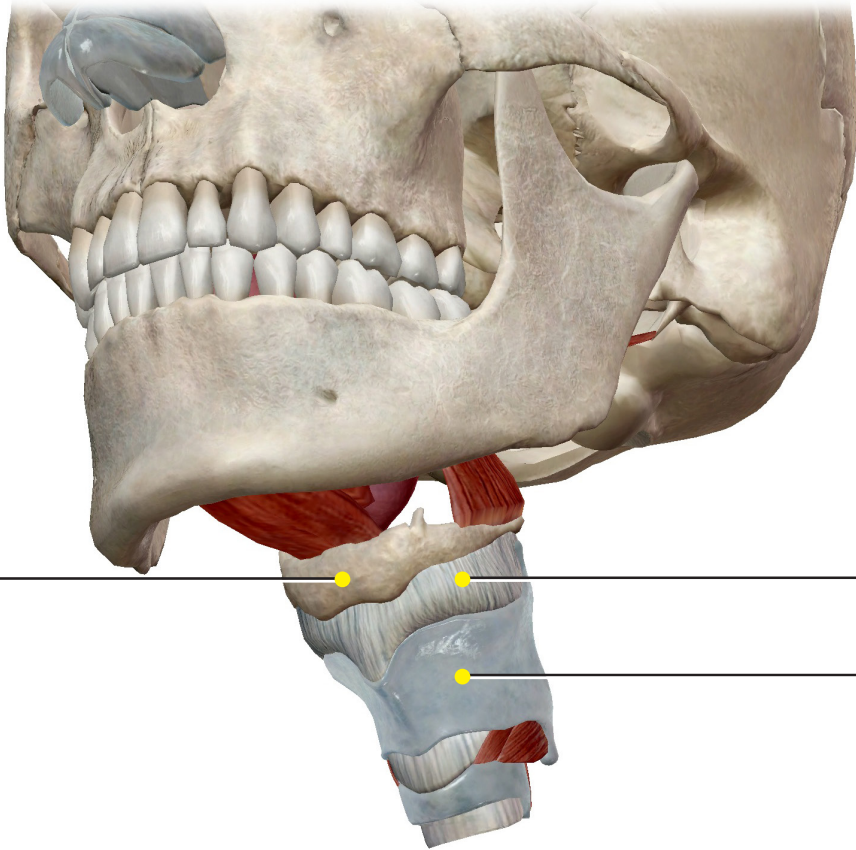
Module 10.15 Palatine Bone Landmarks



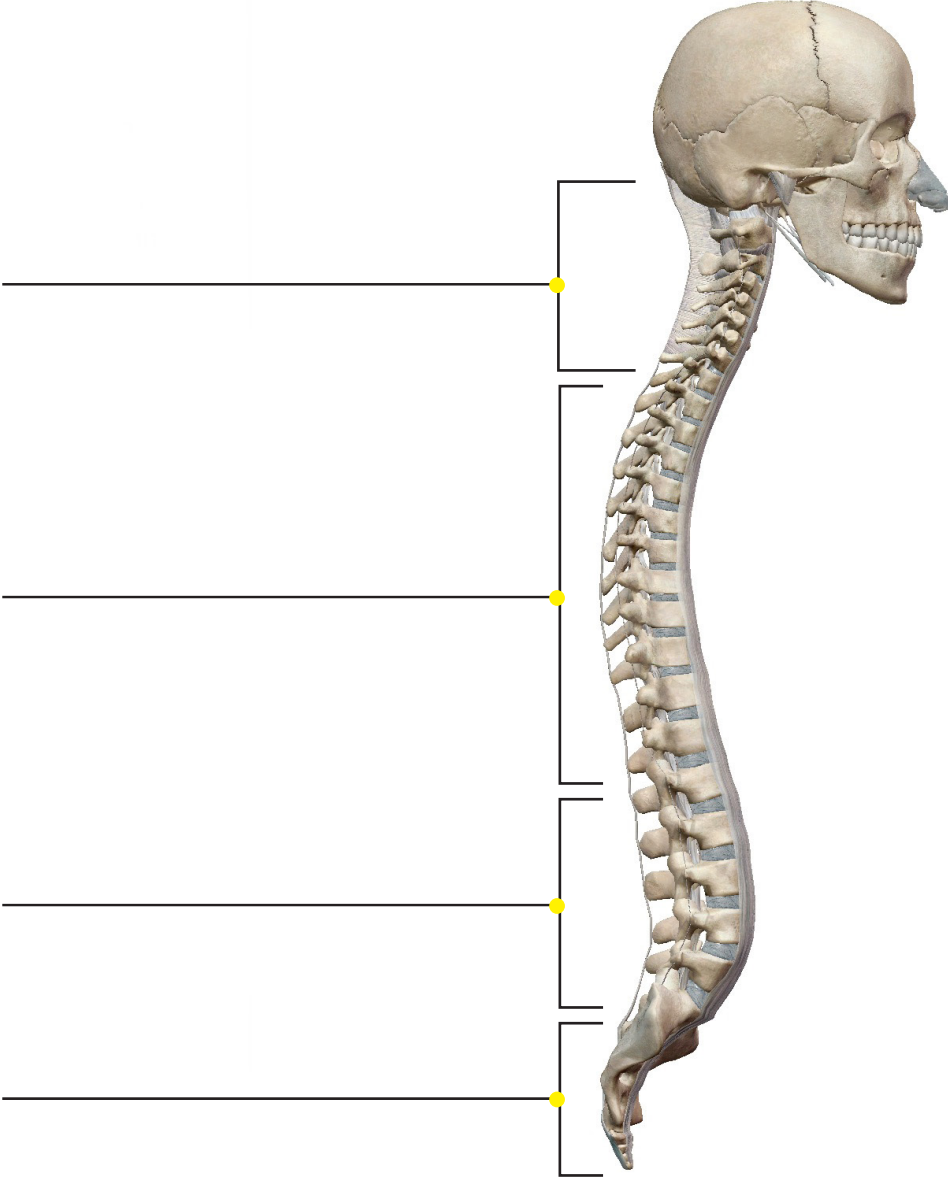
Module 10.16 Lacrimal Bone Landmarks



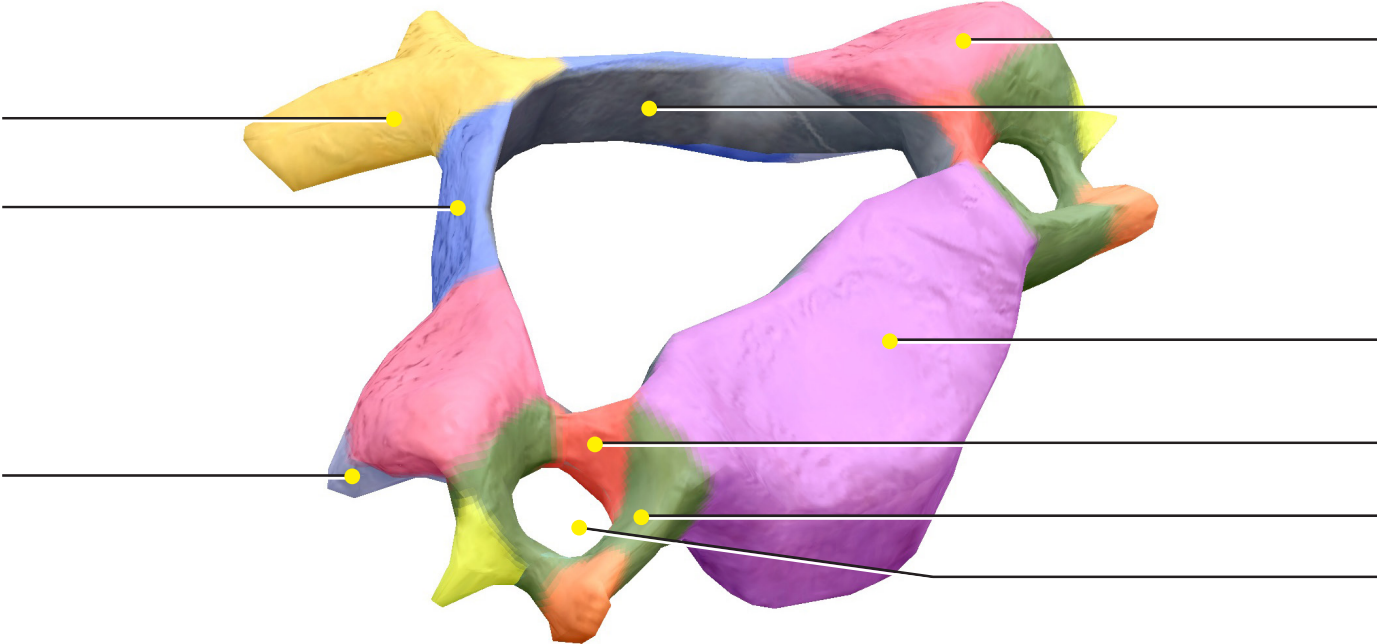
Module 10.21 Hyoid



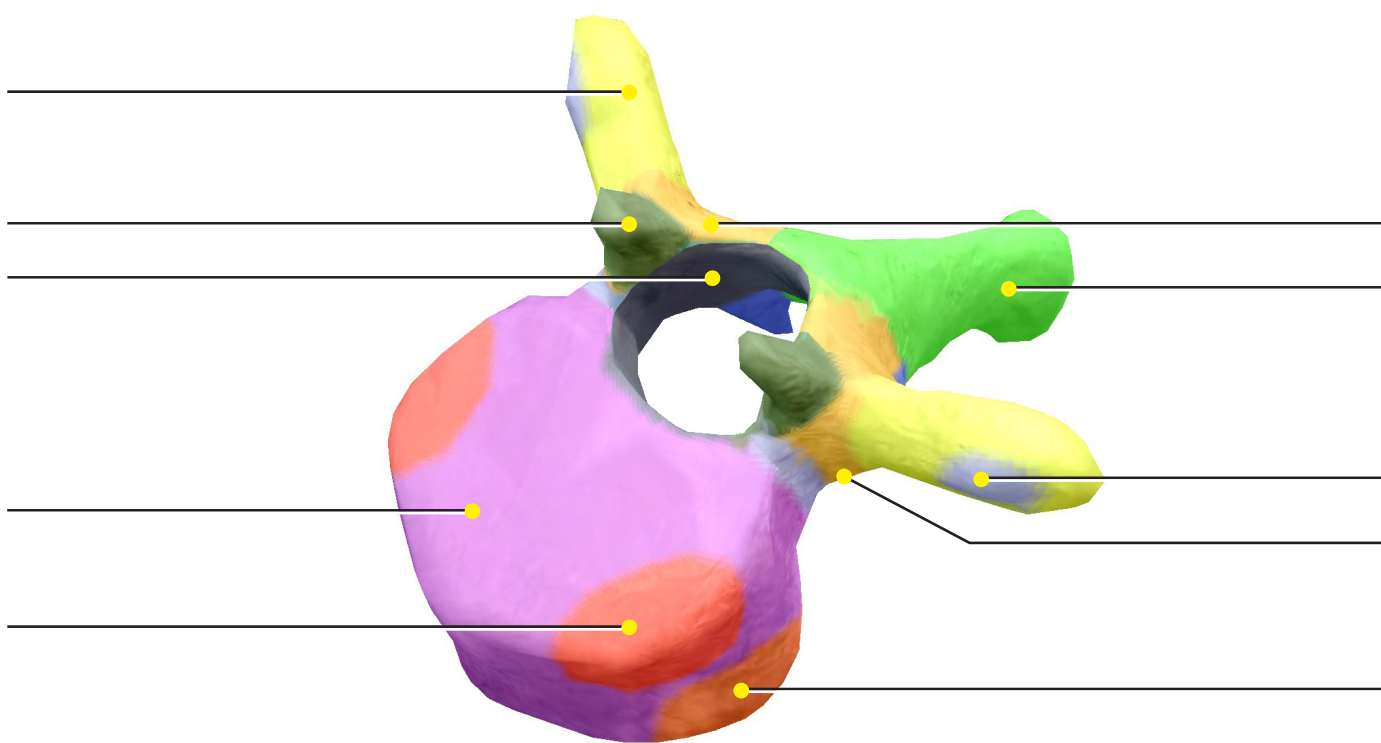
Module 10.22 Vertebral Column



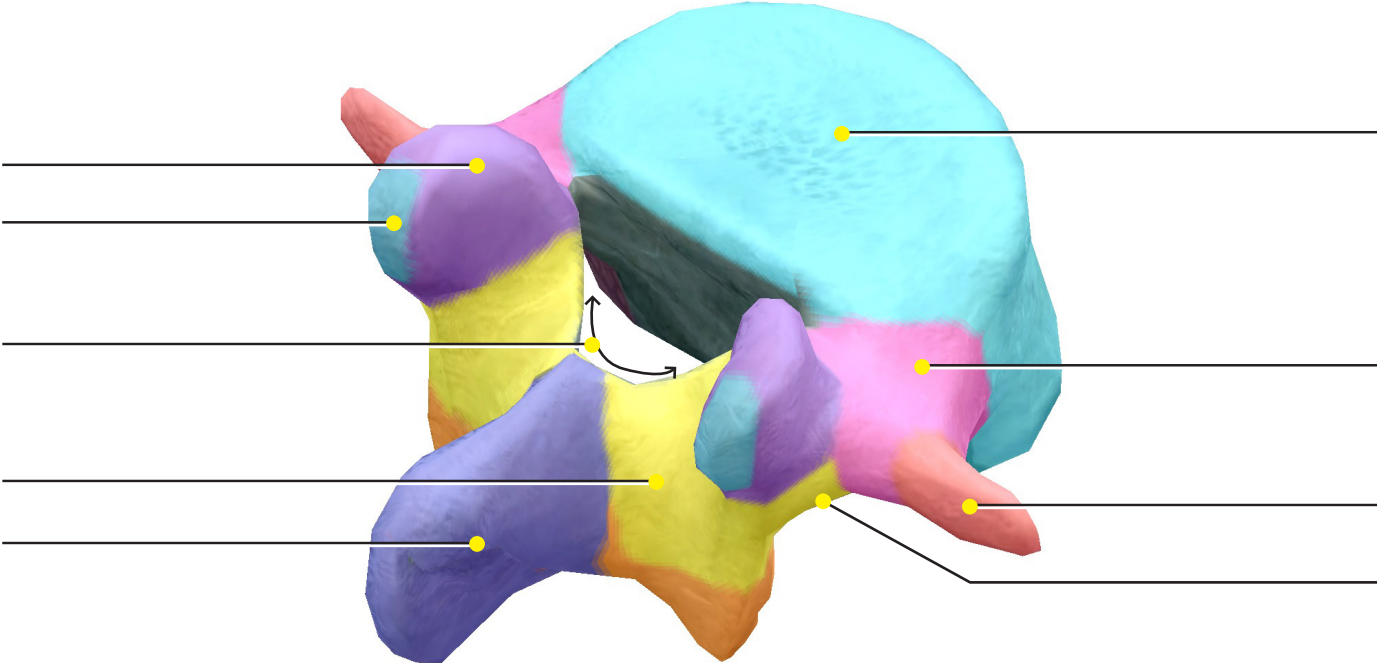
Module 10.27 Cervical Spine Landmarks



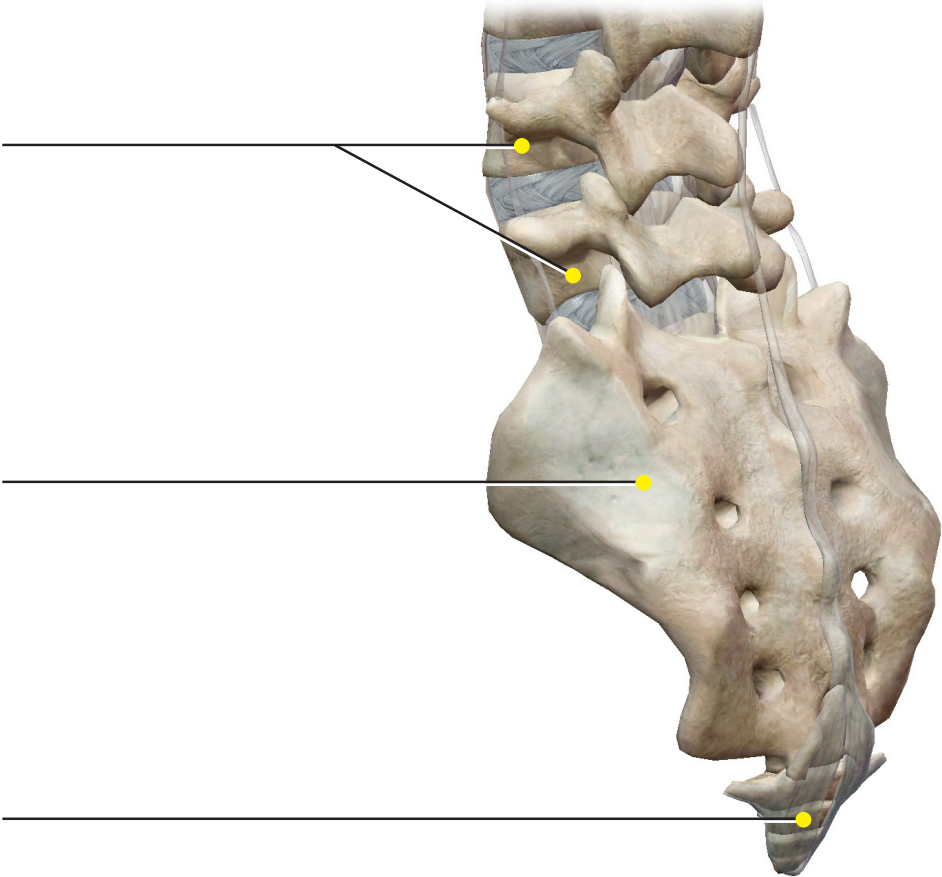
Module 10.29 Thoracic Spine Landmarks



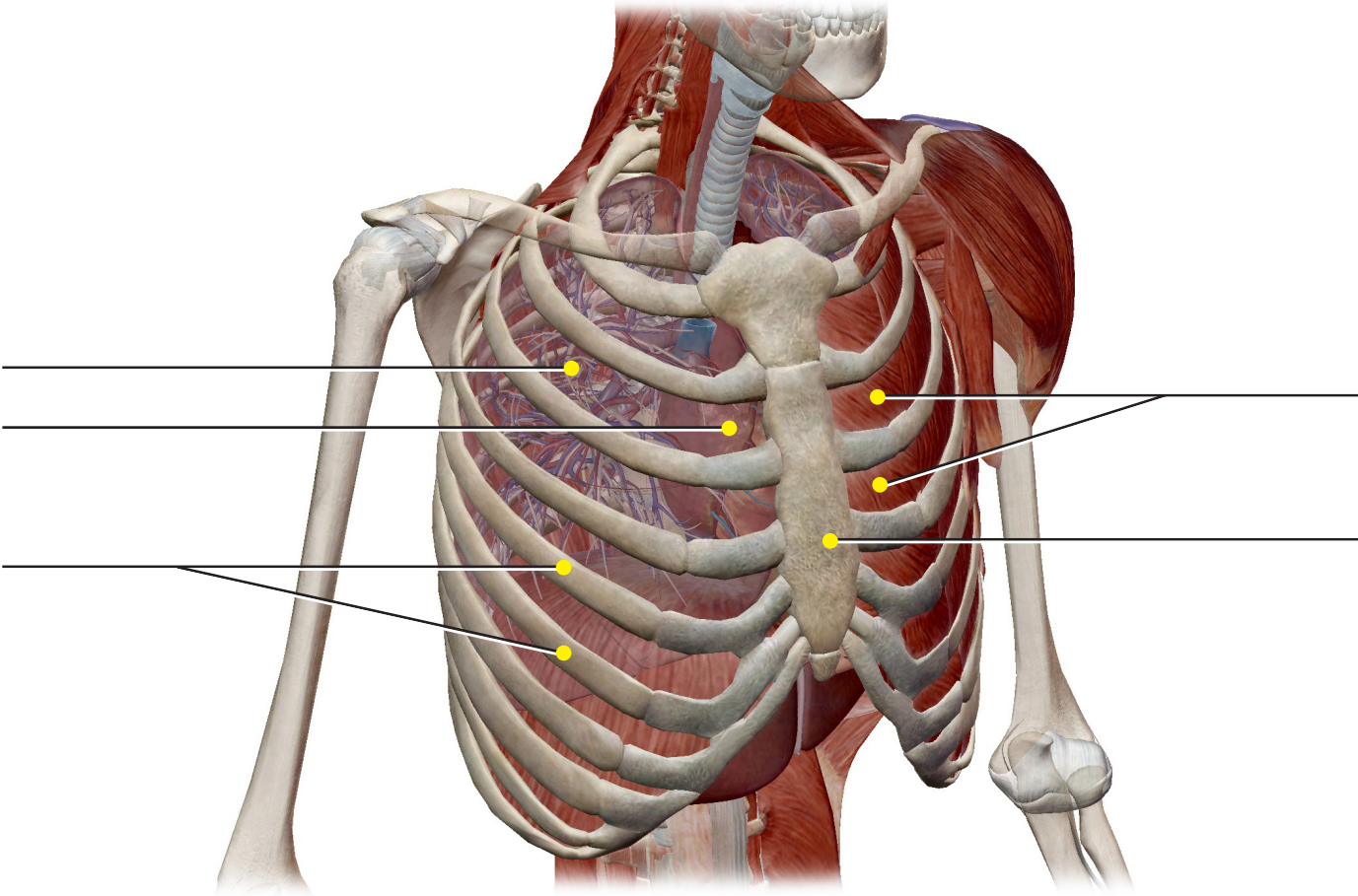
Module 10.31 Lumbar Spine Landmarks



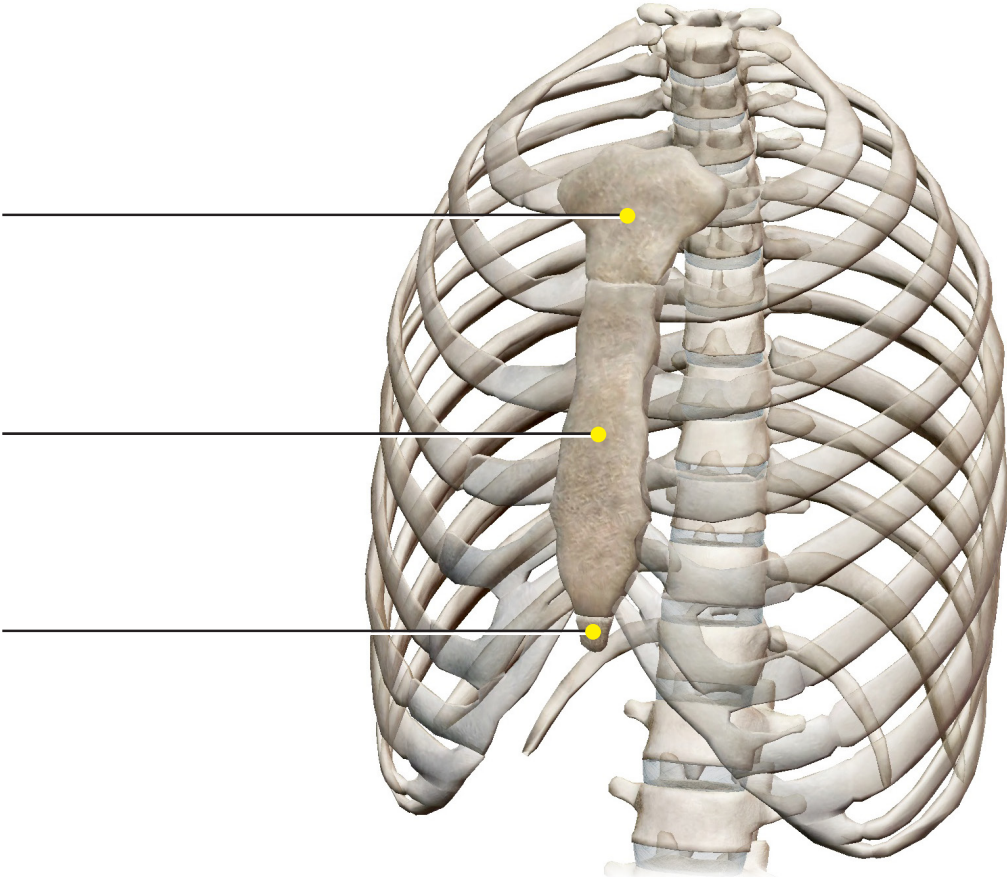
Module 10.32 Sacral Spine



Module 10.33 Thoracic Cage



Module 10.34 Sternum



Module 10.35 Ribs

