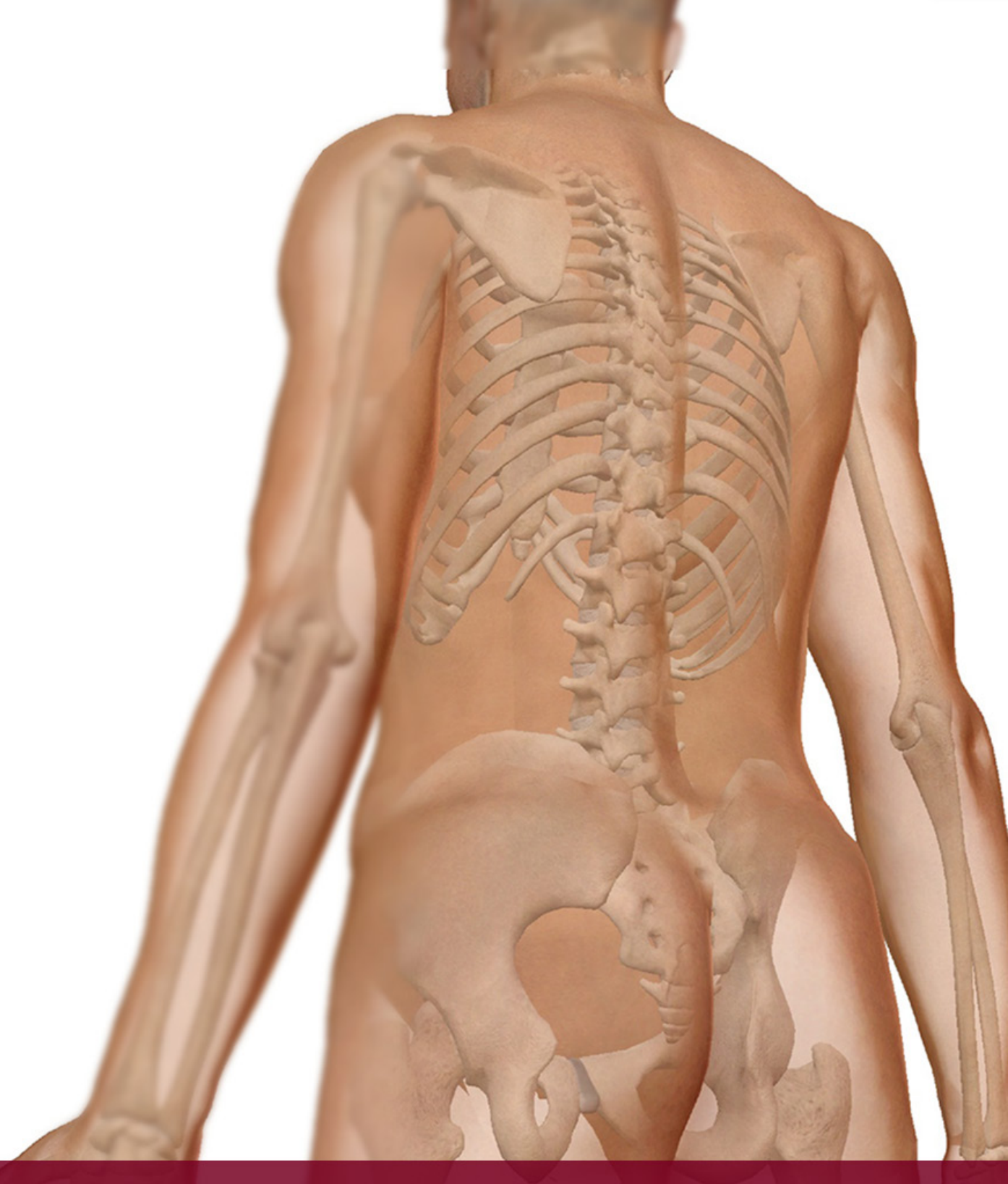

The Appendicular Skeleton

A skeletal system lab activity using Visible Body's Anatomy & Physiology

Stephanie Wallace, Instructor of Biology, TCU

PRE-LAB EXERCISES

When studying the skeletal system, the bones are often sorted into two broad categories: the axial skeleton and the appendicular skeleton. This lab focuses on the appendicular skeleton, which is formed from the pectoral and pelvic girdles and the upper and lower limbs. View Module 7.2 Axial and Appendicular Skeleton to highlight the bones of the appendicular skeleton and compare them to those of the axial skeleton. Examine Module 11.1 Appendicular Skeleton to view only the bones of the appendicular skeleton.

In addition to learning about all the bones of the appendicular skeleton, it is also important to identify some significant bone markings. Bone markings can have many shapes, including holes, round or sharp projections, and shallow or deep valleys, among others. These markings on the bones serve many purposes, including forming attachments to other bones or muscles and allowing passage of a blood vessel or nerve. It is helpful to understand the meanings of some of the more common bone marking terms.

Before we get started, look up the definitions of these common bone marking terms:

Canal:

Condyle:

Facet:

Fissure:

Foramen: (see Module 10.18 Foramina of Skull)

Fossa:

Margin:

Process:

Proximal:

Trochanter:

Tubercle:

Tuberosity:

Throughout this exercise, you will notice bold terms. This is meant to focus your attention on these important words. Make sure you pay attention to any bold words and know how to explain their definitions and/or where they are located.

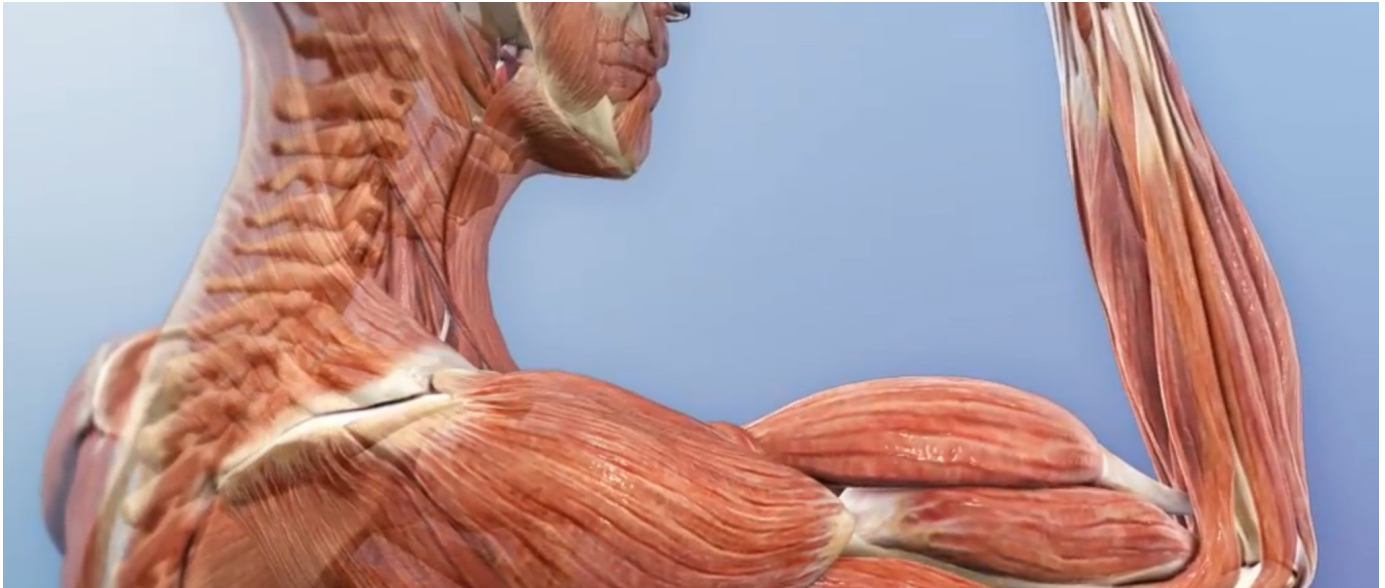
Use the following modules to guide your exploration of the appendicular skeleton. As you explore these bones in Visible Body's app, also locate the bones and bone markings on any available charts, models, or specimens. You may also find it helpful to palpate bones on yourself or make drawings of the bones with the bone markings labeled. The drawings don't have to be perfect; just make sure the different bone markings are in the correct locations, relative to each other.

Open the A&P app, and from the left-side menu, select the Skeletal System.

You are responsible for the identification of **all bold terms** and answers to the questions.

A. Skeletal System Overview

Watch the video in Module 7.1 Skeletal System Overview, examine the 3D anatomical view in Module 7.3 Function of the Skeleton, and answer the following questions.



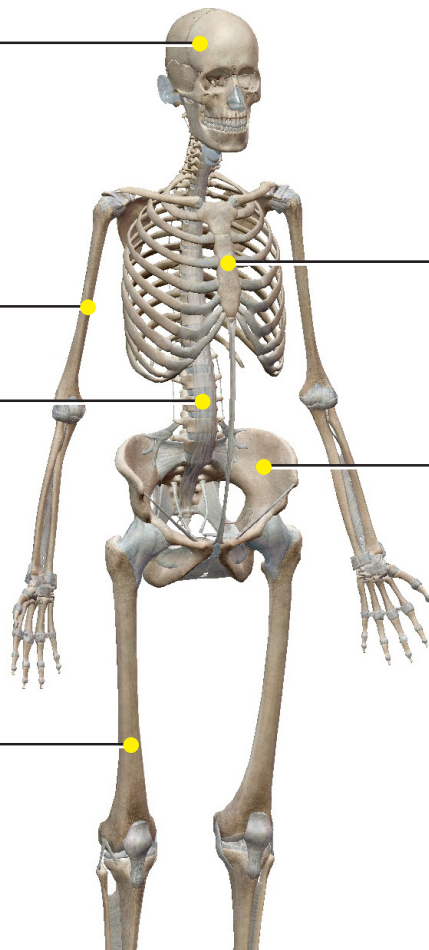
Module 7.3 Function of the Skeleton

Skull

Upper limb

Vertebral column

Lower limb



Thoracic cage

Pelvic girdle

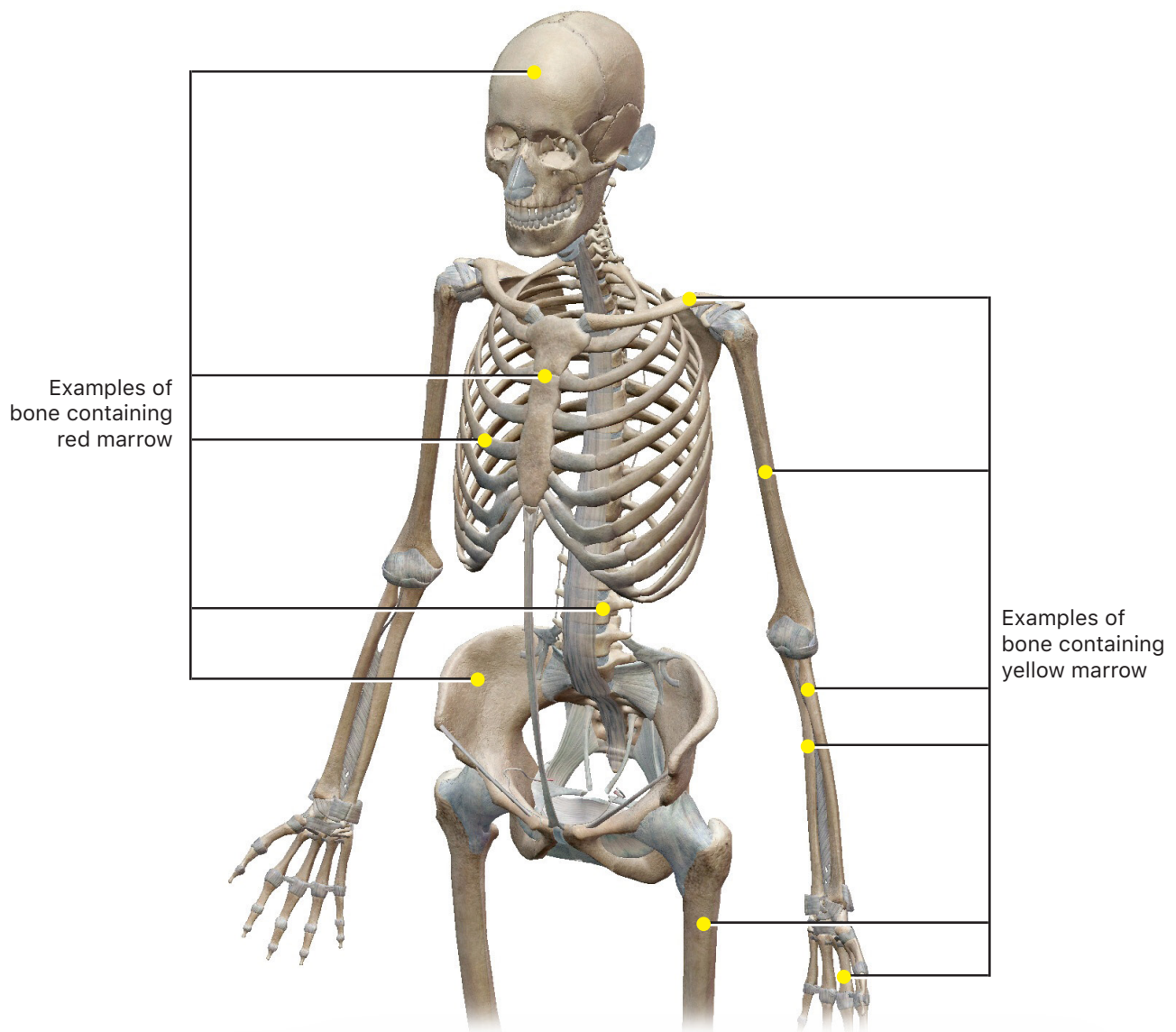
1. How does the skeletal system facilitate movement?
2. What other functions does the skeletal system perform?

B. Long Bone Anatomy

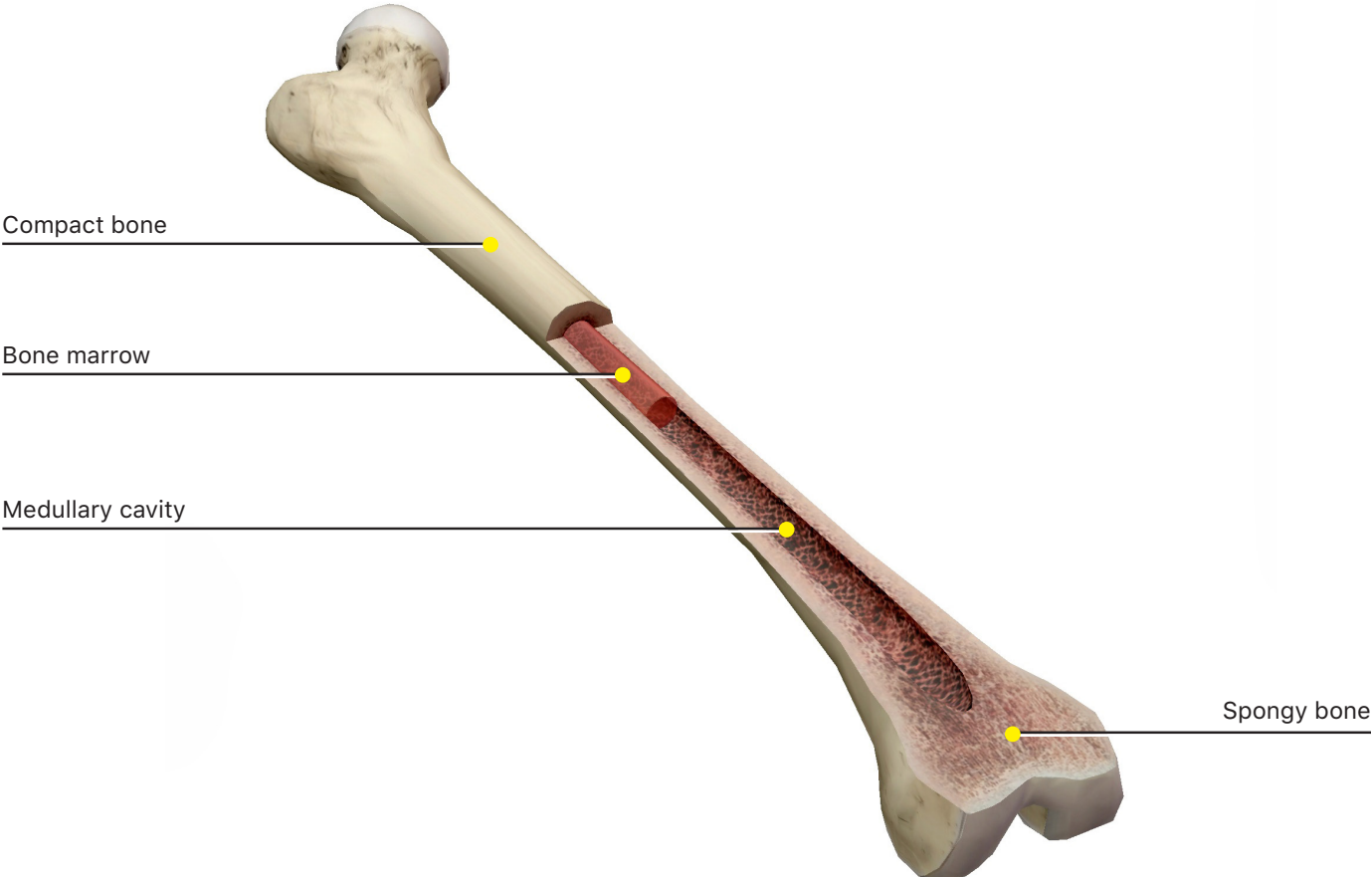
Long bones are common in the appendicular skeleton, because they support the weight of the body and facilitate movement.

Explore the anatomy of long bones by viewing Modules 9.1 Bone Marrow, 9.2 Interior of a Long Bone, and 9.3 Parts of a Long Bone, and then answer the following questions.

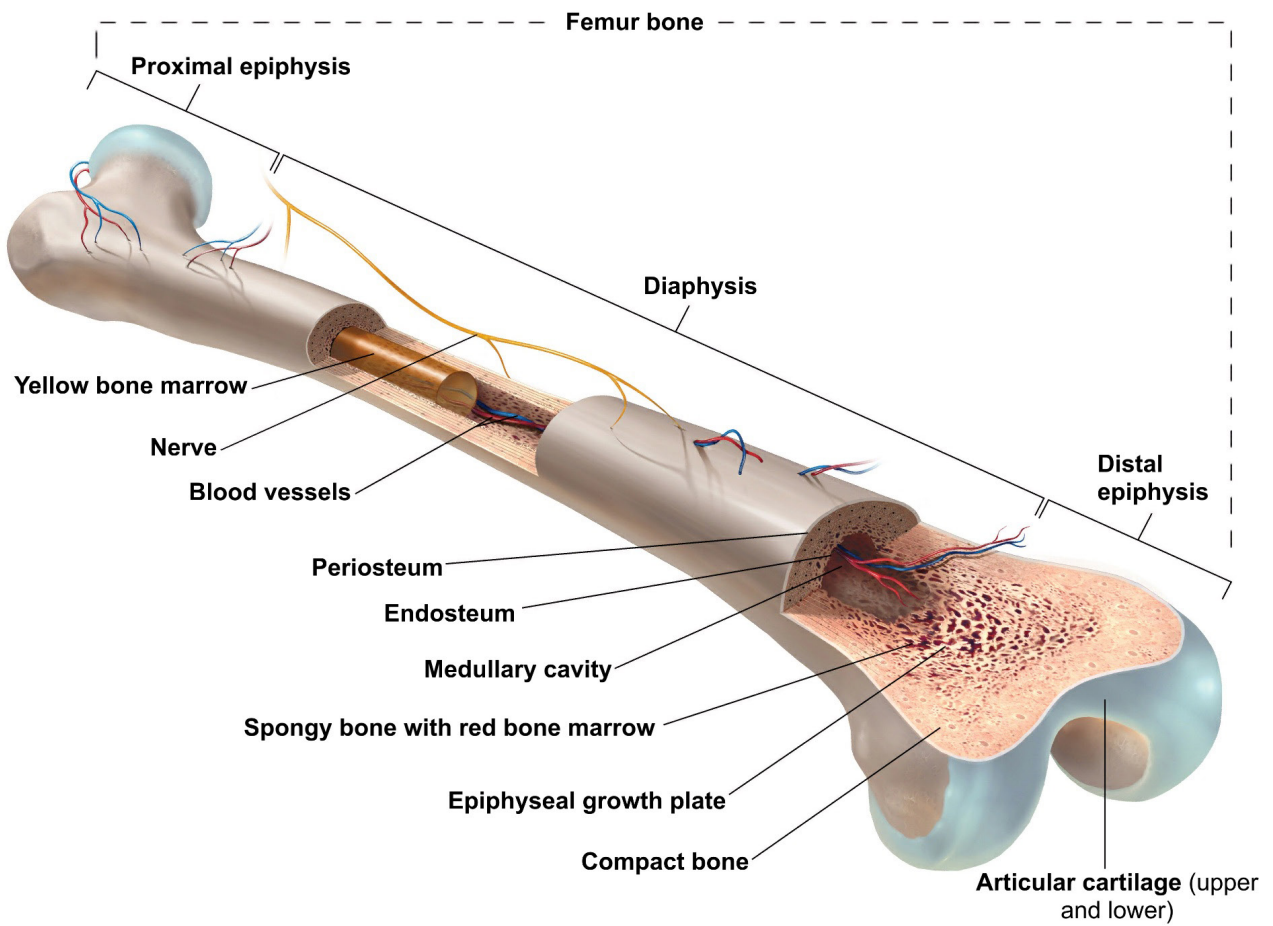
Module 9.1 Bone Marrow



Module 9.2 Interior of a Long Bone



Module 9.3 Parts of a Long Bone



1. What is the difference in composition between **red bone marrow** and **yellow bone marrow**?

2. Where is each type of marrow found in the body?

3. Where is **compact bone** found in comparison to **spongy bone**?

4. Where is the **medullary cavity** found in comparison to **compact bone**?

5. In the space below, draw your own long bone, and label the following structures:

Shaft

Diaphysis

Epiphysis

Epiphyseal growth plate

Medullary cavity

Periosteum

Endosteum

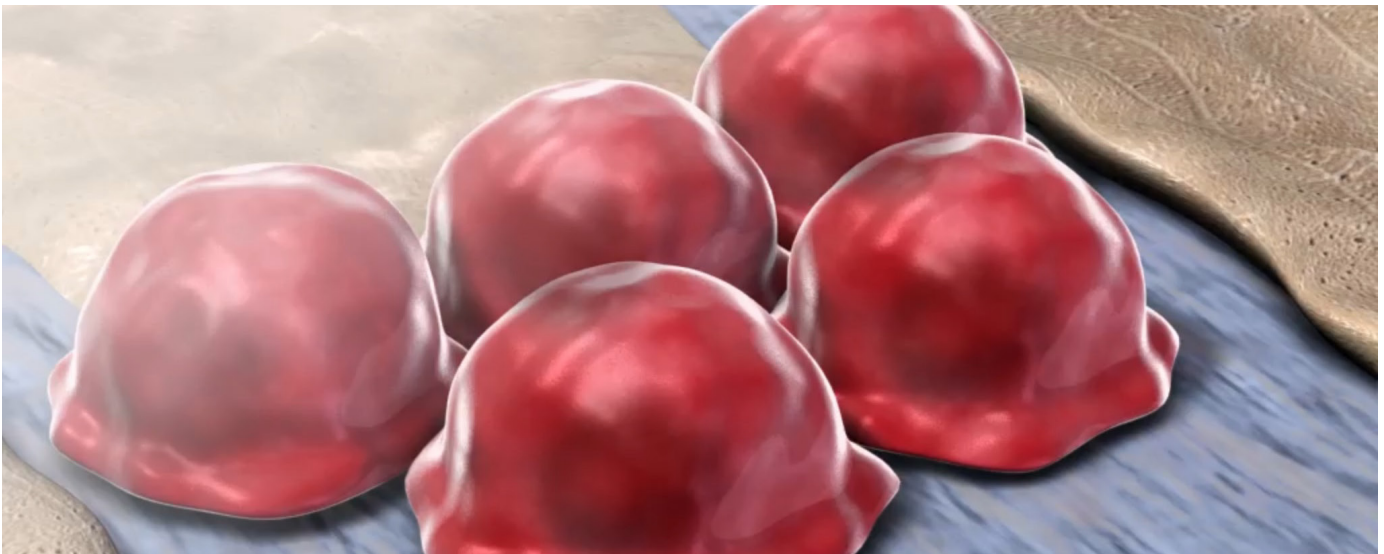
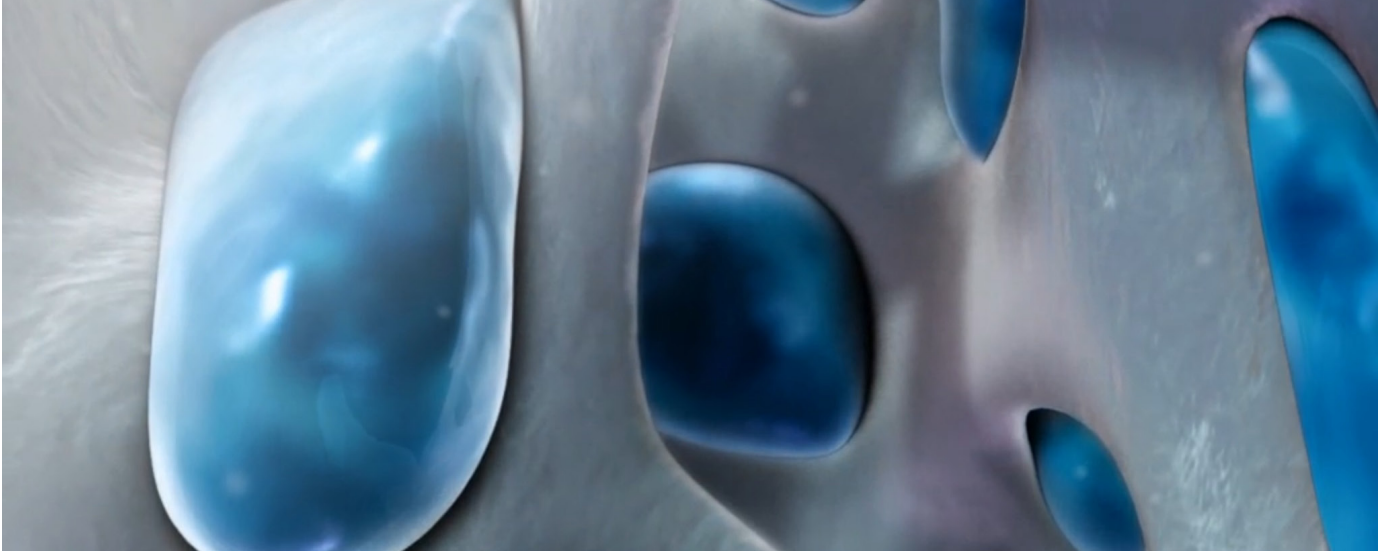
Compact bone

Spongy bone

C. Long Bone Growth and Repair

Long bones use a different growth mechanism than the skull. While flat bones such as those in the skull develop through intramembranous ossification, the rest of the bones in the body develop via endochondral ossification.

Use Modules 9.9 Long Bone Formation and Growth and 9.10 Long Bones in the Limbs to explore how endochondral ossification works and answer the following questions.



1. What substance initially forms the framework on which the bone will be based?
2. What happens to the above substance as **osteoblasts** begin to lay down bone?
3. How are osteoblasts delivered to the area?

D. Fractures and Bone Repair

There are many different ways to break a bone, but the break is always called a **fracture**. There are different names for different types of fractures, depending on how the bone breaks.

View Module 9.11 Types of Fractures to familiarize yourself with the different types, watch the video in Module 9.12 Bone Repair to see how fractures are repaired, and answer the following questions.

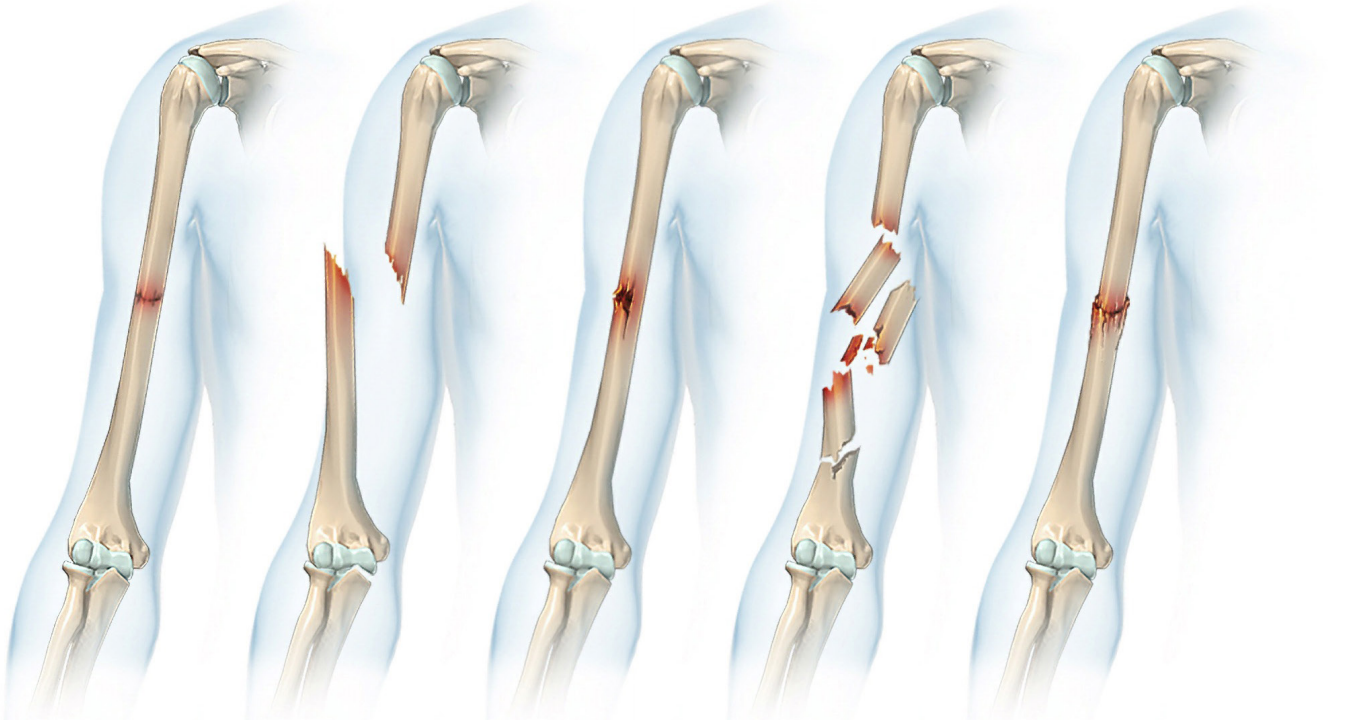
Closed (Simple)

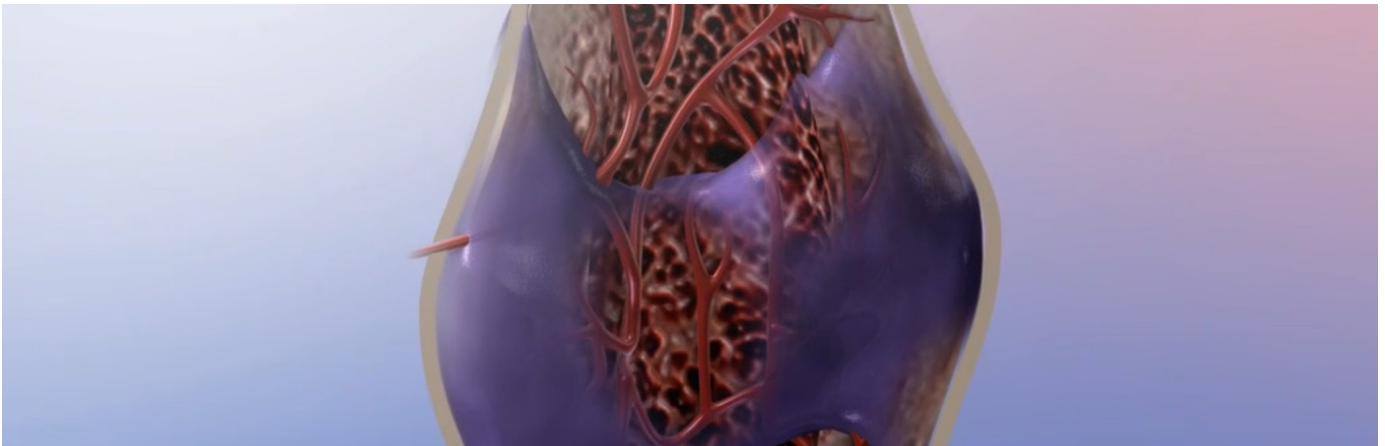
Open (Compound)

Greenstick

Comminuted

Impacted





1. Which type of fracture results in a bone break inside the skin?
2. Greenstick fractures are common in children. Describe what one looks like.
3. This fracture results when a bone is crushed into pieces.
4. What is a hematoma?
5. Which cells are responsible for removing dead bone tissue?
6. Before new bone can be laid down, how is the gap bridged in the broken bone?
7. What external factors influence how the bone is shaped?

IN-LAB EXERCISES

Open the A&P app, and from the left-side menu, select the Skeletal System.

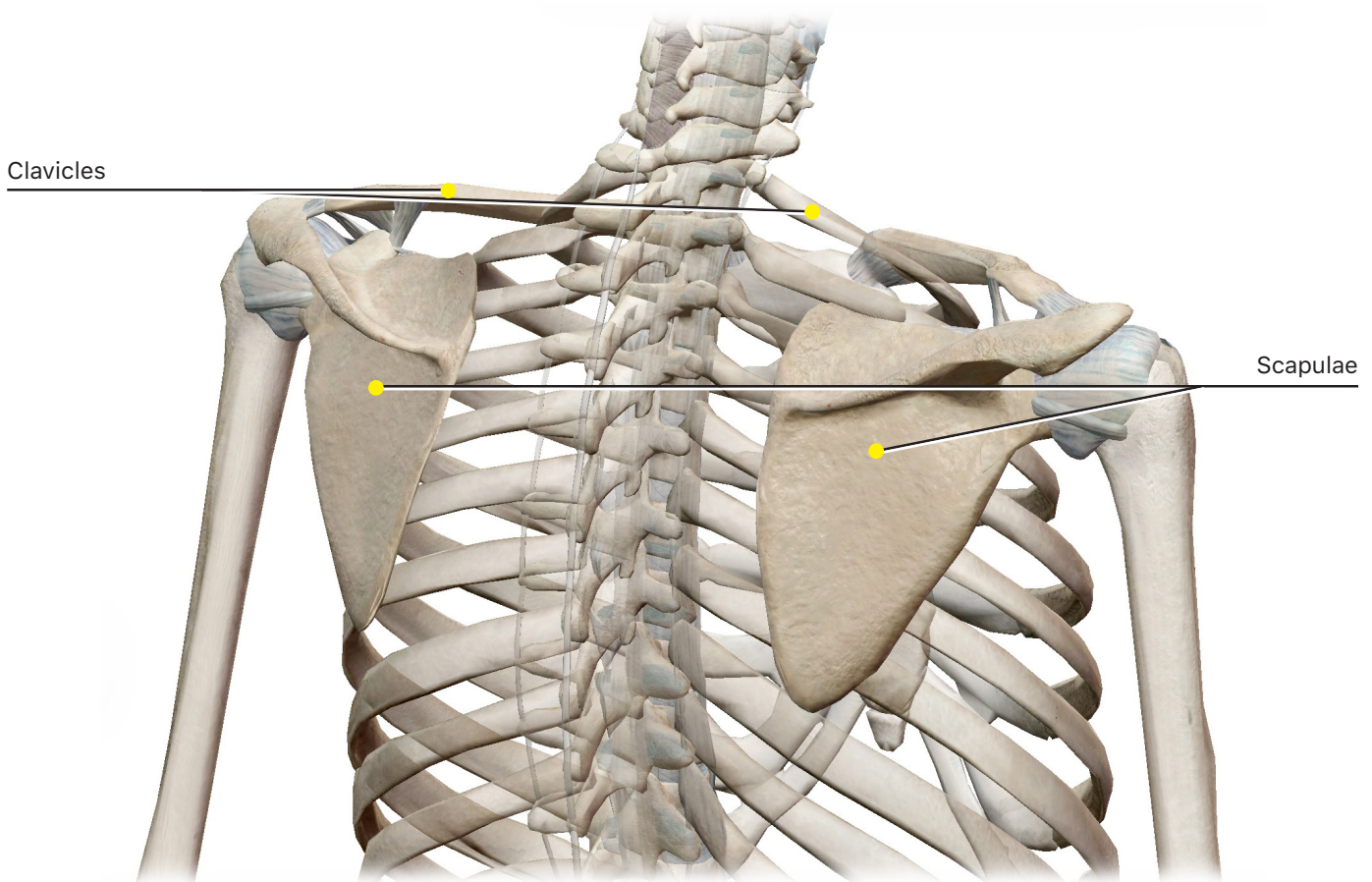
You are responsible for the identification of **all bold terms** and all answers to the questions.

A. The Pectoral Girdle

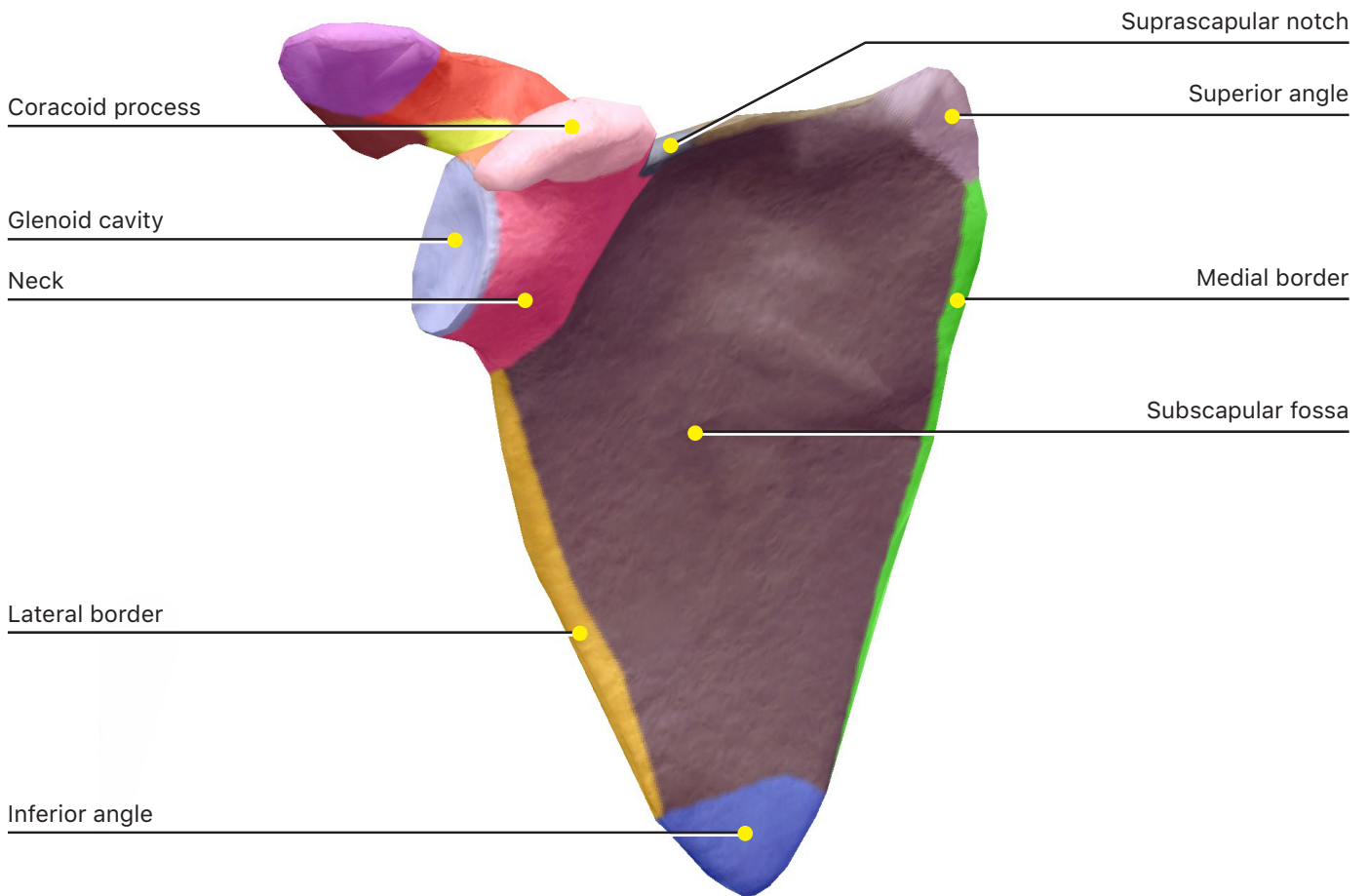
View Module 11.2 Pectoral (Shoulder) Girdle to find the clavicles and scapulae. These bones make up the pectoral girdle and are responsible for attaching the upper limbs to the skeleton as well as providing attachment points for the shoulder muscles.

Observe Module 11.5 Muscular Stabilization to see how muscles attach to the clavicles and scapulae. The shoulder has the largest range of motion of any joint in the body, and the many muscles that attach here stabilize the pectoral girdle to allow for that movement. After identifying the bones and how they function in muscle stabilization, find their bone markings and answer the questions.

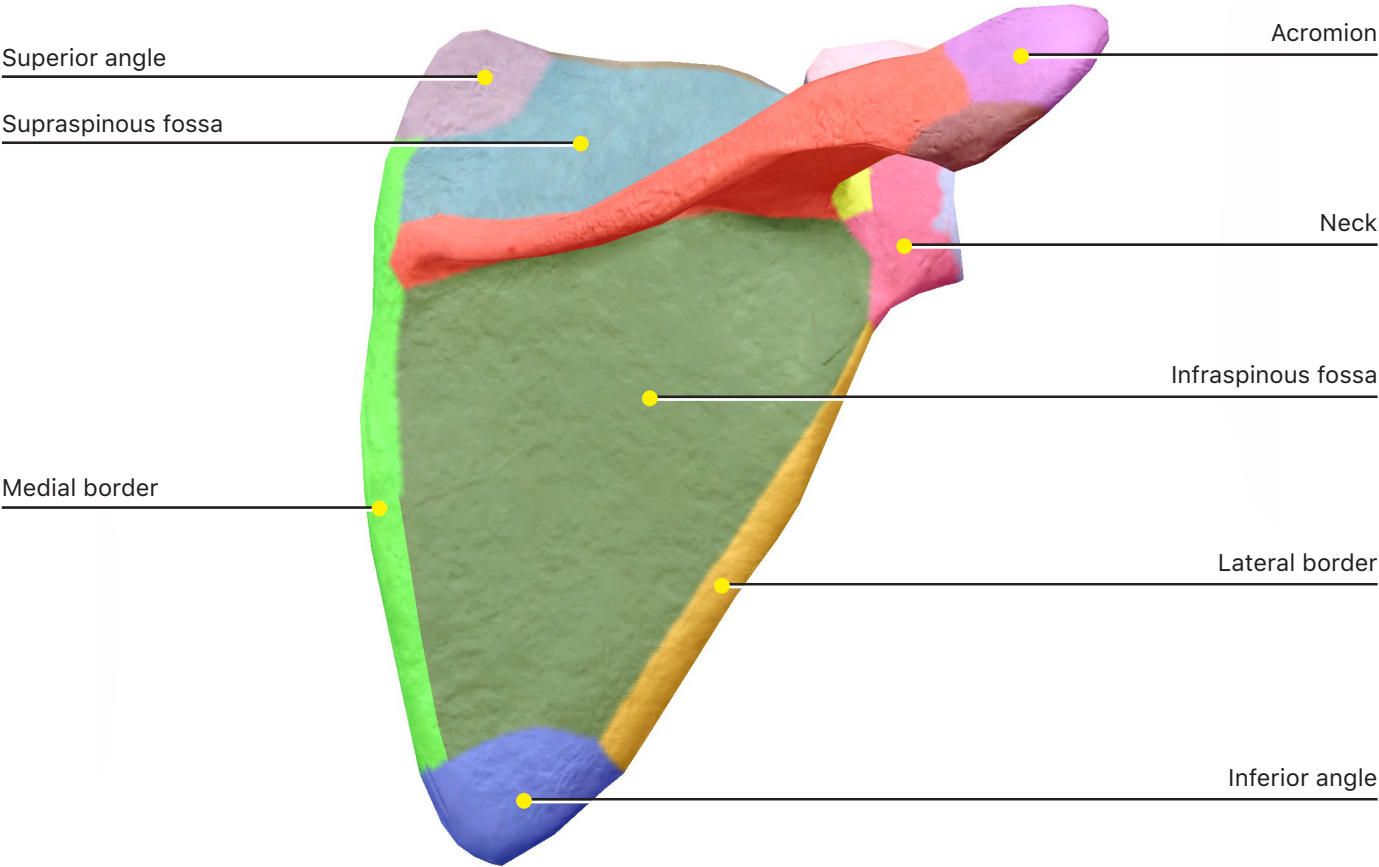
Module 11.2 Pectoral (Shoulder) Girdle



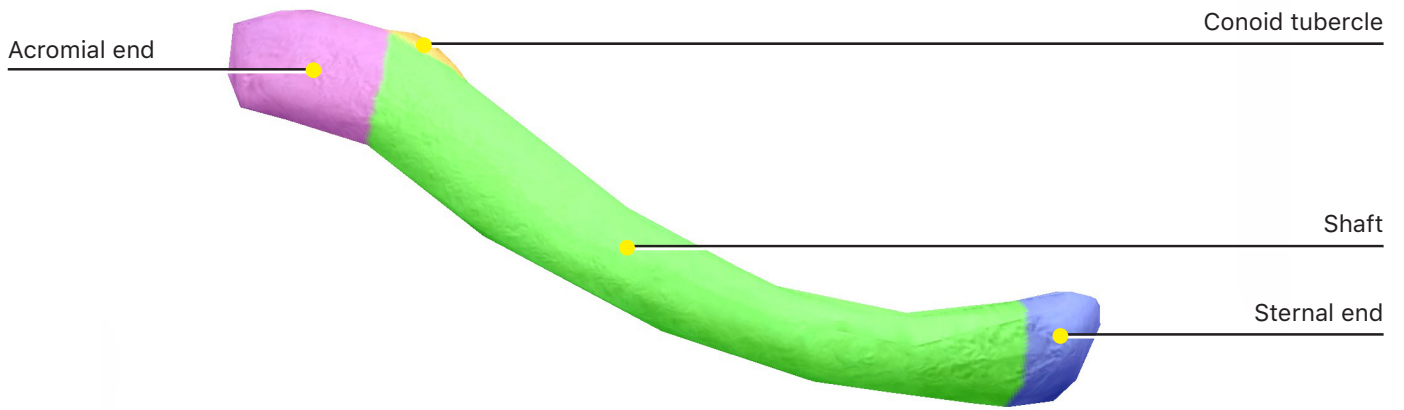
Module 11.3 Scapula Landmarks (Part 1)



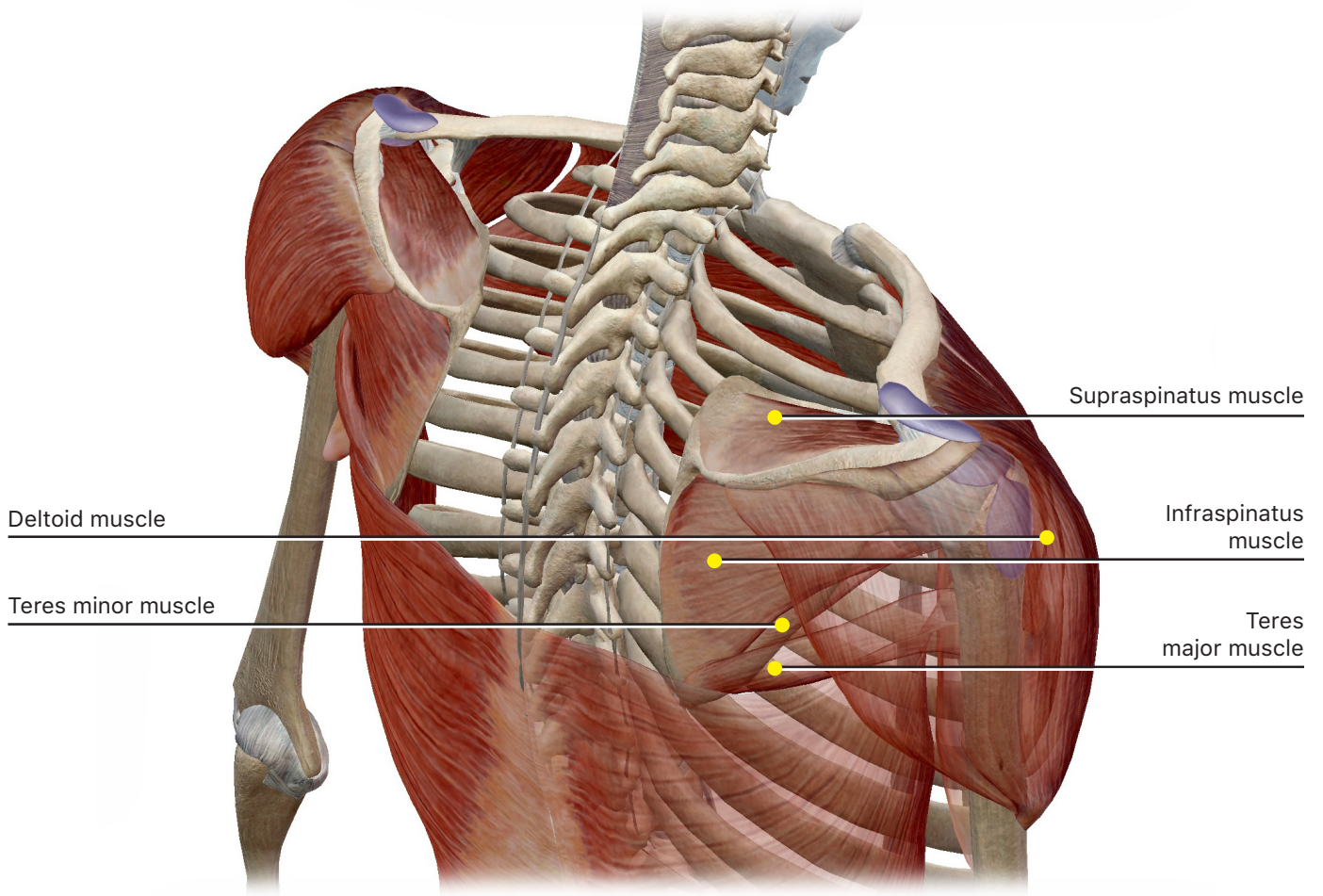
Module 11.3 Scapula Landmarks (Part 2)



Module 11.4 Clavicle Landmarks



Module 11.5 Muscular Stabilization



1. Scapula (see Module 11.3 Scapula Landmarks)

a. Identify the following bone markings:

i. **Glenoid cavity**

ii. **Spine**

iii. **Acromion**

iv. **Coracoid process**

v. **Infraspinous fossa**

vi. **Supraspinous fossa**

vii. **Subscapular fossa**

viii. **Inferior angle**

ix. **Superior angle**

x. **Lateral border**

xi. **Medial border**

xii. **Neck**

xiii. **Acromial angle**

b. Describe how to determine a right scapula from a left scapula.

2. Clavicle (see Module 11.4 Clavicle Landmarks)

a. Identify the following bone markings:

i. **Acromial end**

ii. **Sternal end**

iii. **Shaft**

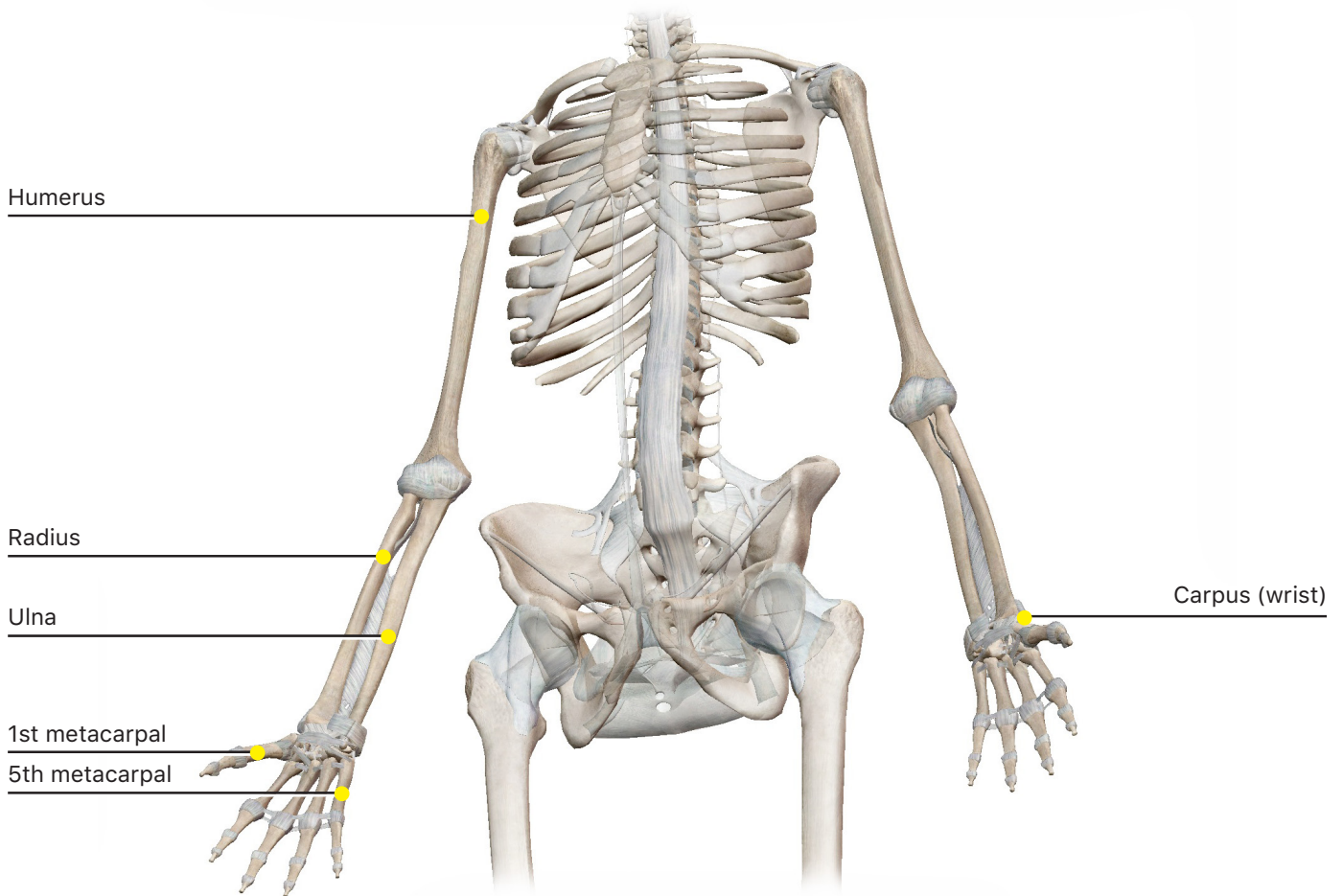
iv. **Conoid tubercle**

b. Describe how the clavicle curves and articulates with other bones.

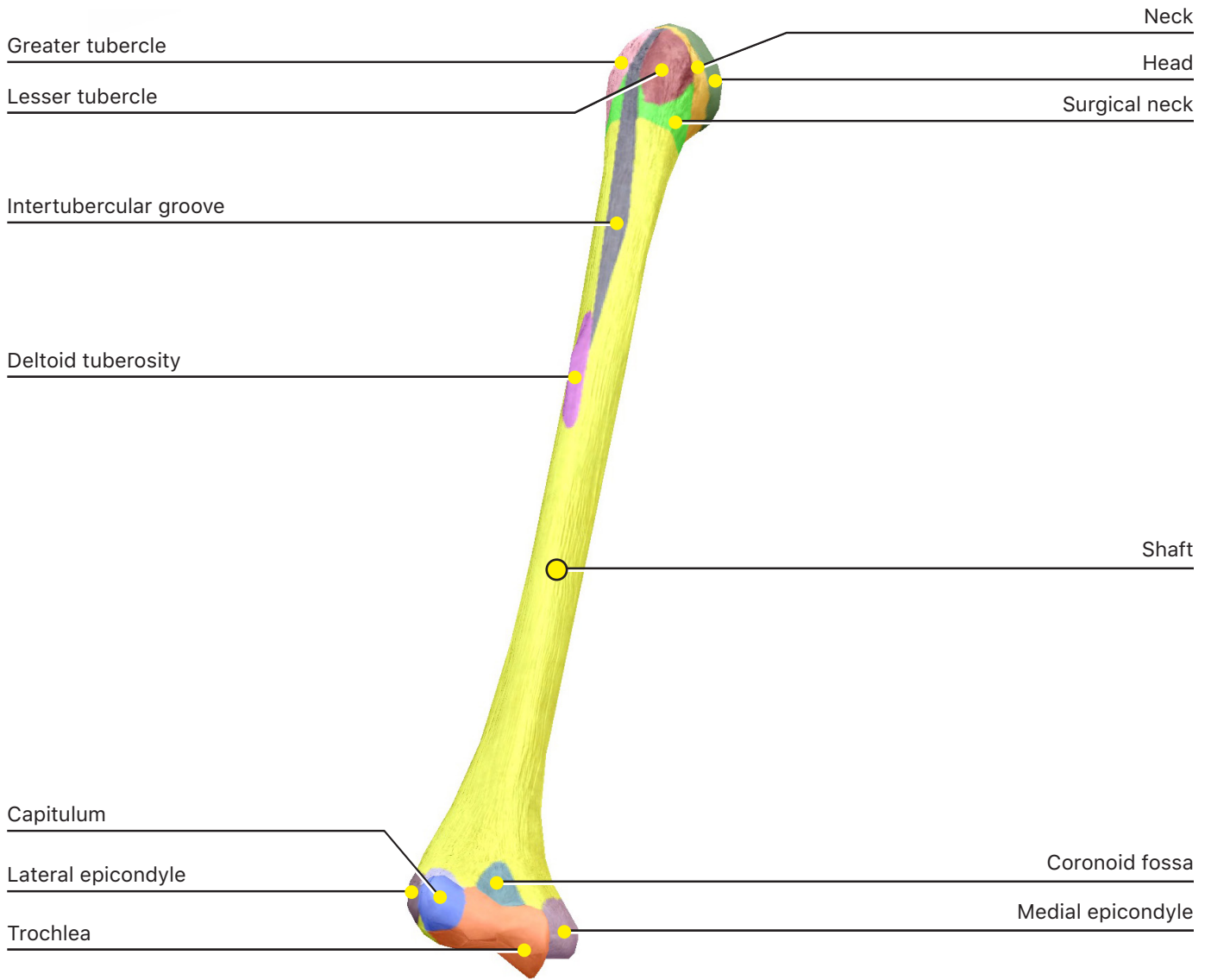
B. Upper Limb

The upper limb consists of the bones of the arm, forearm, wrist, and hand. View Module 11.6 Upper Limb to see where the bones of the upper limb are located. Identify the following bones and bone markings, and then go back to Module 11.6 and observe how the individual bones fit together. Note how processes often fit into the fossae of the same name.

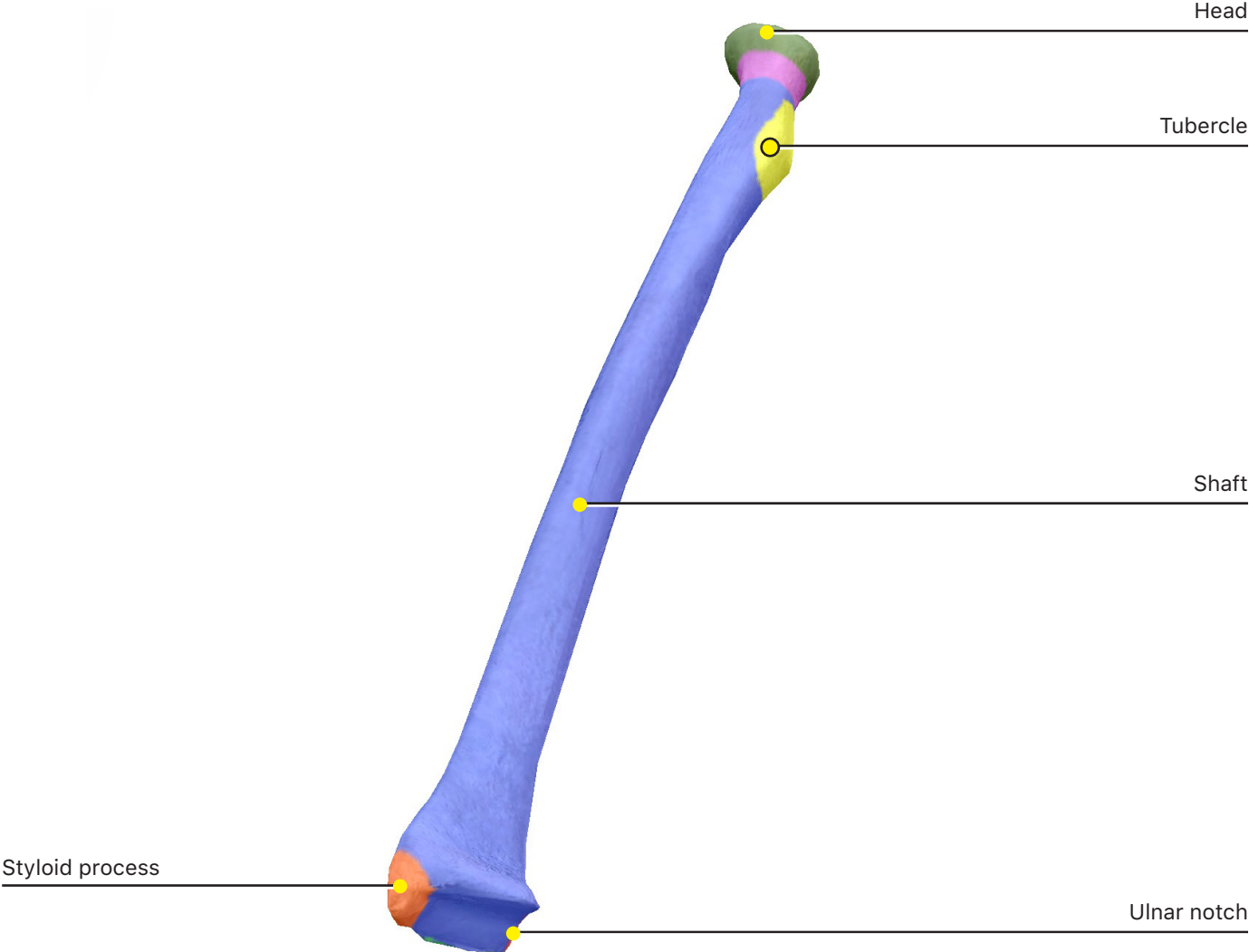
Module 11.6 Upper Limb



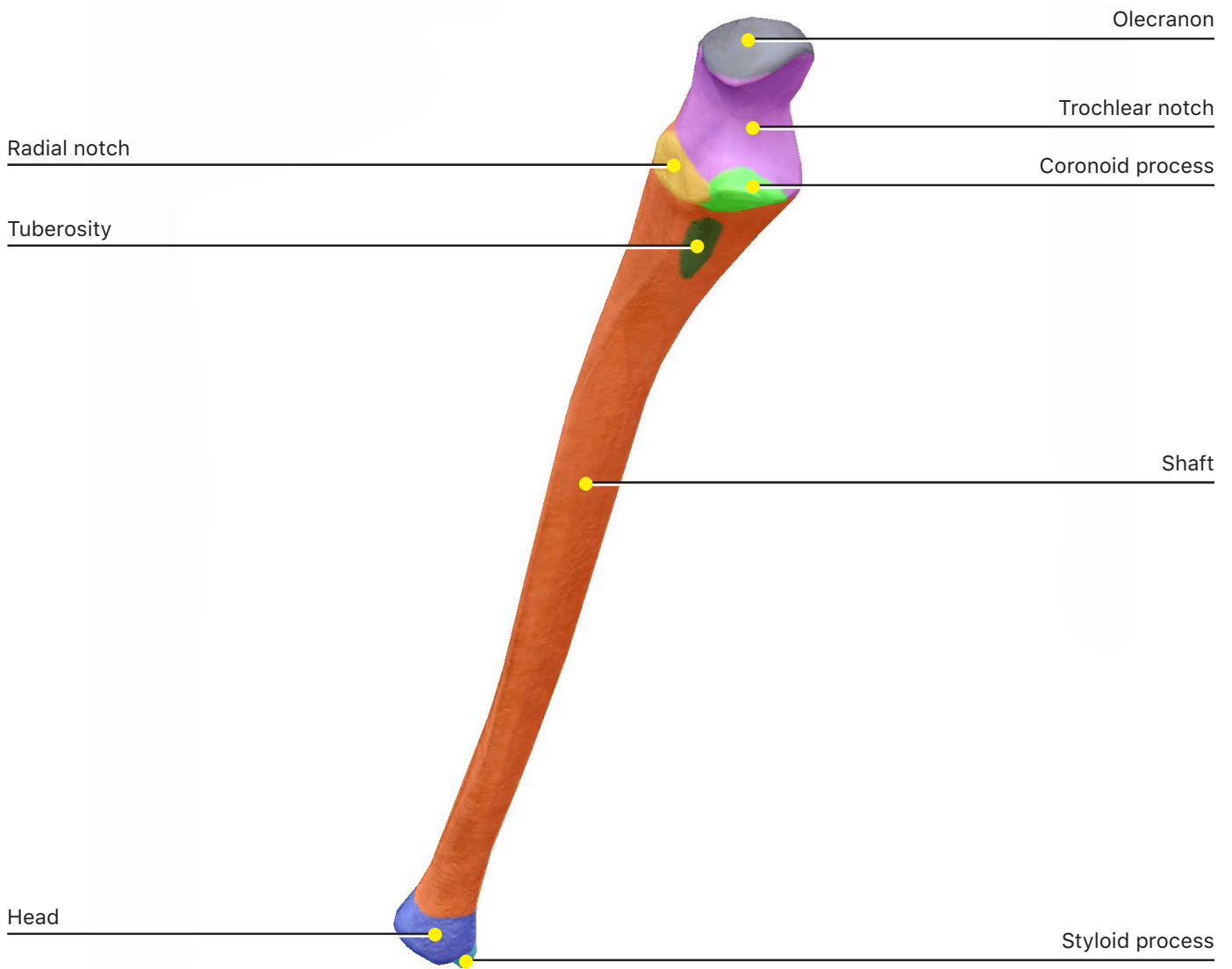
Module 11.8 Humerus Landmarks



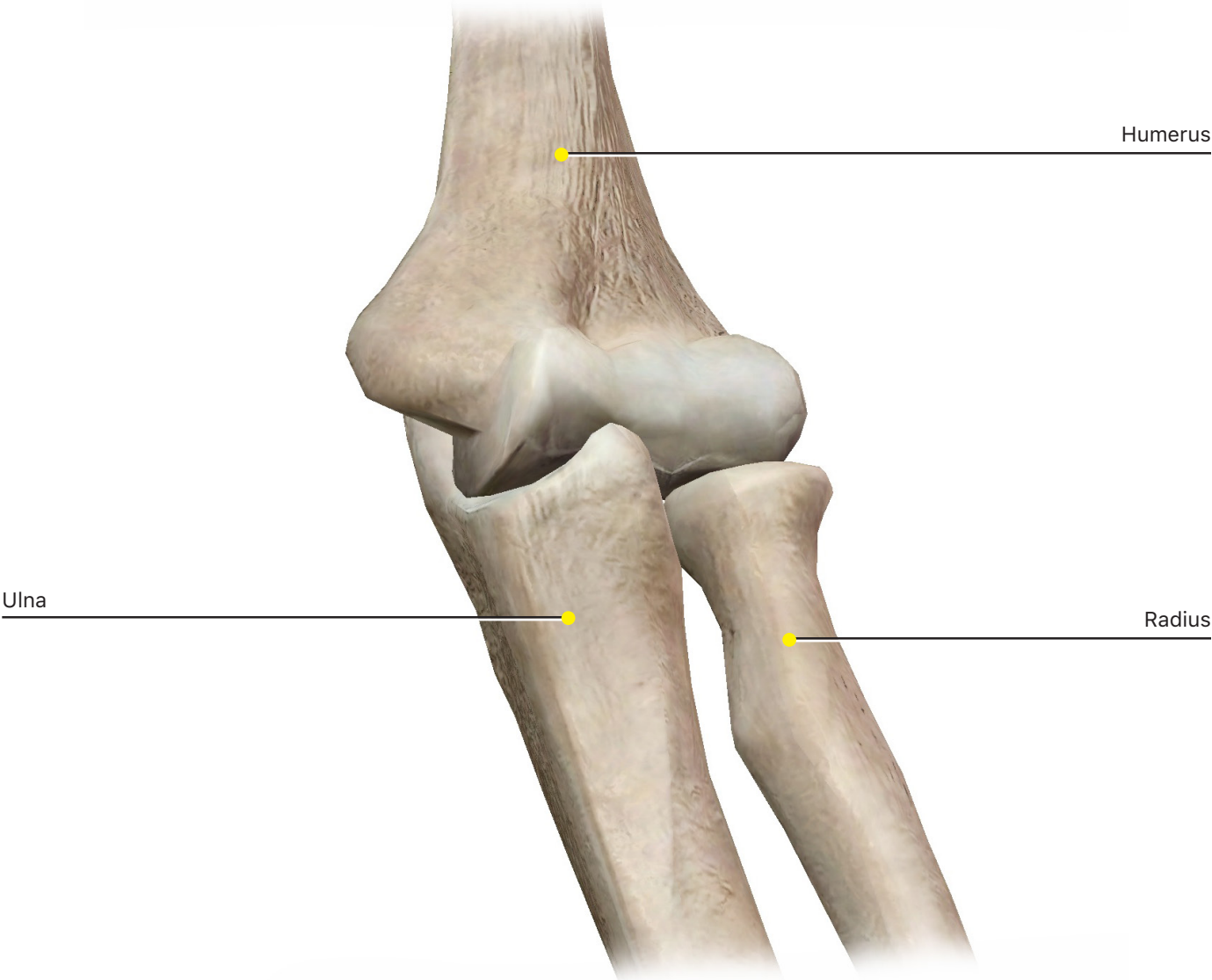
Module 11.9 Radius Landmarks



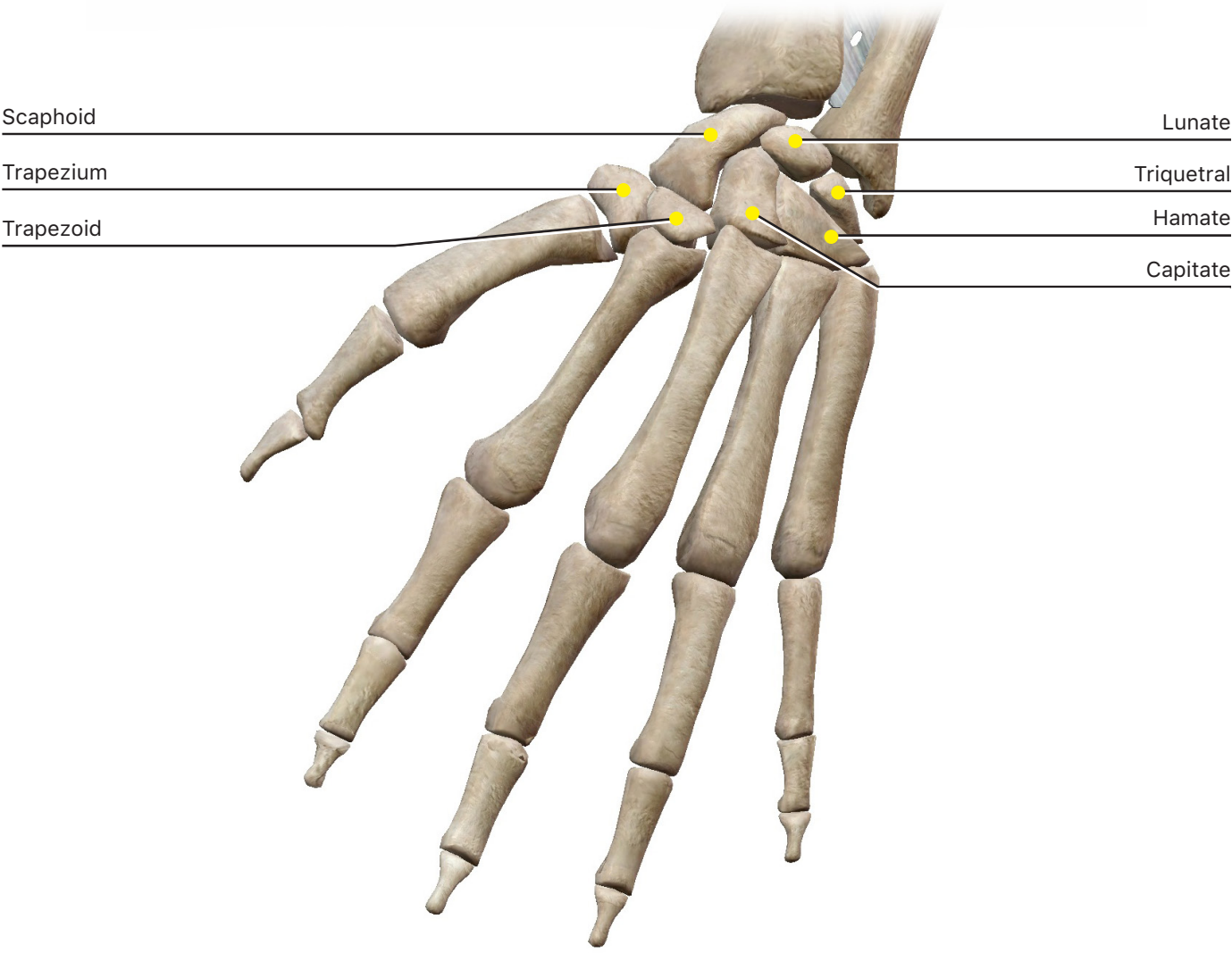
Module 11.10 Ulna Landmarks



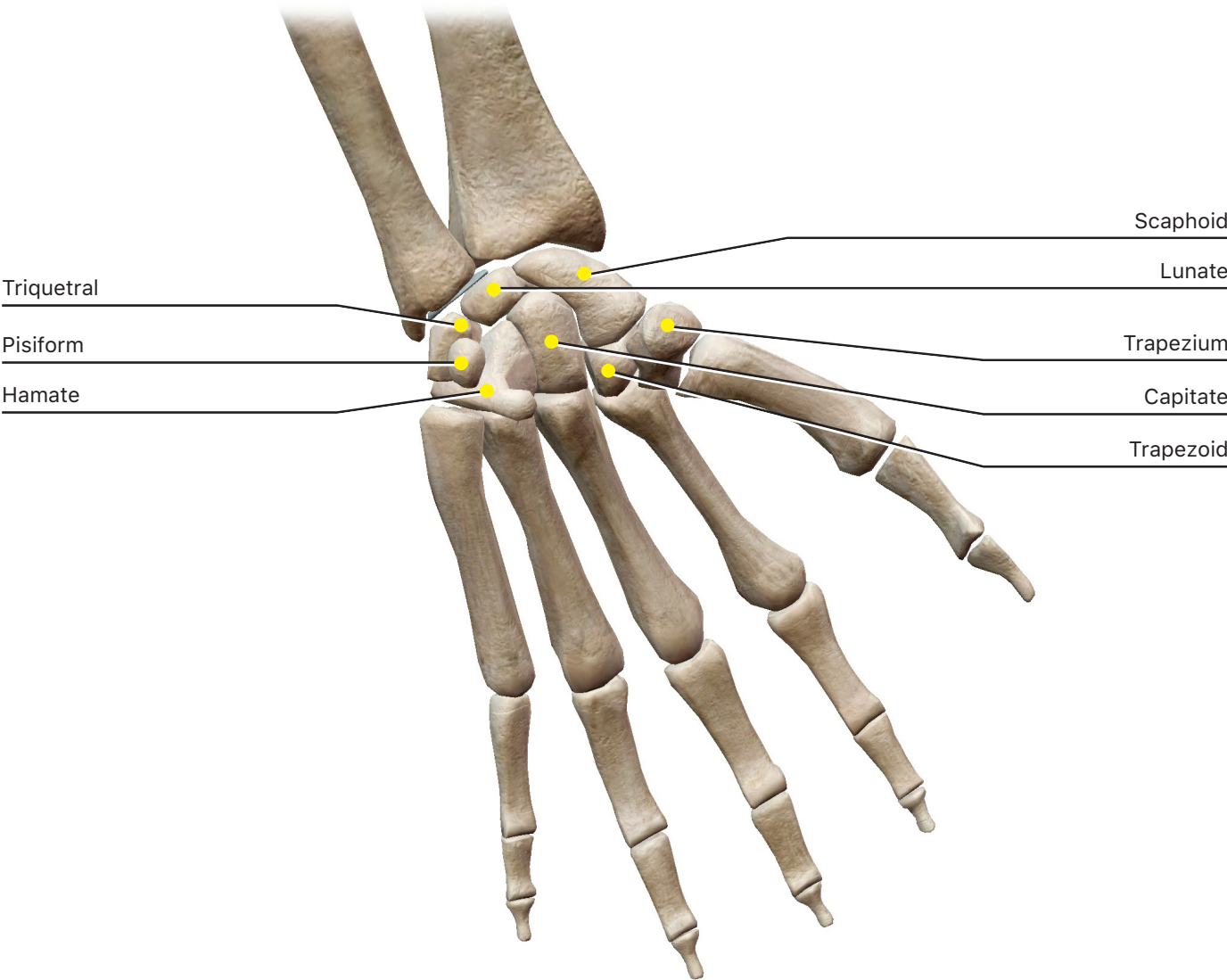
Module 11.11 Carpus (Wrist) I



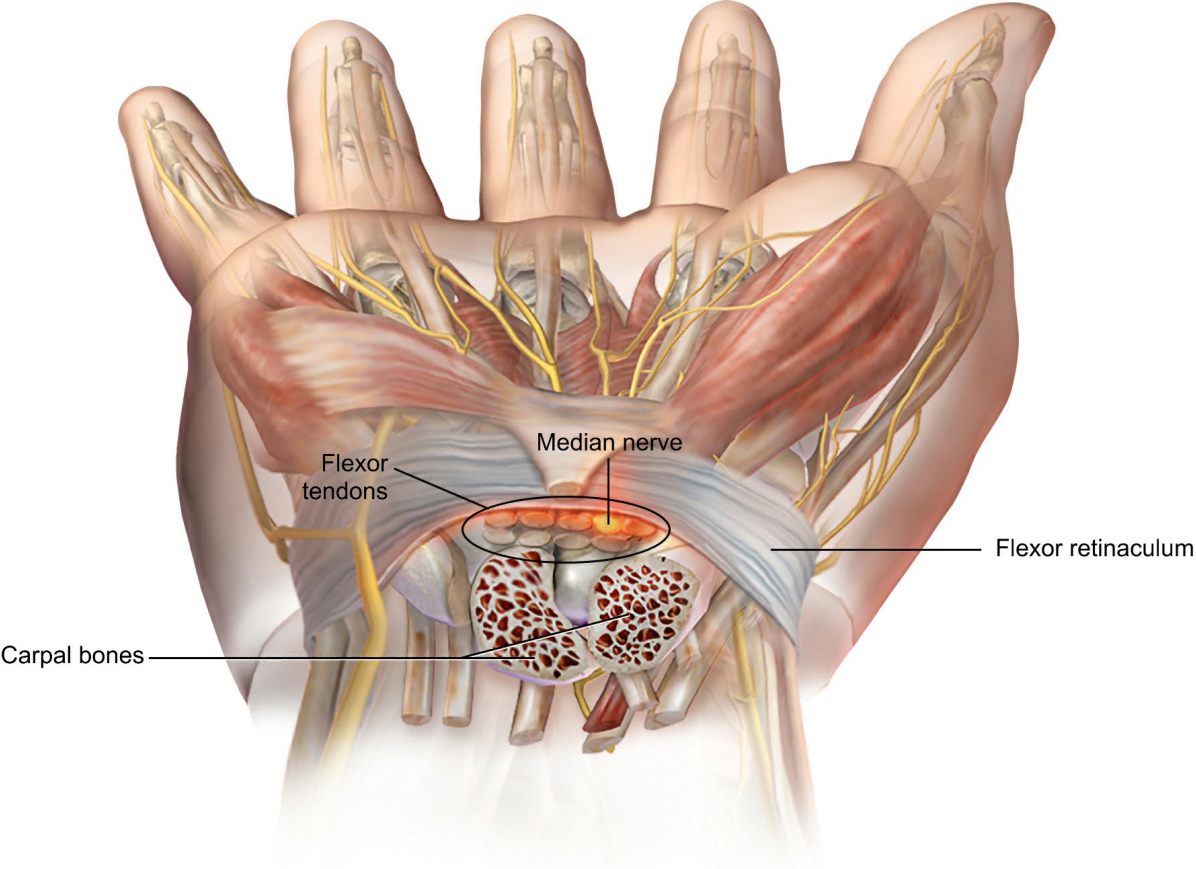
Module 11.12 Carpus (Wrist) II (Posterior)



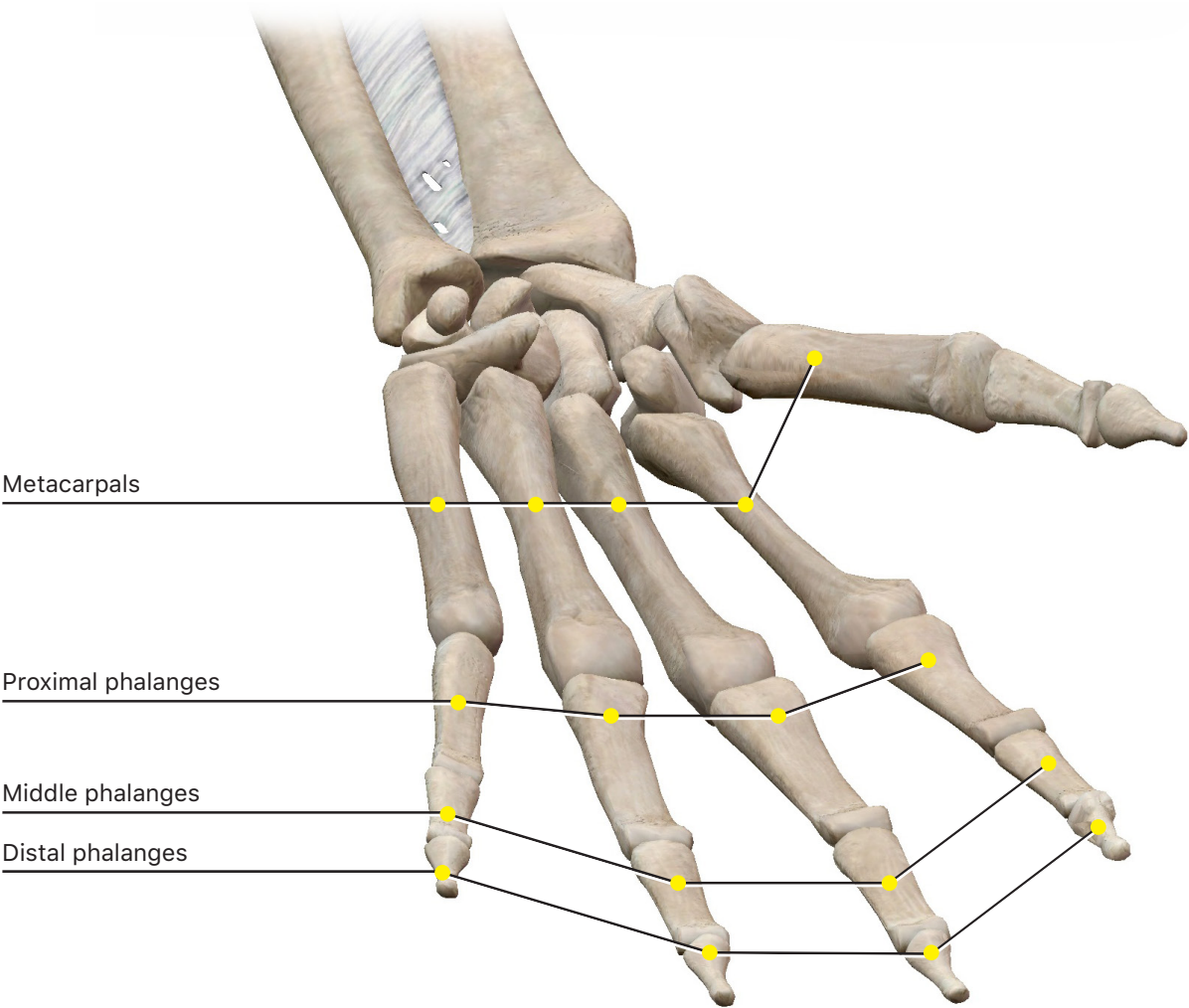
Module 11.12 Carpus (Wrist) II (Anterior)



Module 11.13 Carpal Tunnel



Module 11.14 Hand



1. **Humerus** (see Module 11.8 Humerus Landmarks)

a. Identify the following bone markings:

- i. **Head**
- ii. **Neck**
- iii. **Surgical neck**
- iv. **Shaft**
- v. **Greater tubercle**
- vi. **Lesser tubercle**
- vii. **Intertubercular groove**
- viii. **Radial groove**
- ix. **Deltoid tuberosity**
- x. **Trochlea**
- xi. **Capitulum**
- xii. **Coronoid fossa**
- xiii. **Olecranon fossa**
- xiv. **Medial epicondyle**
- xv. **Lateral epicondyle**
- xvi. **Radial fossa**

b. Describe the difference in position of the anatomical neck and the surgical neck.

2. **Radius** (see Module 11.9 Radius Landmarks)

a. Identify the following bone markings:

- i. **Head**
- ii. **Neck**
- iii. **Shaft**

- iv. **Tubercle**
- v. **Styloid process**
- vi. **Ulnar notch**

3. **Ulna** (see Module 11.10 Ulna Landmarks)

a. Identify the following bone markings:

- i. **Coronoid process**
- ii. **Olecranon**
- iii. **Radial notch**
- iv. **Trochlear notch**
- v. **Styloid process**
- vi. **Head**
- vii. **Shaft**

b. How do the bones of the radius and ulna attach to each other?

c. Describe how the radius and ulna attach to and rotate around the humerus when the elbow flexes.

4. **Carpus (Wrist)** (see Modules 11.11 Carpus (Wrist) I and 11.12 Carpus (Wrist) II)

a. Identify the following carpal bones:

- i. **Lunate**
- ii. **Scaphoid**
- iii. **Trapezium**
- iv. **Trapezoid**
- v. **Capitate**

vi. **Hamate**

vii. **Triquetral**

viii. **Pisiform**

b. After reviewing the carpal (wrist) bones, observe Module 11.13 Carpal Tunnel to see how a tunnel is formed inside the wrist and how carpal tunnel syndrome can result. Answer the following questions.

i. What structures form the tunnel?

ii. What events happen to cause carpal tunnel syndrome?

iii. Which nerve is compressed?

5. Hand (see Module 11.14 Hand)

Note the nomenclature for the bones of the hand. The thumb is considered digit I, while the pinky finger is digit V. The metacarpals and phalanges are numbered accordingly.

a. Identify the following hand bones:

i. **Metacarpals**

ii. **Proximal phalanges**

iii. **Middle phalanges**

iv. **Distal phalanges**

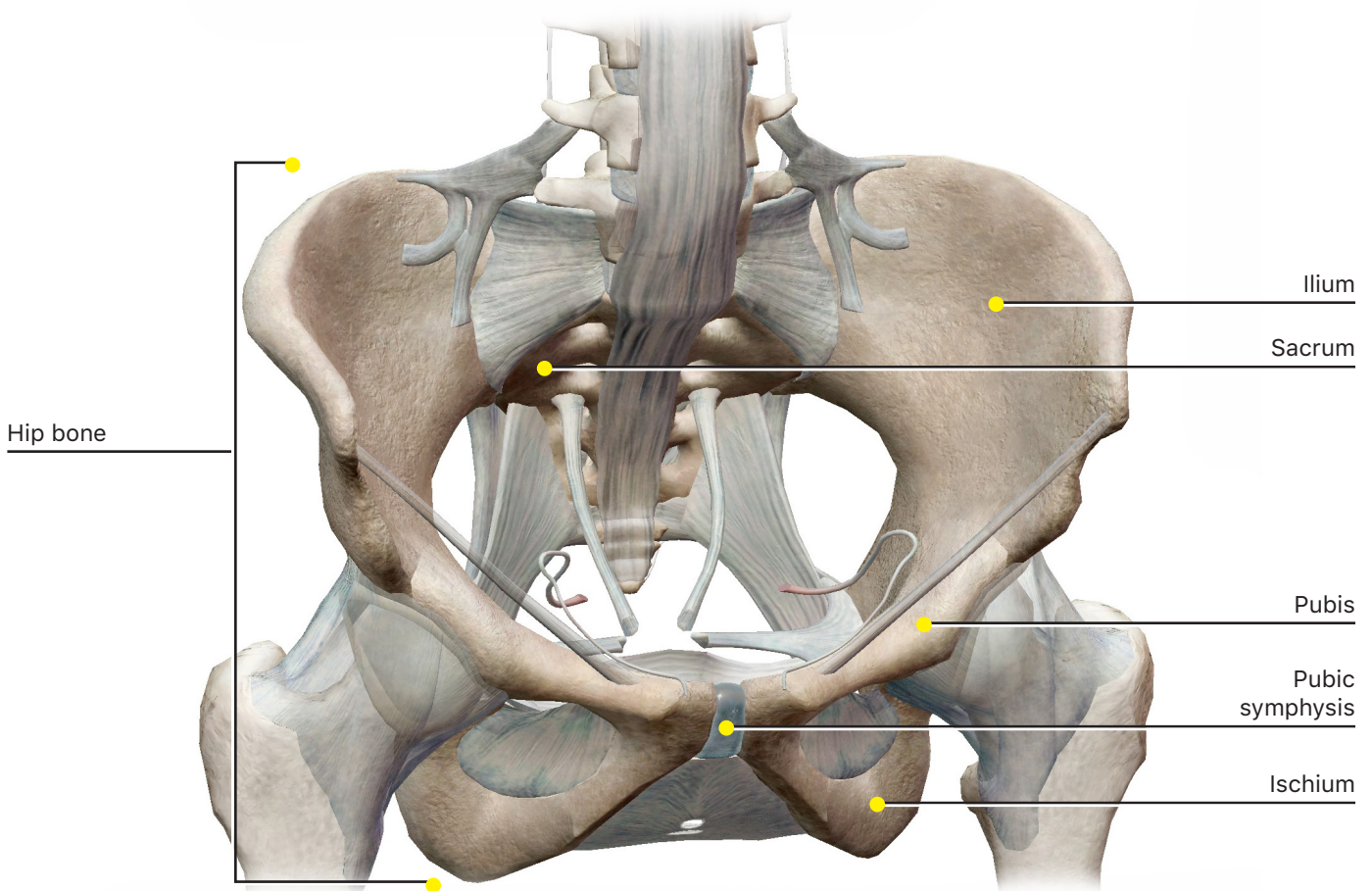
b. List all the bones in your hand on your thumb from proximal to distal. Do the same for your pinky finger. What is the difference?

C. Pelvic Girdle

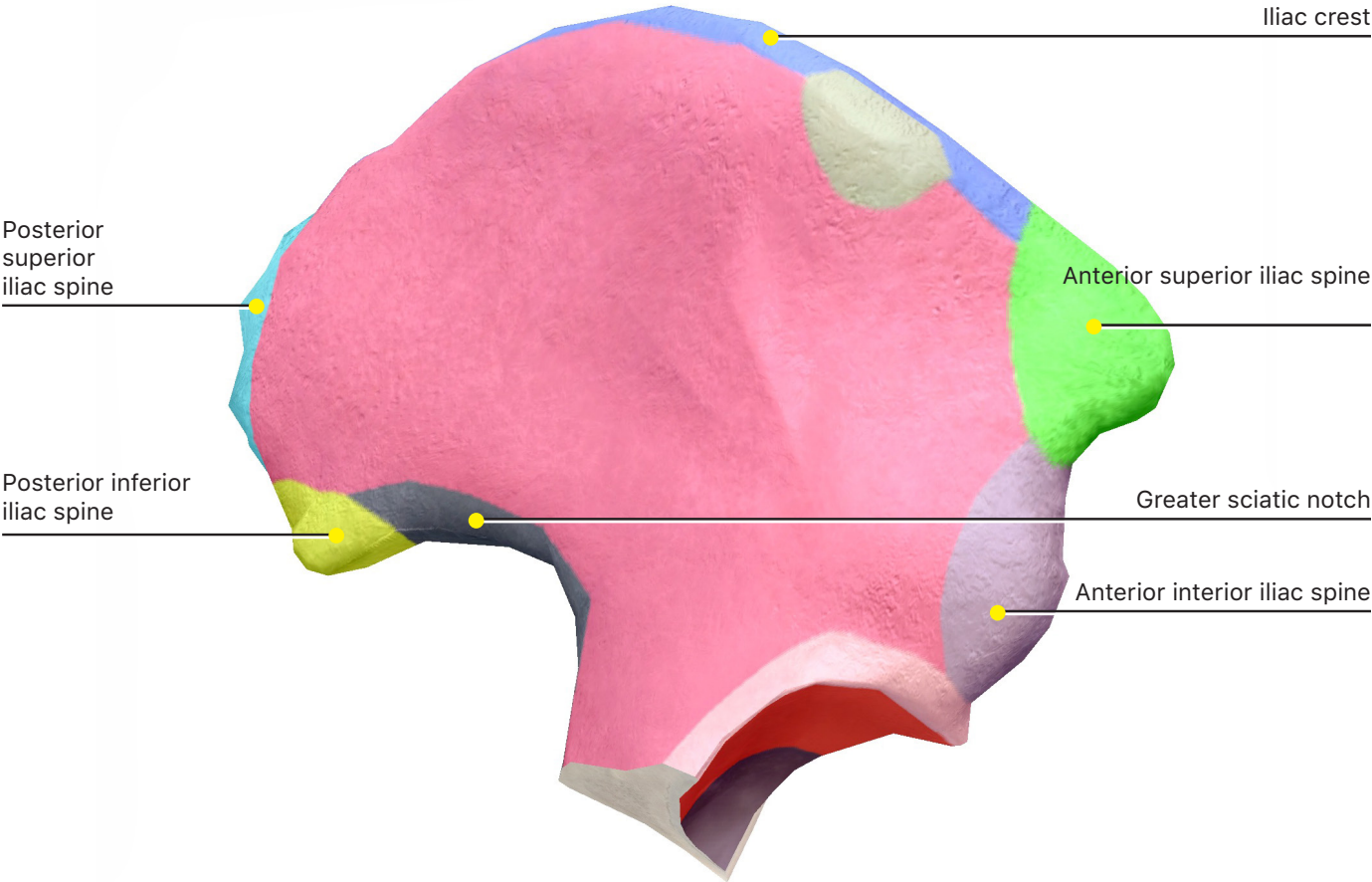
Just like the pectoral girdle attaches the upper limbs to the skeleton, the pelvic girdle attaches the lower limbs to the skeleton. The pelvic girdle consists of the right and left **hip bones** and the **sacrum** that connects the hip bones on the posterior side. You may remember the sacrum from studying the axial skeleton, because it is part of the vertebral column. Each of the hip bones begins as three separate bones: the **ilium**, **ischium**, and **pubis**. These bones eventually fuse together, but bone markings are still considered to belong to one of these three distinct regions.

Observe the different regions of the hip bone in Module 11.15 Pelvic (Hip) Girdle. Come back to this module after you've looked at the individual hip bones and try to find the same landmarks on the whole hip bone.

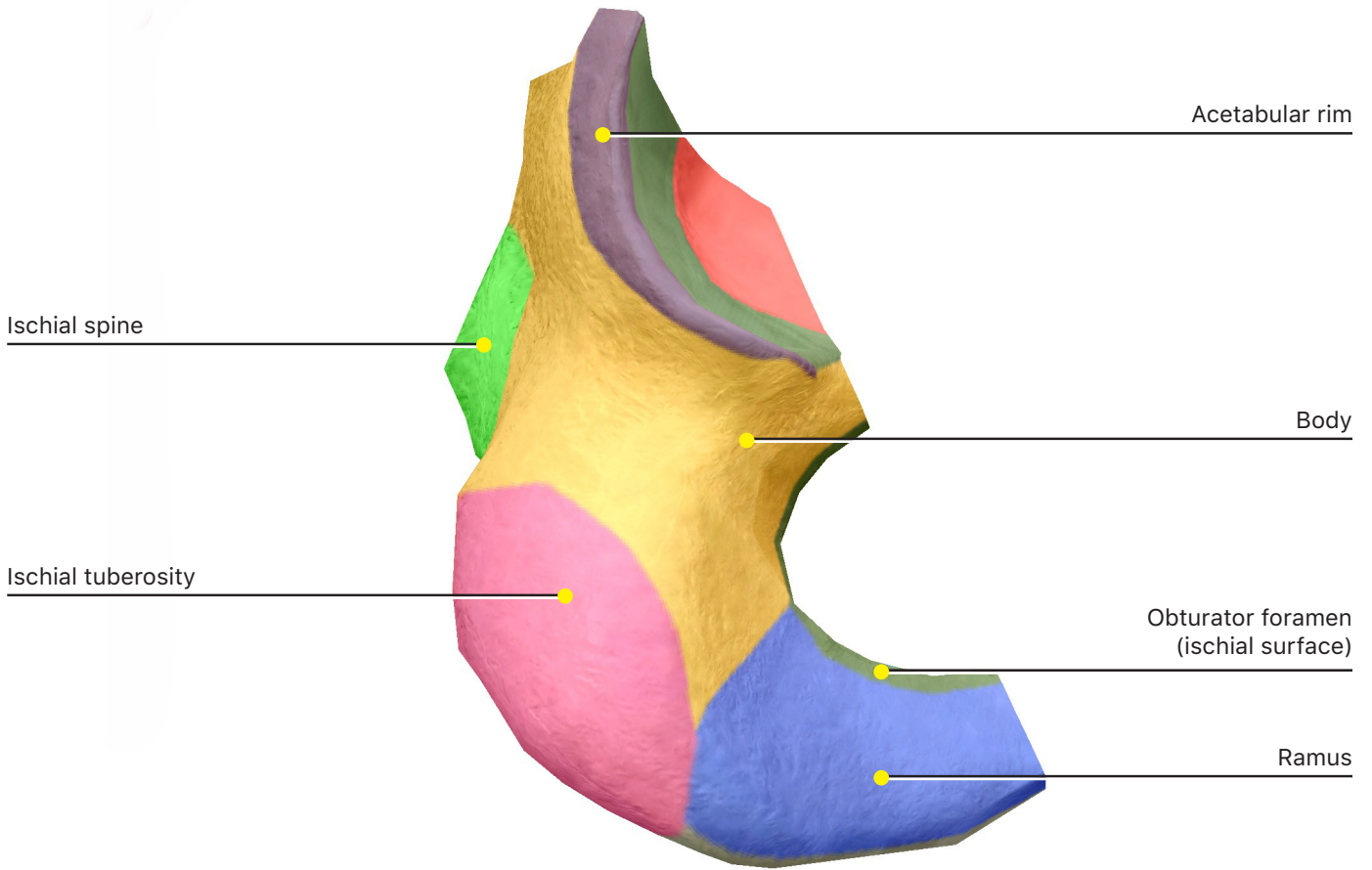
Module 11.15 Pelvic (Hip) Girdle



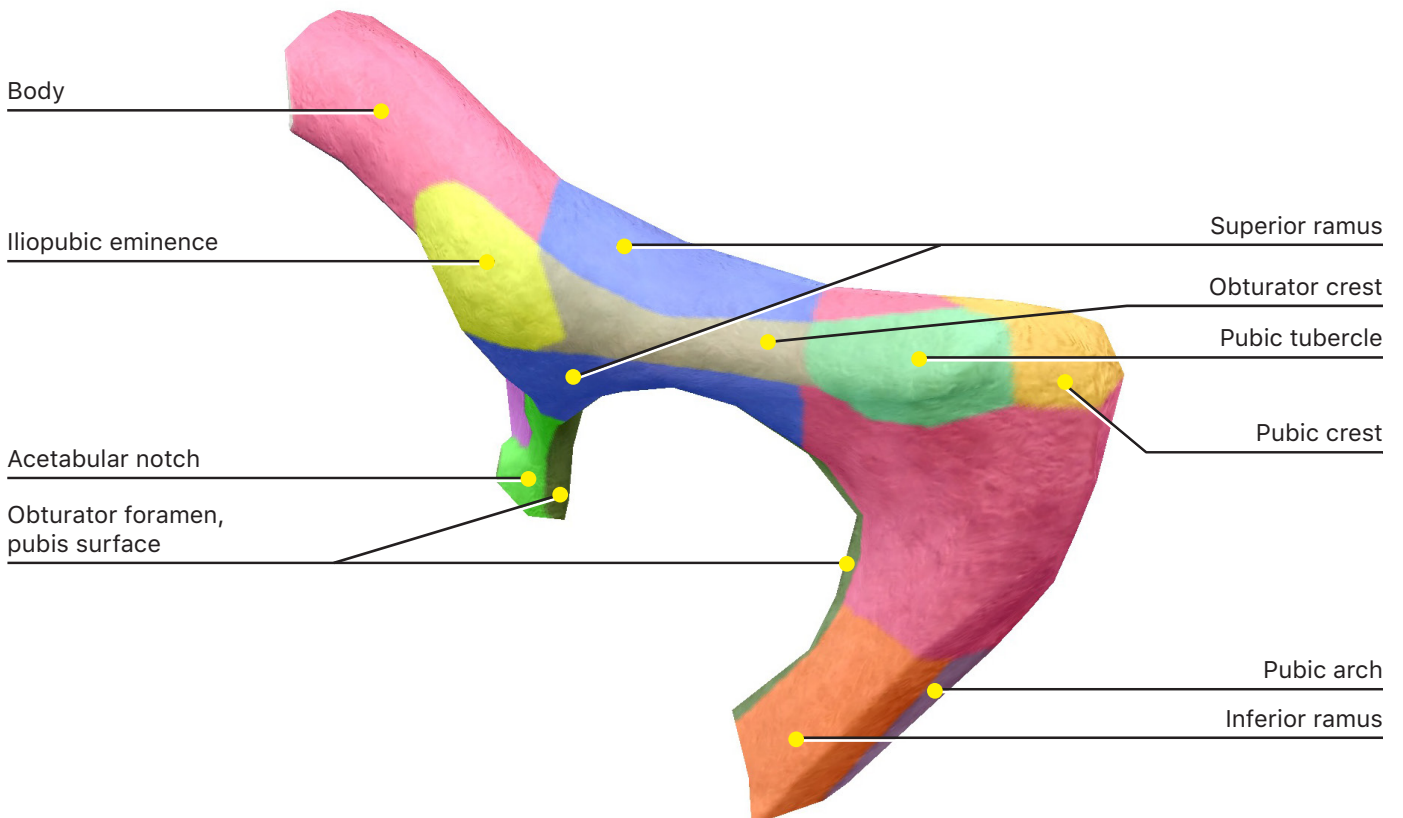
Module 11.16 Ilium Landmarks



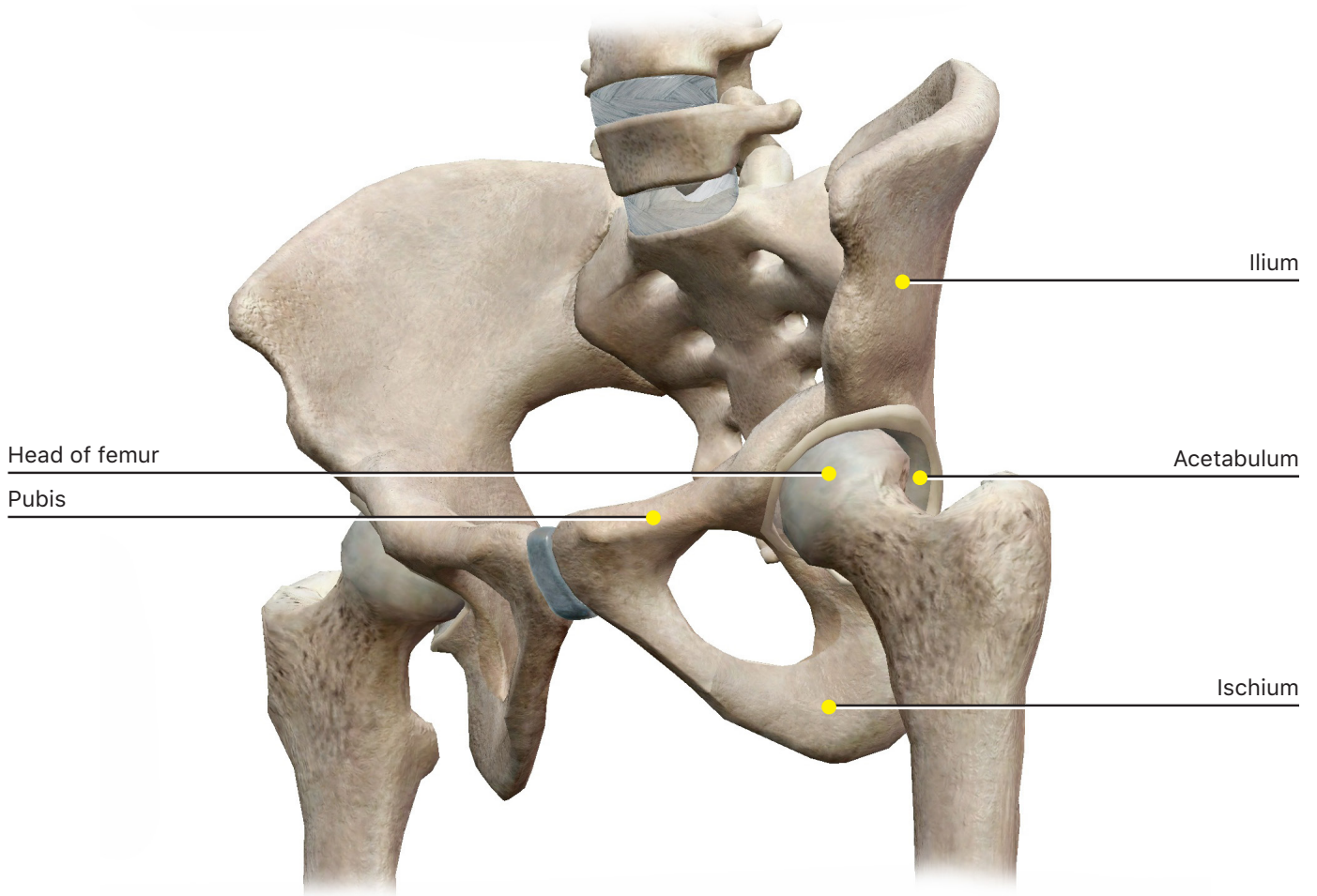
Module 11.17 Ischium Landmarks



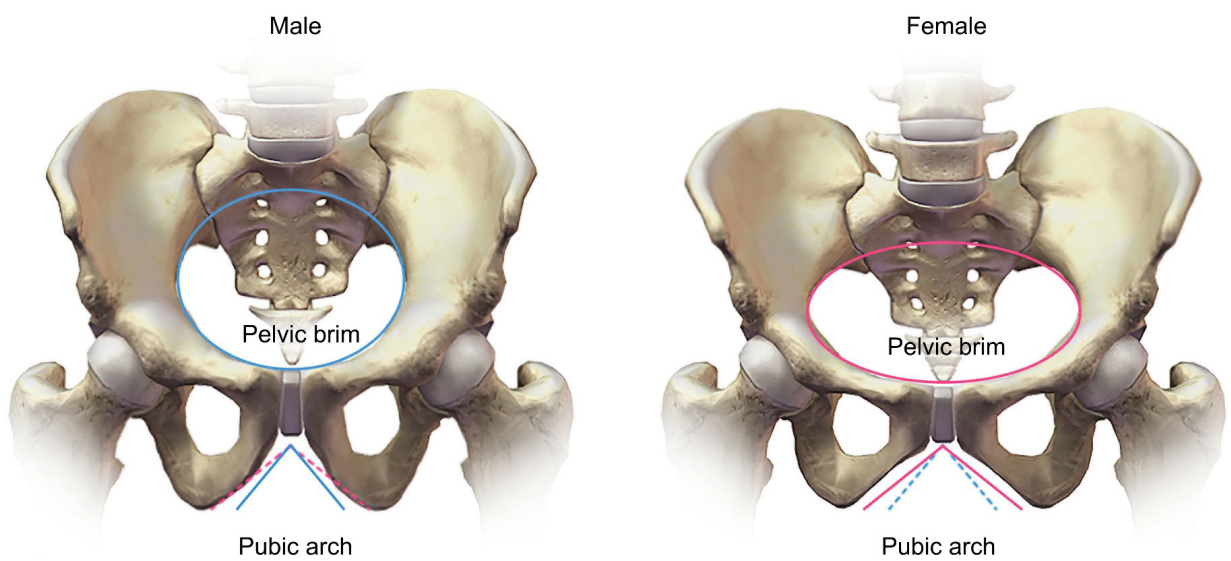
Module 11.18 Pubis Landmarks



Module 11.15 Pelvic (Hip) Girdle



Module 11.19 Male and Female Pelvis



1. Ilium (see Module 11.16 Ilium Landmarks)

a. Identify the following bone markings:

- i. **Body**
- ii. **Iliac crest**
- iii. **Iliac fossa**
- iv. **Acetabulum**
- v. **Anterior inferior iliac spine**
- vi. **Anterior superior iliac spine**
- vii. **Posterior inferior iliac spine**
- viii. **Posterior superior iliac spine**
- ix. **Auricular surface**
- x. **Greater sciatic notch**

2. Ischium (see Module 11.17 Ischium Landmarks)

a. Identify the following bone markings:

- i. **Body**
- ii. **Ramus**
- iii. **Acetabulum**
- iv. **Lesser sciatic notch**
- v. **Ischial tuberosity**
- vi. **Ischial spine**
- vii. **Pubic arch**
- viii. **Obturator foramen (ischial surface)**

3. Pubis (see Module 11.18 Pubis Landmarks)

a. Identify the following bone markings:

- i. **Body**
- ii. **Acetabulum**

- iii. **Superior ramus**
- iv. **Inferior ramus**
- v. **Pubic arch**
- vi. **Pubic crest**
- vii. **Pubic tubercle**
- viii. **Obturator crest**
- ix. **Obturator foramen (pubis surface)**

4. Where does the lower limb attach to the hip bone? Which part of the hip bone is this?

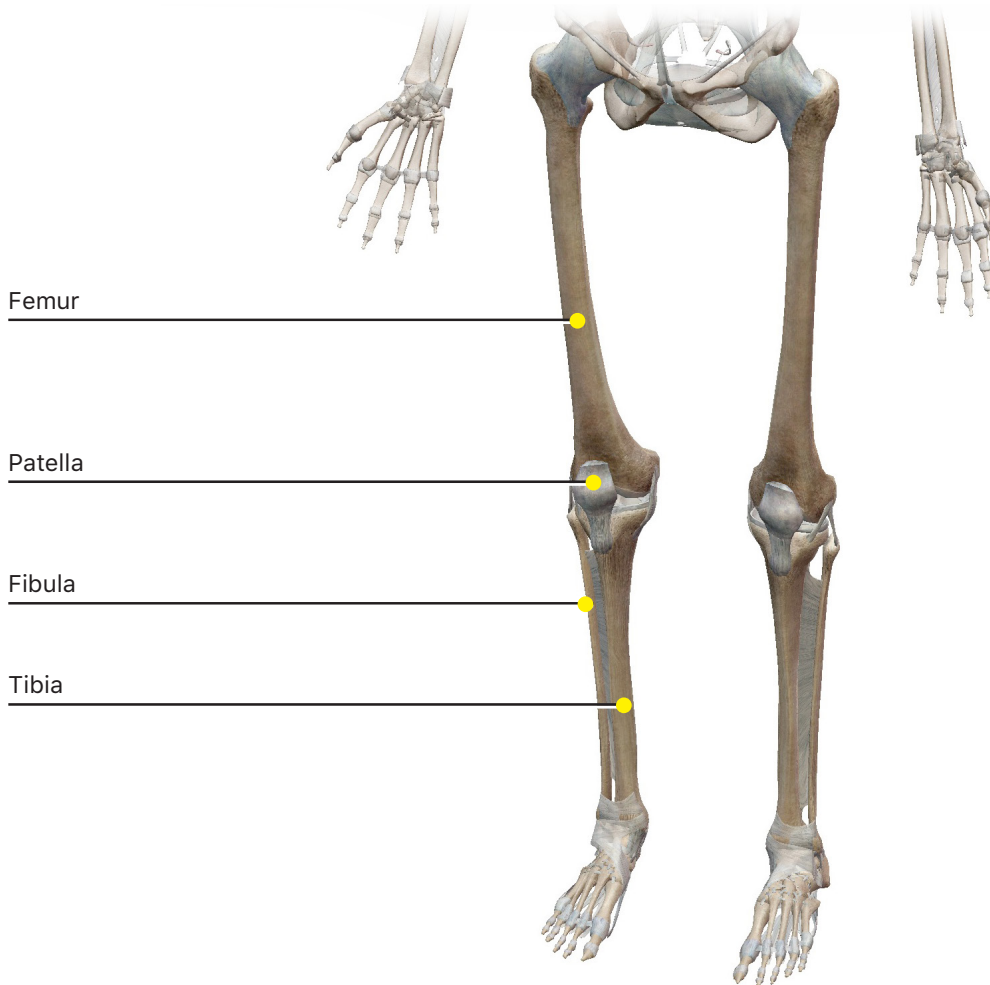
5. The male and female pelvises have a few differences due to childbearing adaptations. Observe the pelvises in Module 11.19 Male and Female Pelvis and answer the following questions.

- a. Describe what the pelvic brim is.
- b. How is the pelvic brim different in males vs. females?
- c. Describe what the pubic arch is.
- d. How is the pubic arch different in males vs. females?

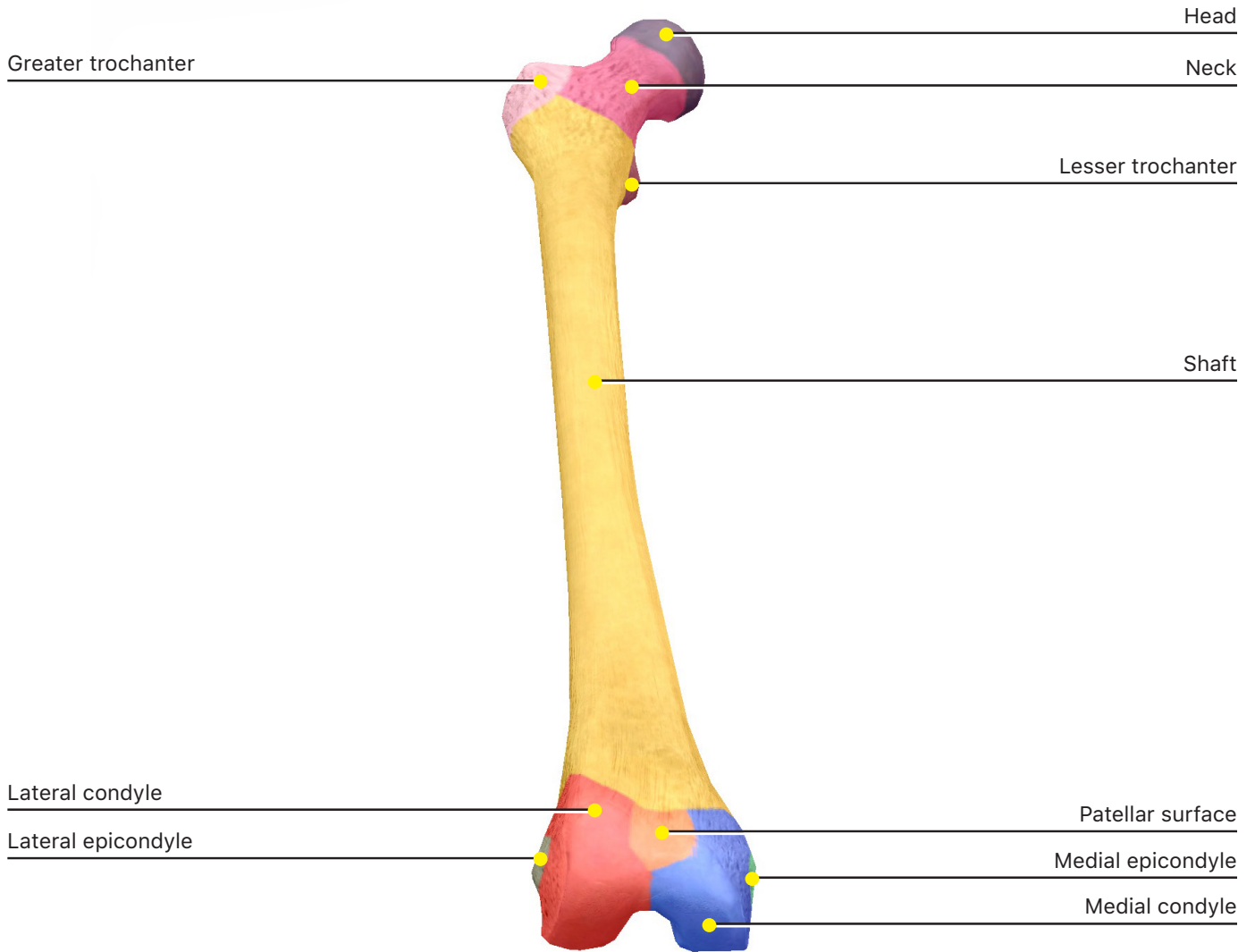
D. Lower Limb

View Module 11.20 Lower Limb to see the bones that compose the lower limb. In addition to their importance in movement, they support the weight of the rest of the body. As a result, they are generally larger and heavier than the bones of the upper limb.

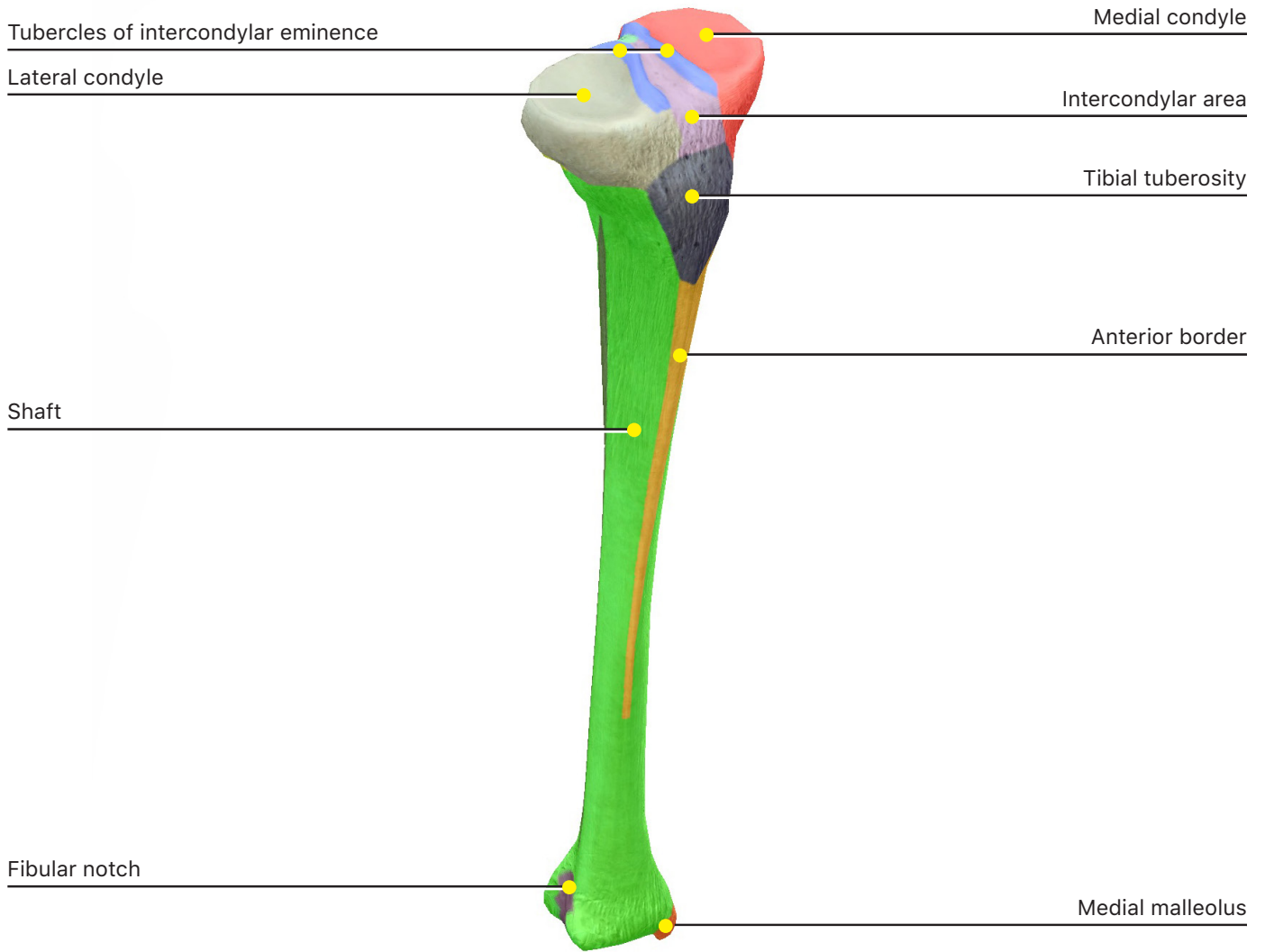
Module 11.20 Lower Limb



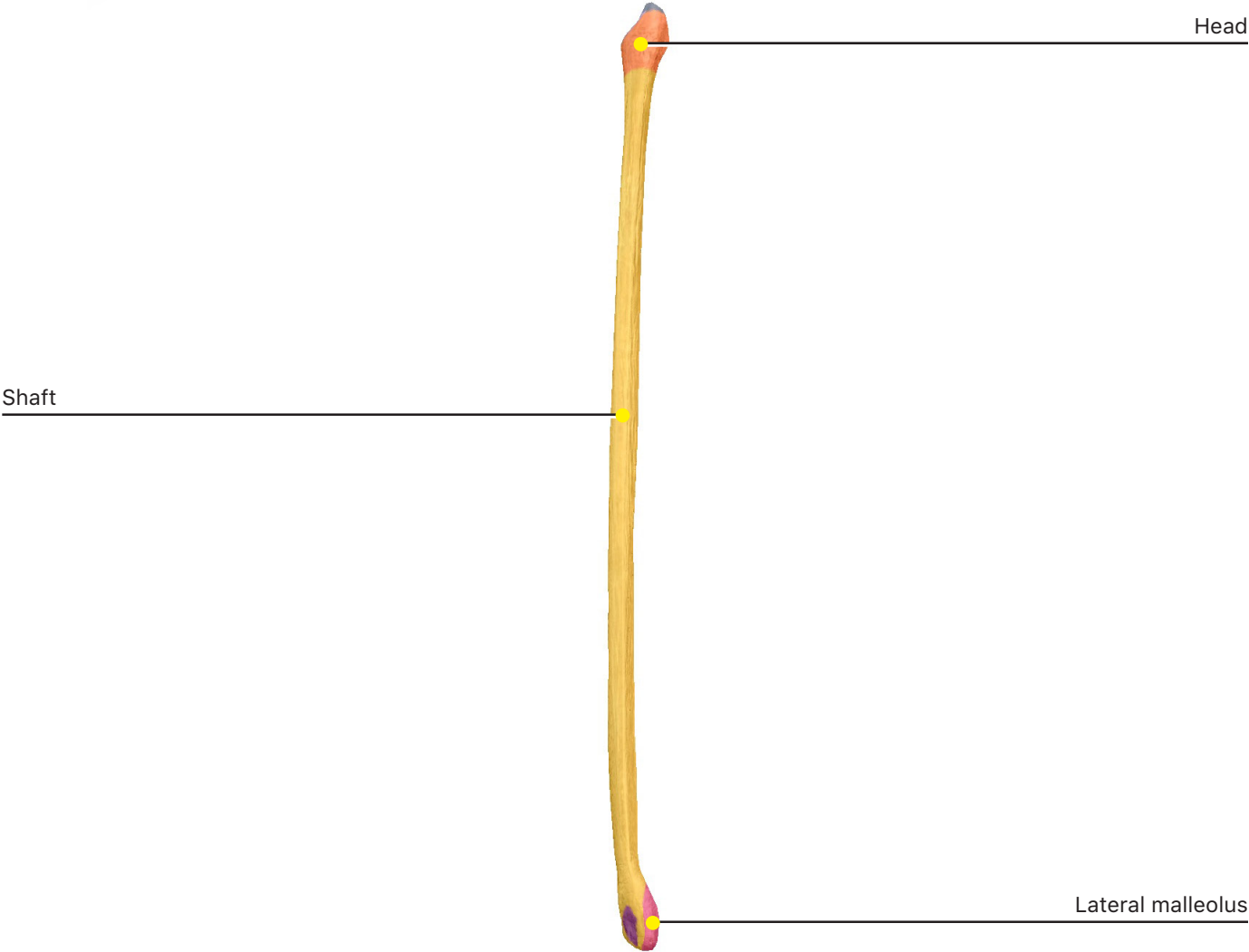
Module 11.22 Femur Landmarks



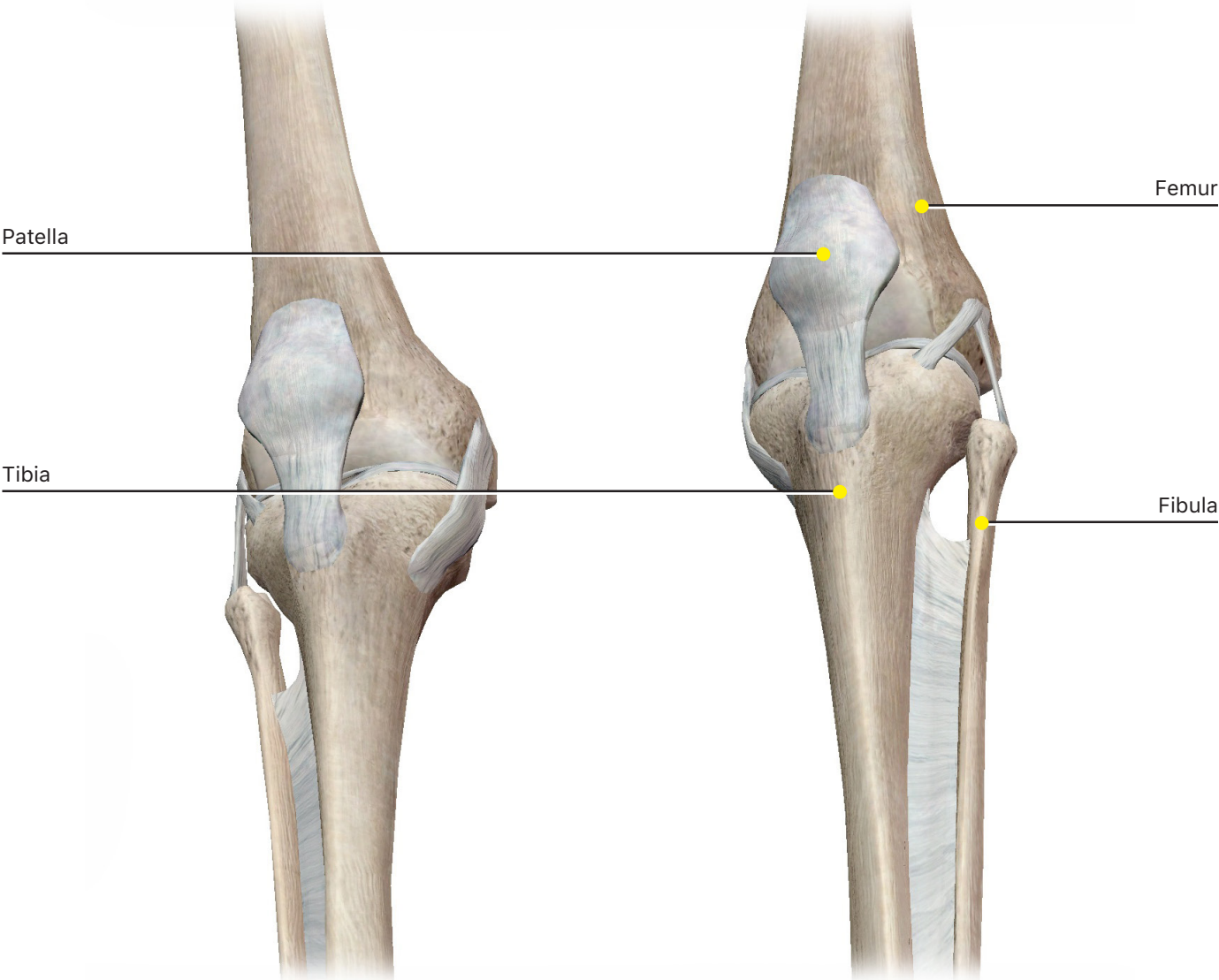
Module 11.23 Tibia Landmarks



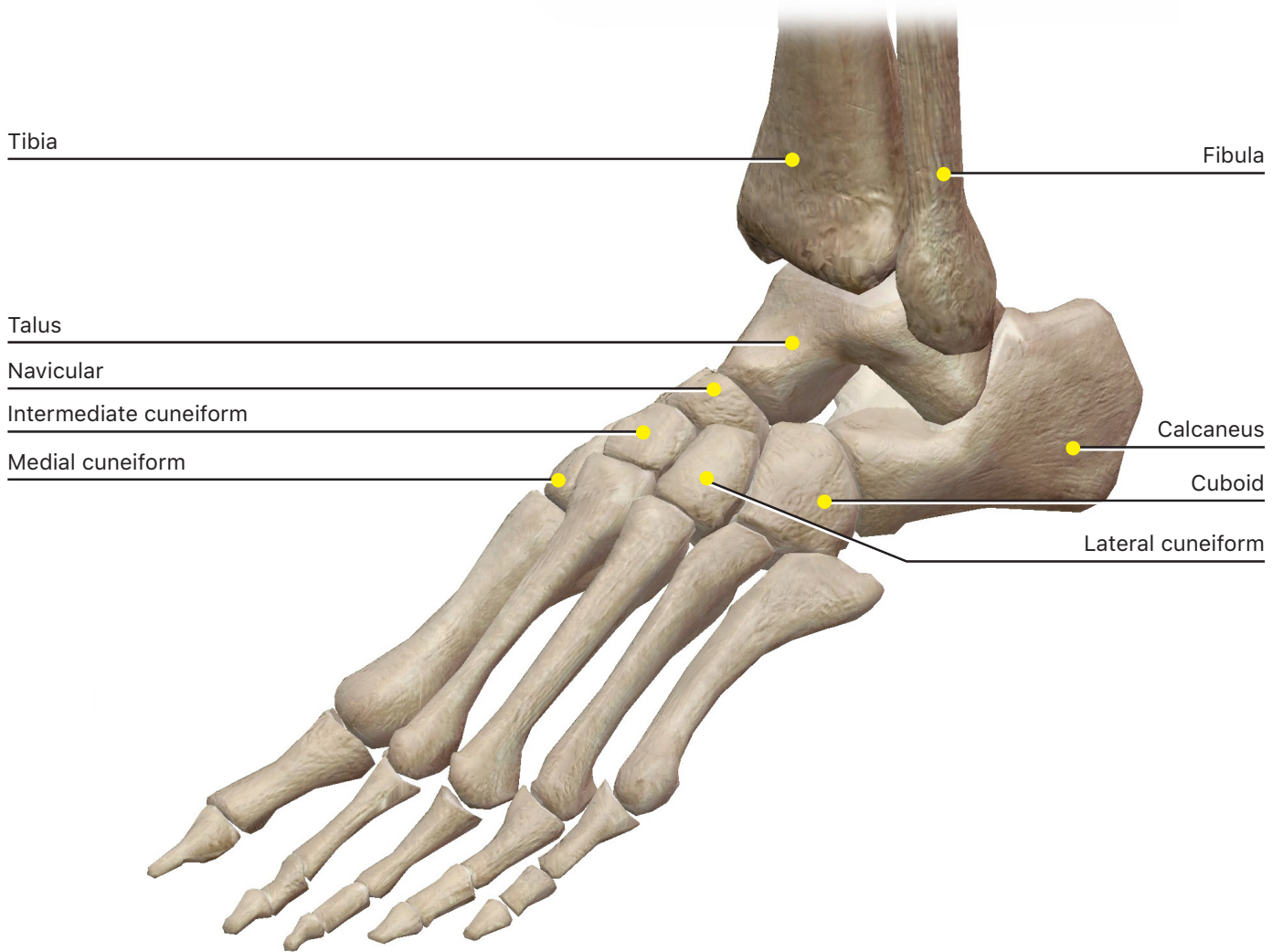
Module 11.24 Fibula Landmarks



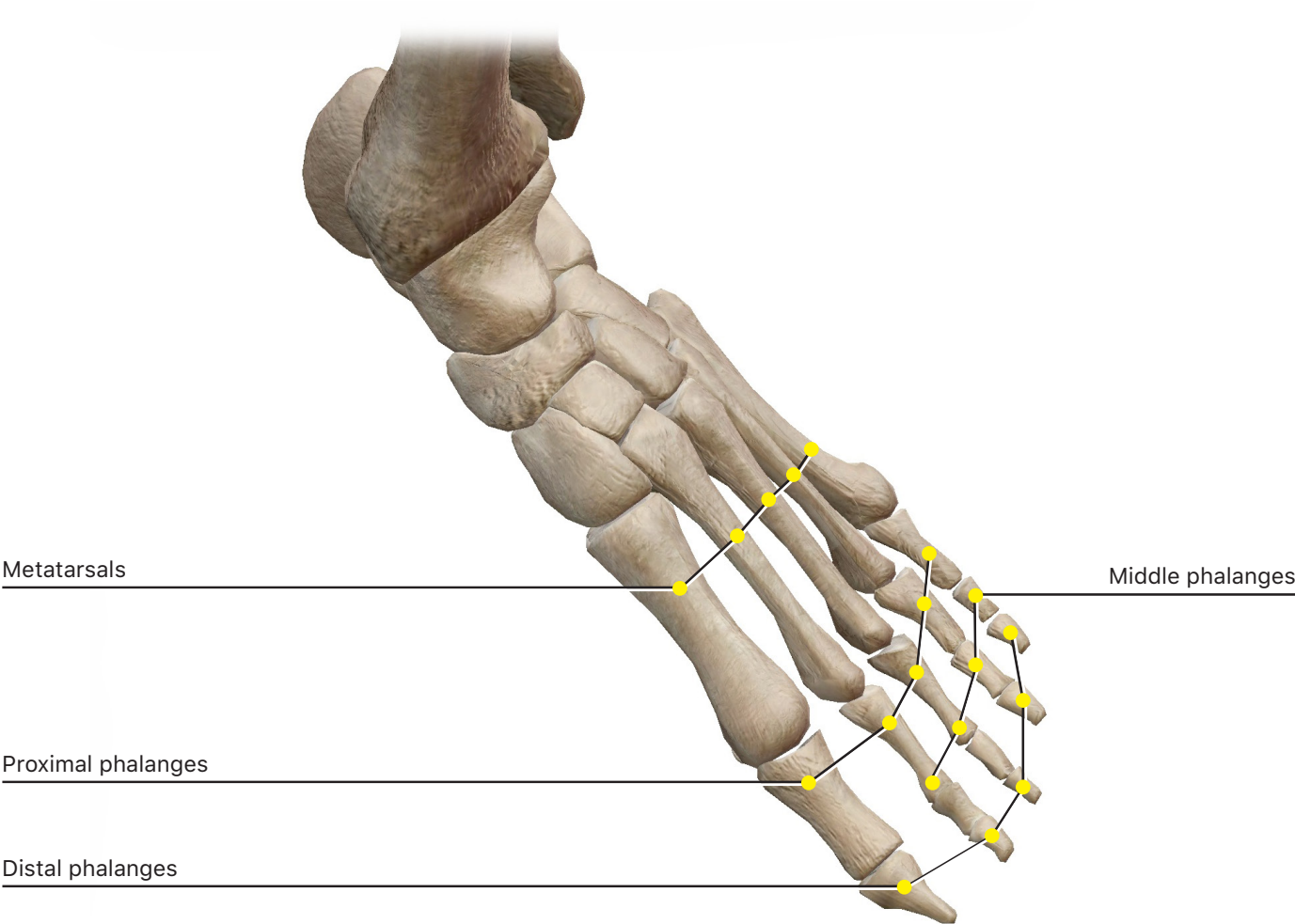
Module 11.21 Thigh and Leg



Module 11.25 Tarsus



Module 11.27 Foot



1. **Femur** (see Module 11.22 Femur Landmarks)

a. Identify the following bone markings:

- i. **Head**
- ii. **Shaft**
- iii. **Greater trochanter**
- iv. **Lesser trochanter**
- v. **Neck**
- vi. **Lateral condyle**
- vii. **Lateral epicondyle**
- viii. **Medial condyle**
- ix. **Medial epicondyle**
- x. **Intercondylar fossa**
- xi. **Gluteal tuberosity**
- xii. **Linea aspera**
- xiii. **Patellar surface**
- xiv. **Popliteal surface**

b. Describe how you would differentiate between a right femur and a left femur.

2. **Tibia** (see Module 11.23 Tibia Landmarks)

a. Identify the following bone markings:

- i. **Shaft**
- ii. **Medial condyle**
- iii. **Lateral condyle**
- iv. **Intercondylar area**
- v. **Tibial tuberosity**

vi. **Anterior border**

vii. **Medial malleolus**

3. **Fibula** (see Module 11.24 Fibula Landmarks)

a. Identify the following bone markings:

i. **Head**

ii. **Shaft**

iii. **Lateral malleolus**

4. **Patella**

a. Which bones compose the knee joint?

b. Where do the different bones attach to each other?

5. **Tarsus** (see Module 11.25 Tarsus)

a. Identify the following tarsal bones:

i. **Calcaneus**

ii. **Talus**

iii. **Medial cuneiform**

iv. **Intermediate cuneiform**

v. **Lateral cuneiform**

vi. **Cuboid**

vii. **Navicular**

b. Which bone forms the heel of the foot?

6. **Foot** (see Module 11.27 Foot)

Note that the nomenclature for the toes is the same as for the hand. The big toe is considered digit I, and the pinky toe is digit V.

a. Identify the following foot bones:

i. **Metatarsals**

ii. **Proximal Phalanges**

iii. **Middle Phalanges**

iv. **Distal Phalanges**

7. **Observe Module 11.26 Foot Arches and answer the following questions.**

a. What are the functions of the foot arches?

b. What are the names of the arches?

PUTTING IT ALL TOGETHER

1. What is the significance of an epiphyseal growth plate that is composed of bone versus one that is composed of cartilage?

2. How is the shape of the glenoid cavity of the scapula different from that of the acetabulum in the hip bone? How do the shapes of these bone markings affect the range of motion at their respective joints?

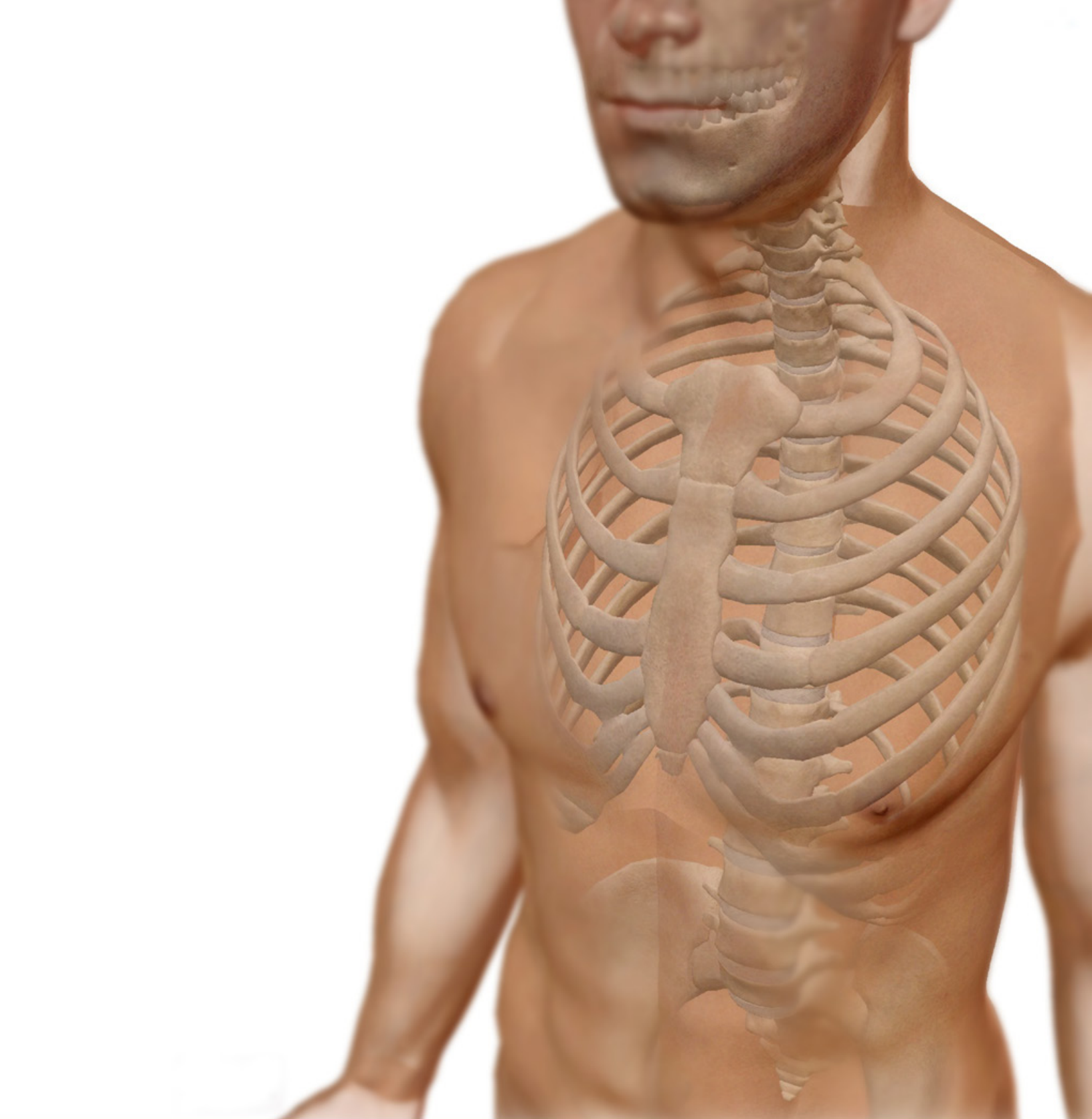3. How do the distinct characteristics of the female pelvis make childbirth easier?

4. Which bone markings are responsible for making the protrusions of the ankles, just above the feet?

5. When someone falls with an outstretched arm, a broken clavicle often results. Physically, how would that person appear afterward? What is the function of the clavicle?

TIME TO PRACTICE!

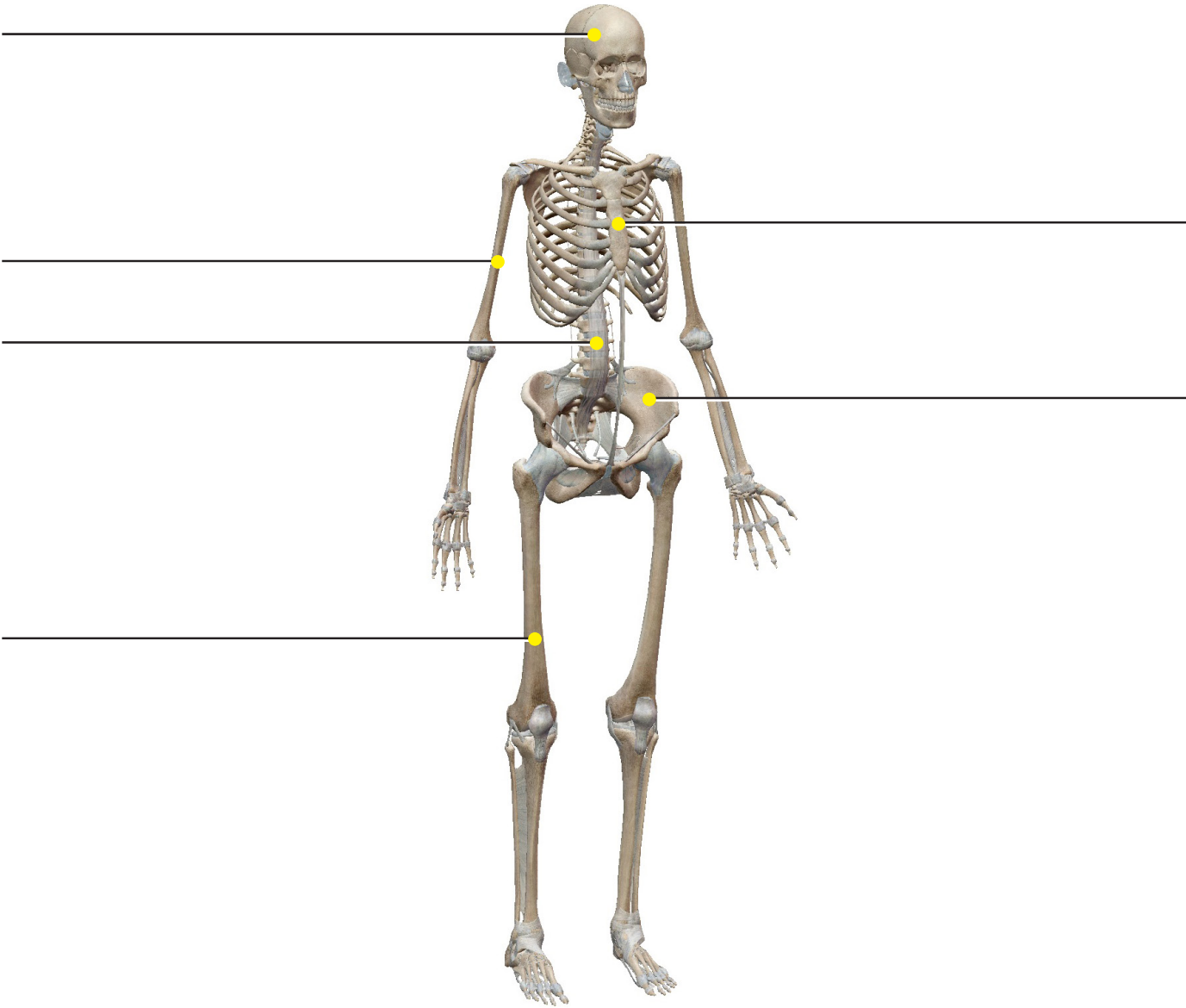
[GO TO THE QUIZZES MENU AND COMPLETE SKELETAL SYSTEM QUIZZES 8.A, 9.A, 11.A, AND 11.B.](#)



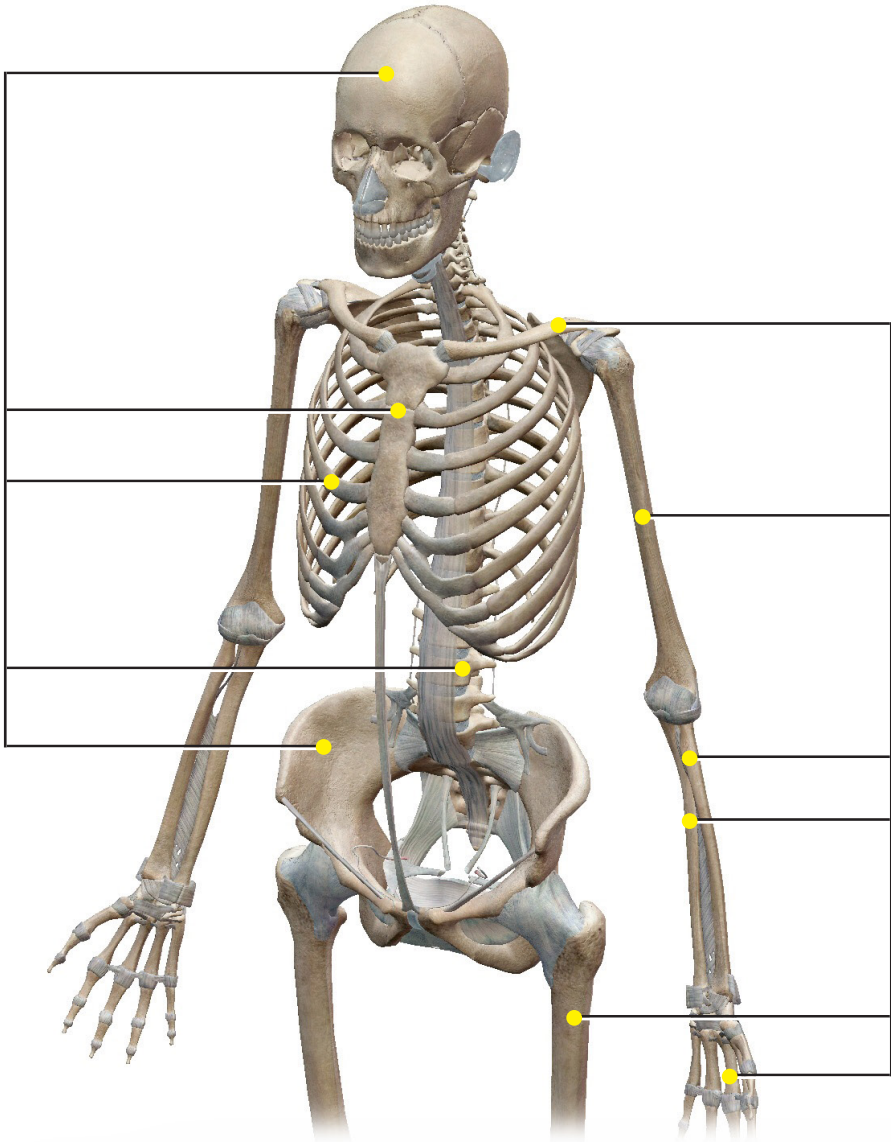
Student Practice

Label all the structures on the following images.

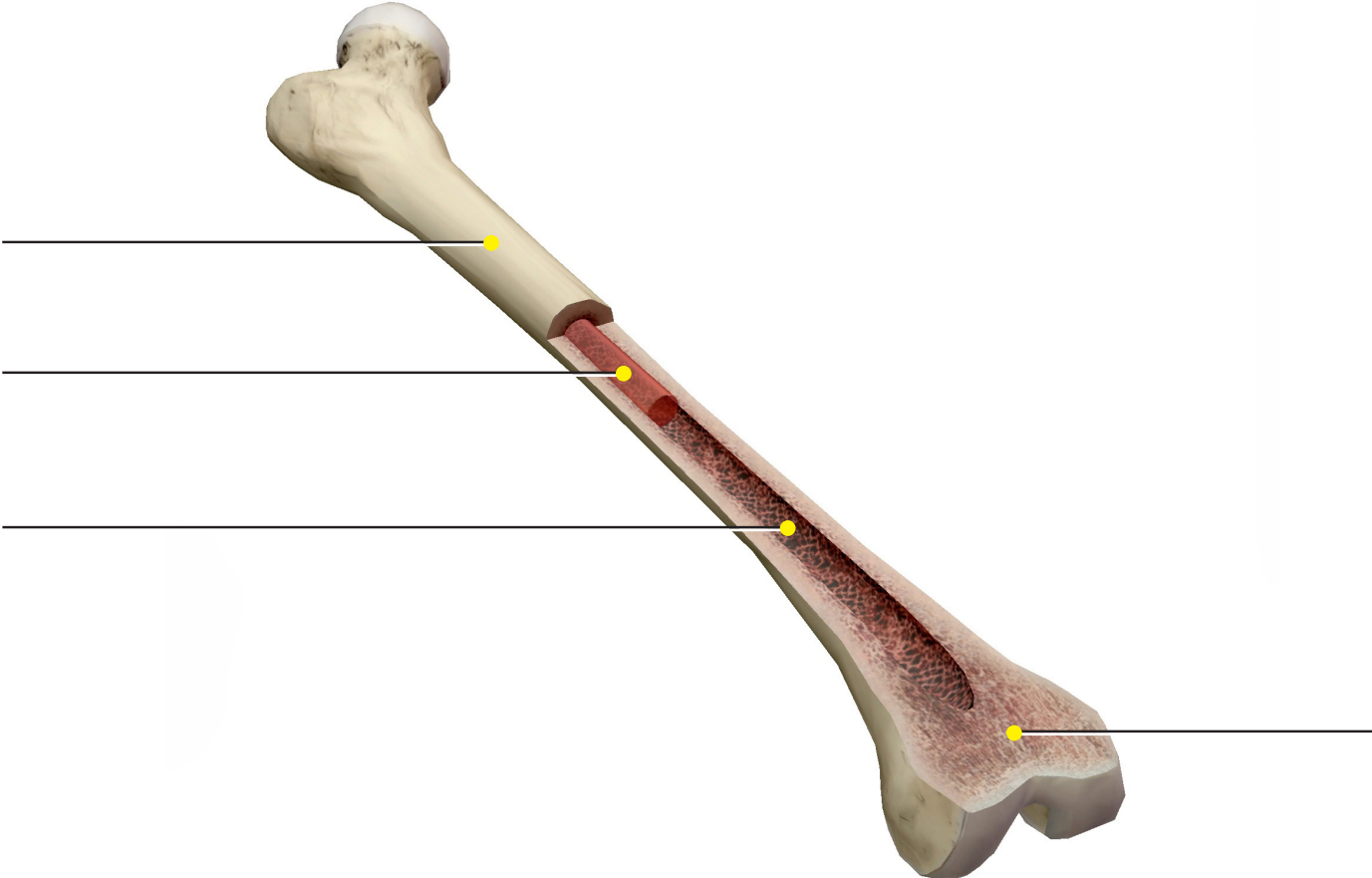
Module 7.3 Function of the Skeleton



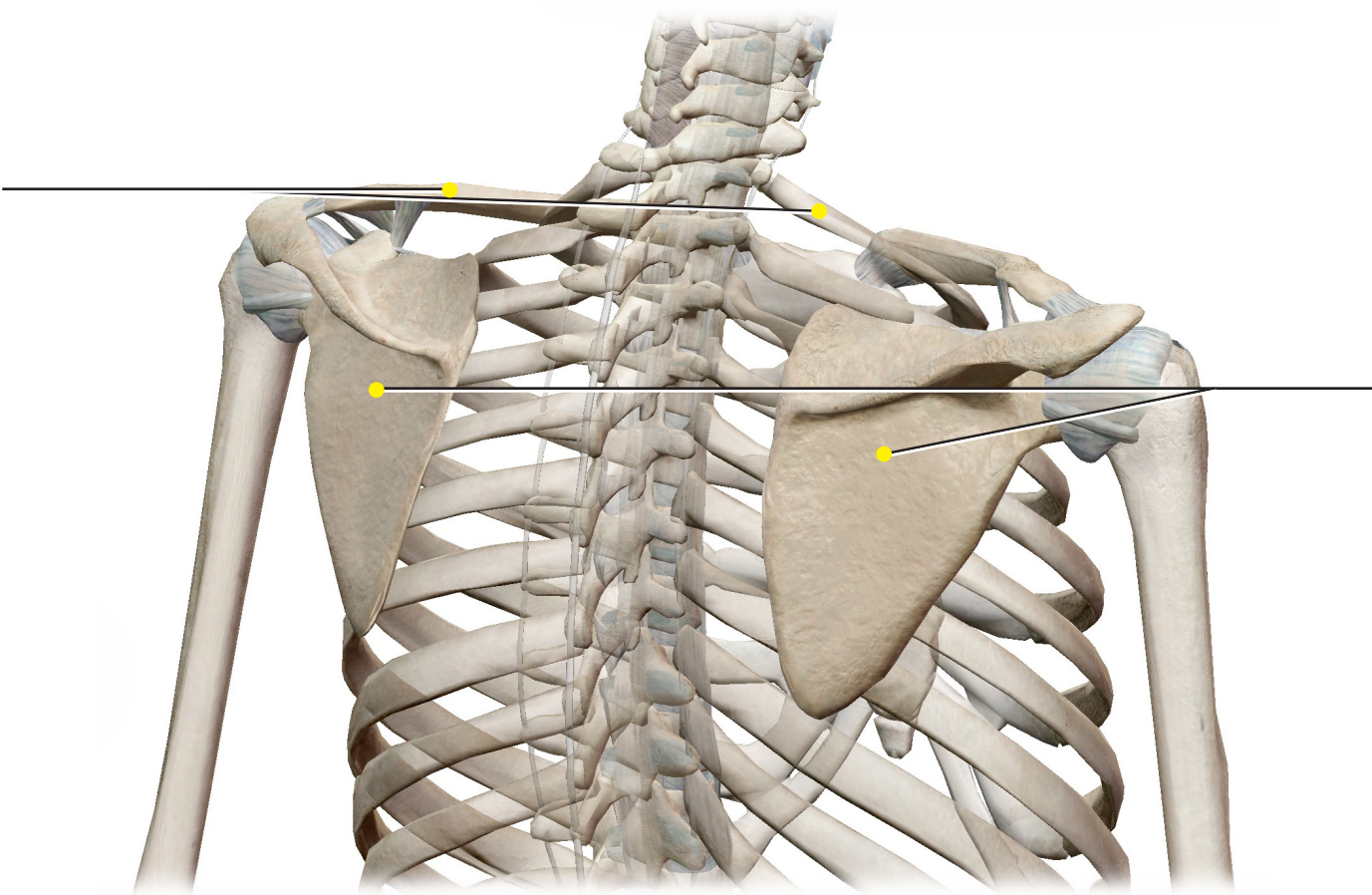
Module 9.1 Bone Marrow



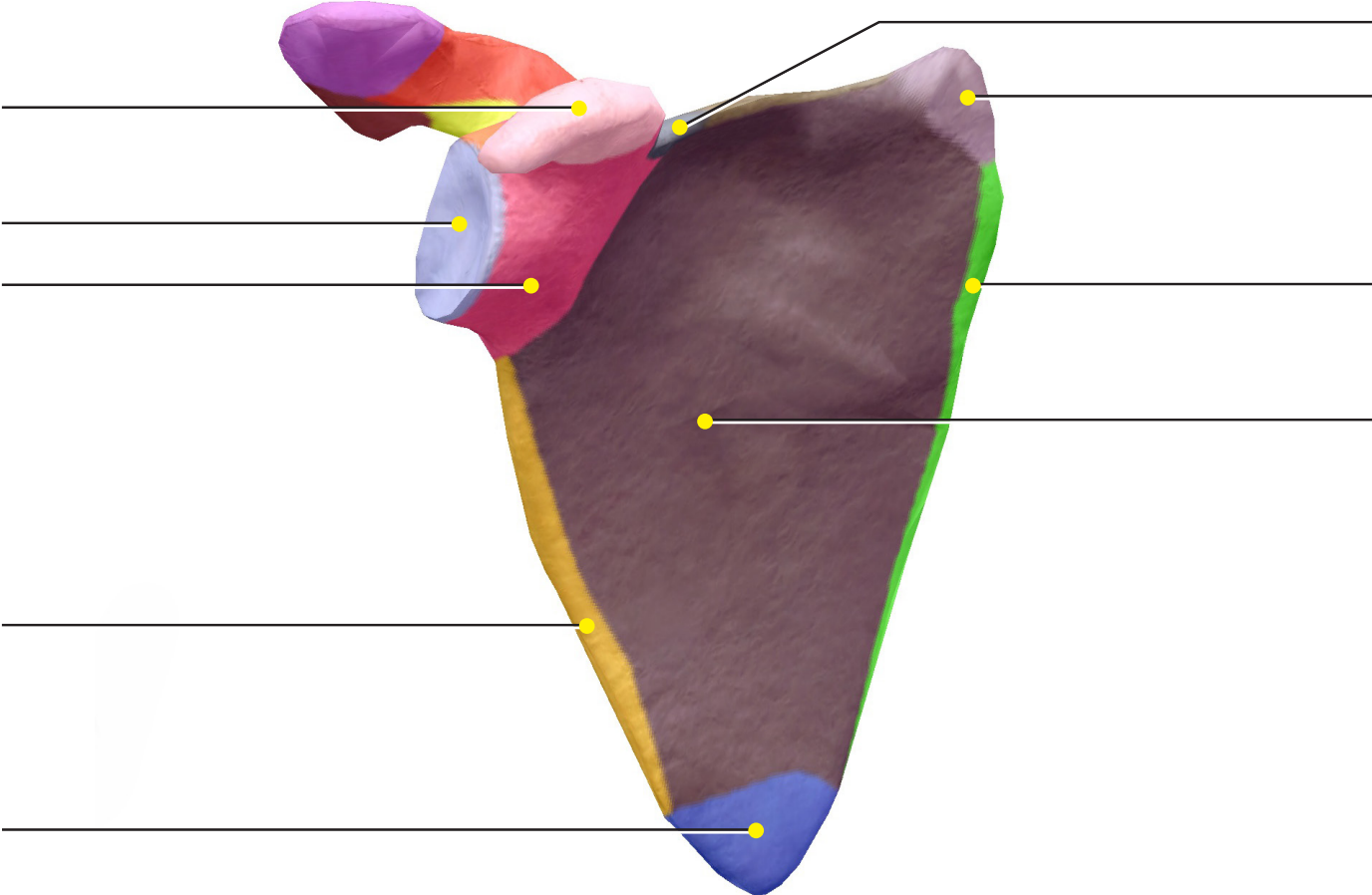
Module 9.2 Interior of a Long Bone



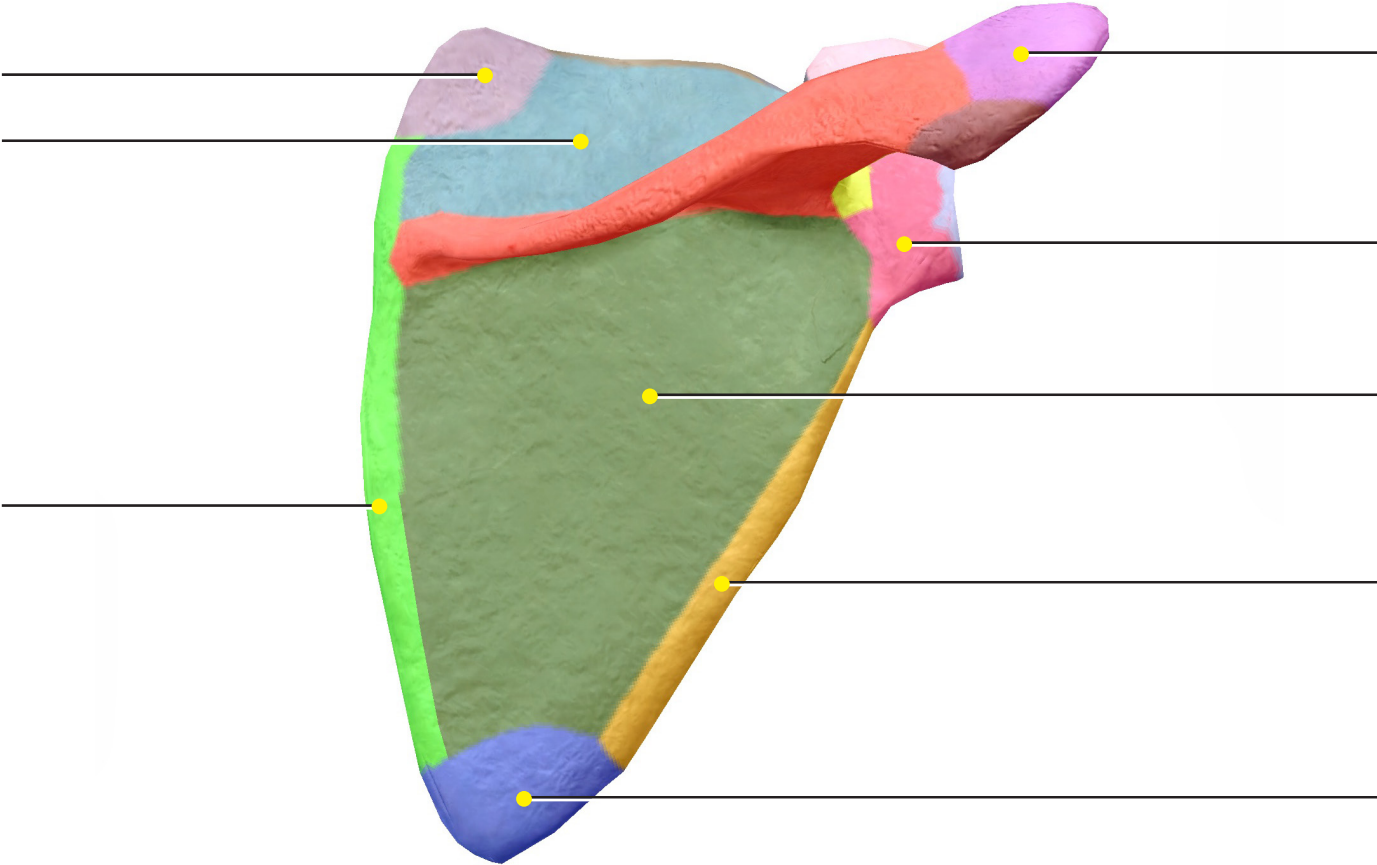
Module 11.2 Pectoral (Shoulder) Girdle



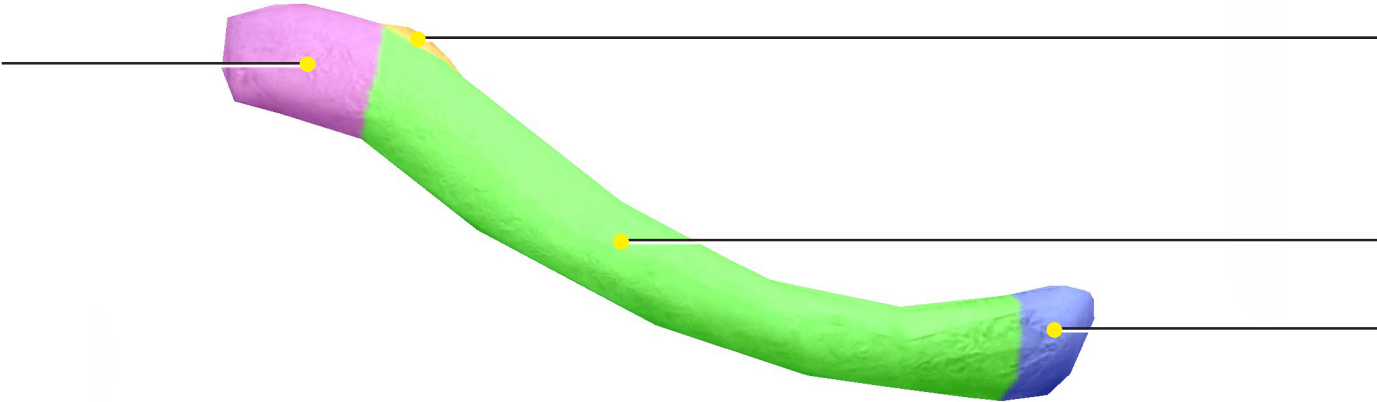
Module 11.3 Scapula Landmarks (Part 1)



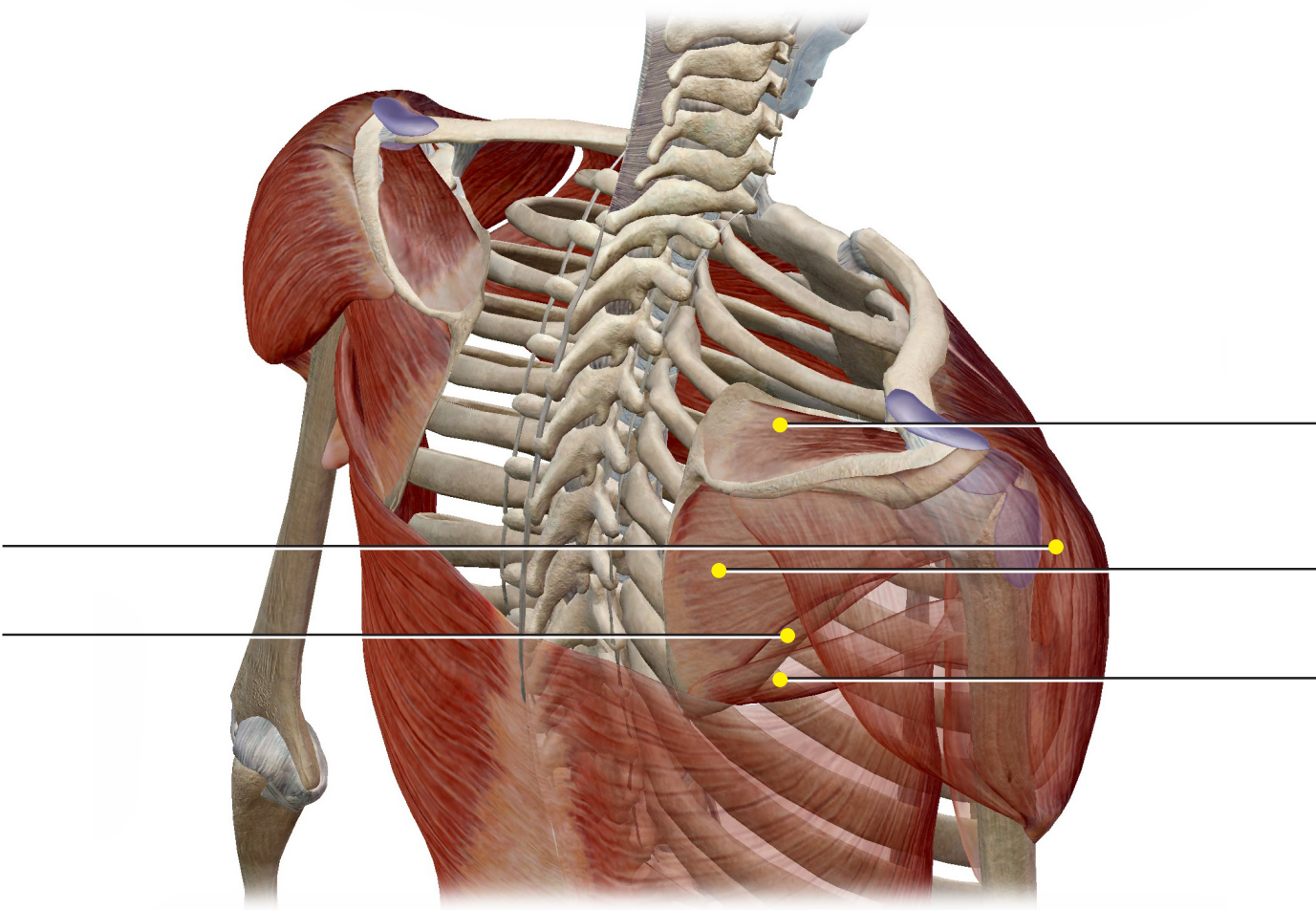
Module 11.3 Scapula Landmarks (Part 2)



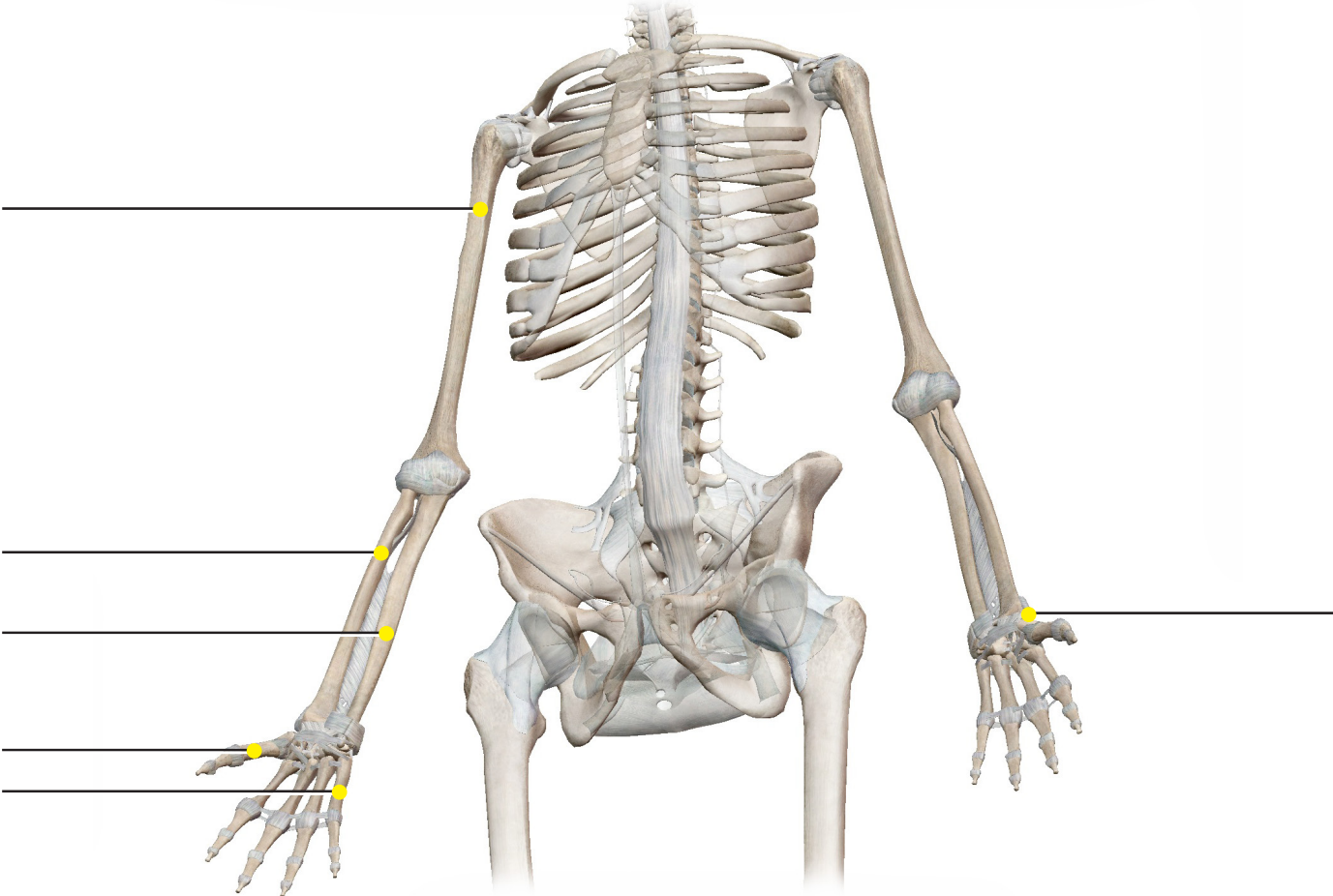
Module 11.4 Clavicle Landmarks



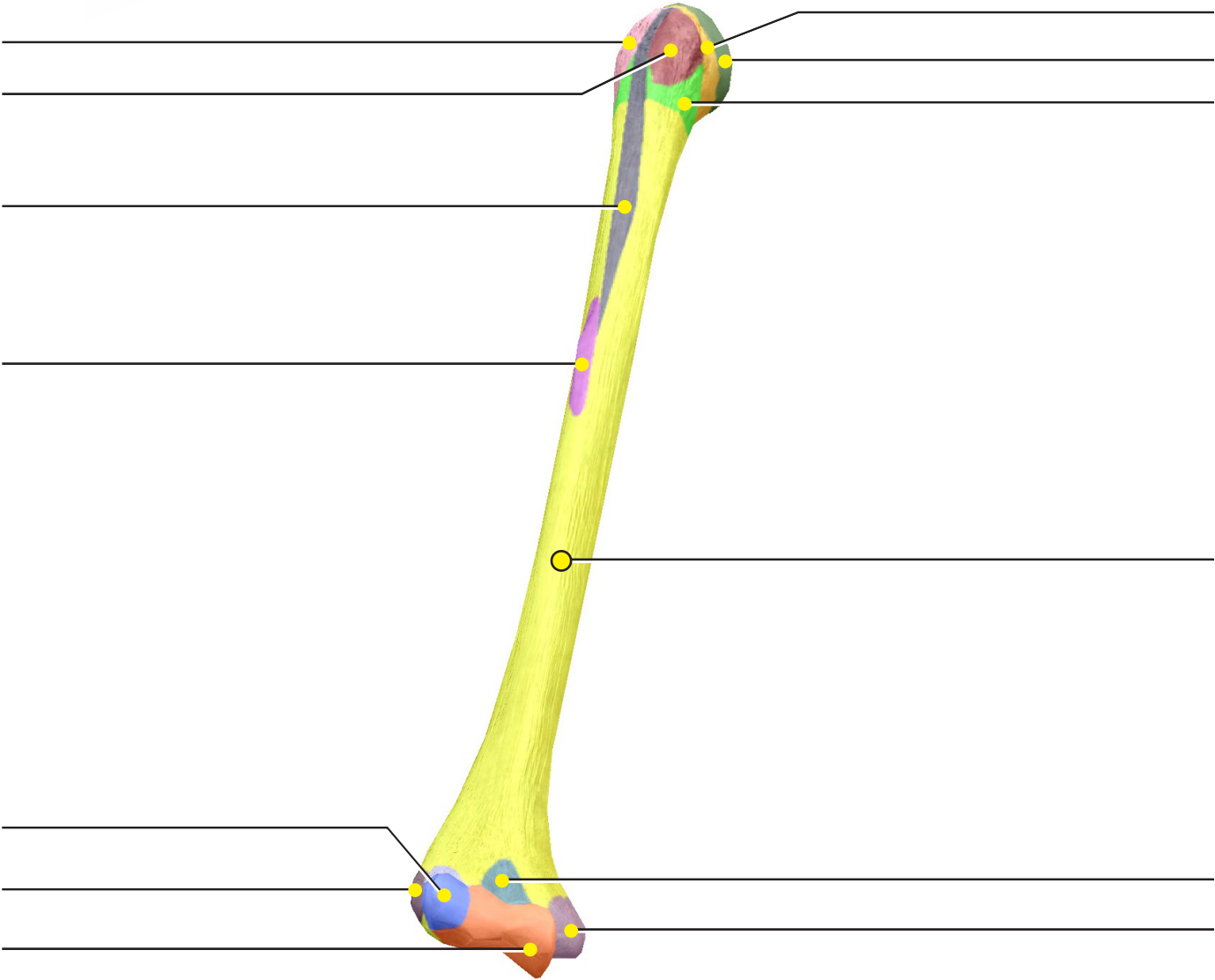
Module 11.5 Muscular Stabilization



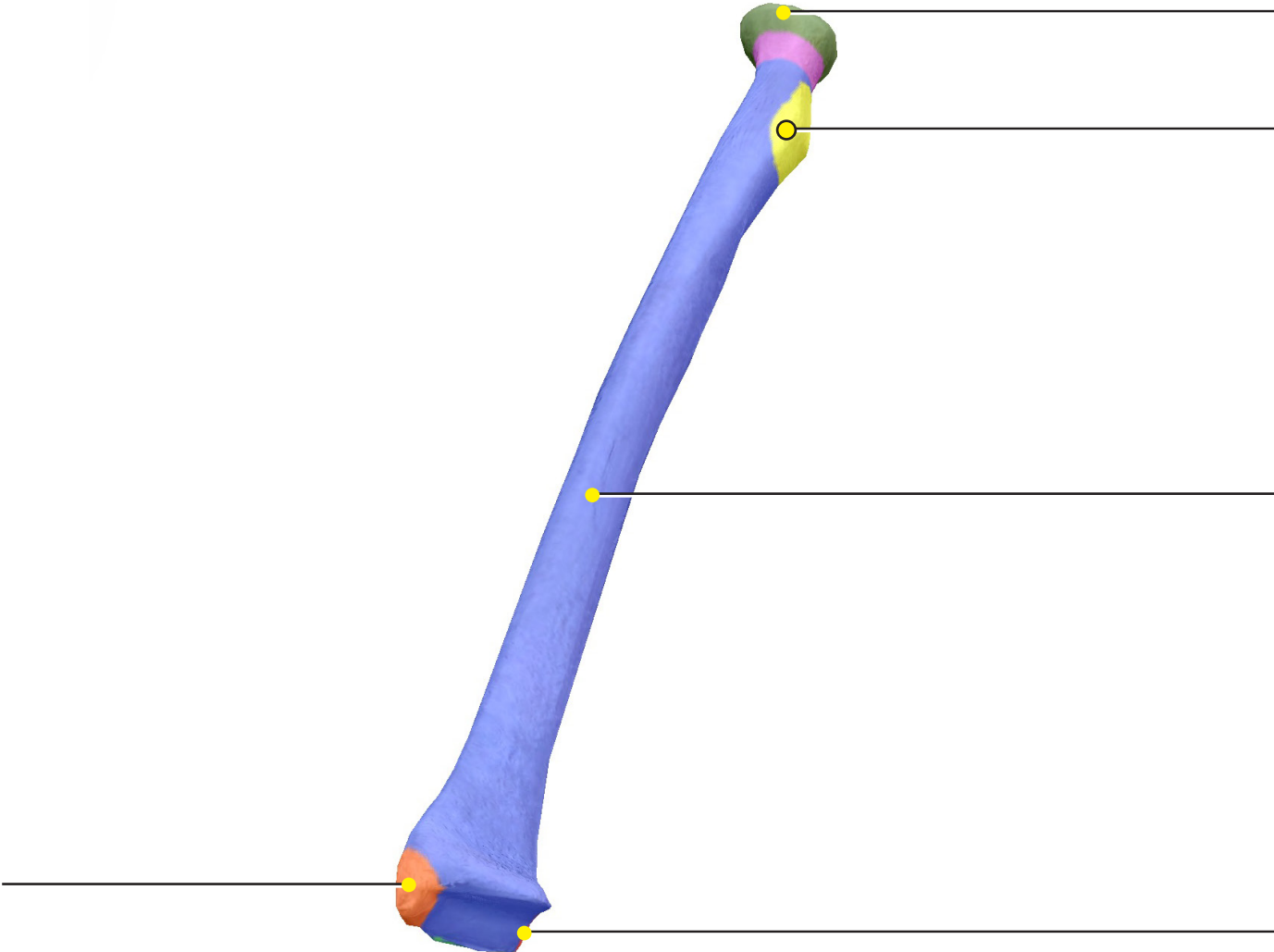
Module 11.6 Upper Limb



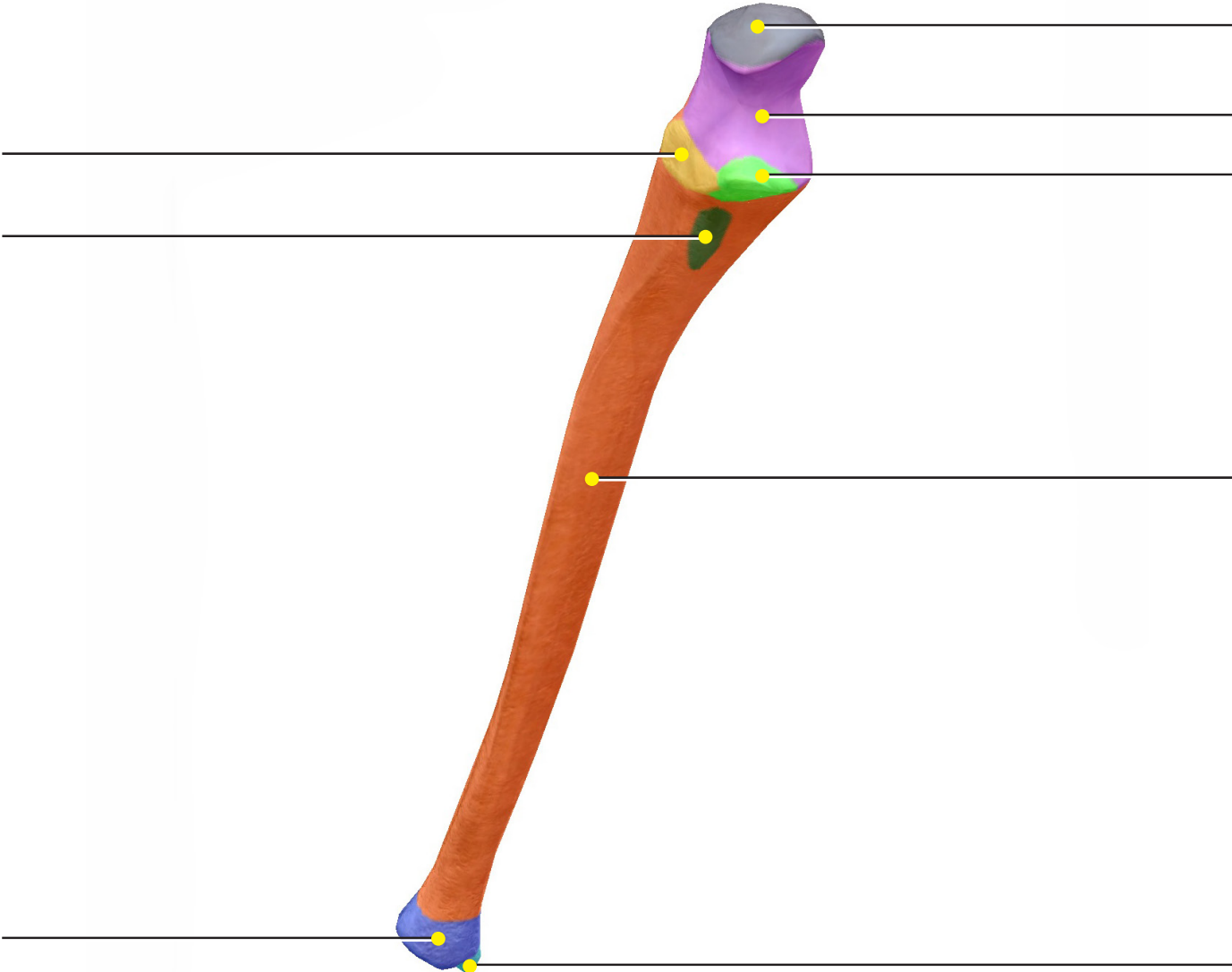
Module 11.8 Humerus Landmarks



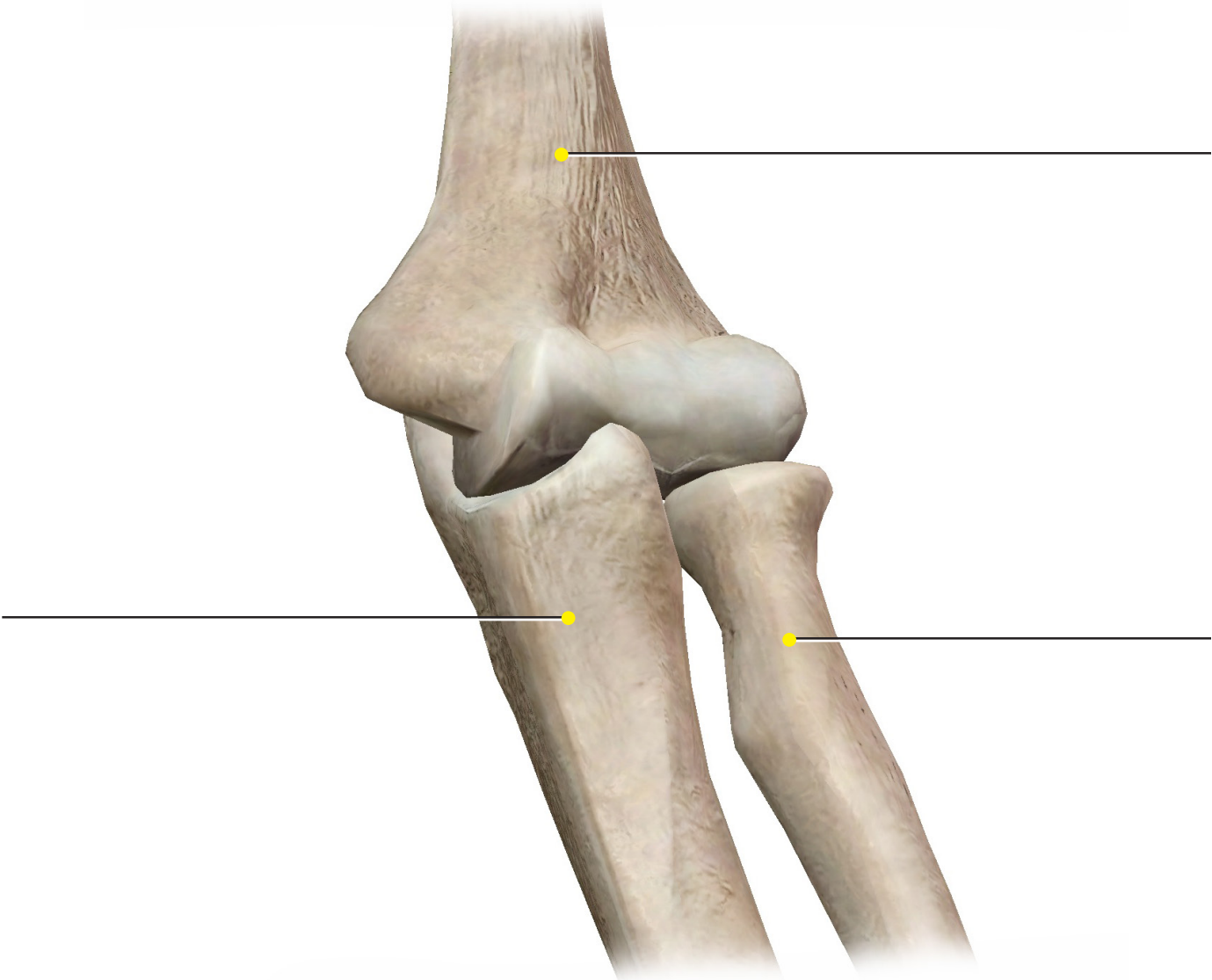
Module 11.9 Radius Landmarks



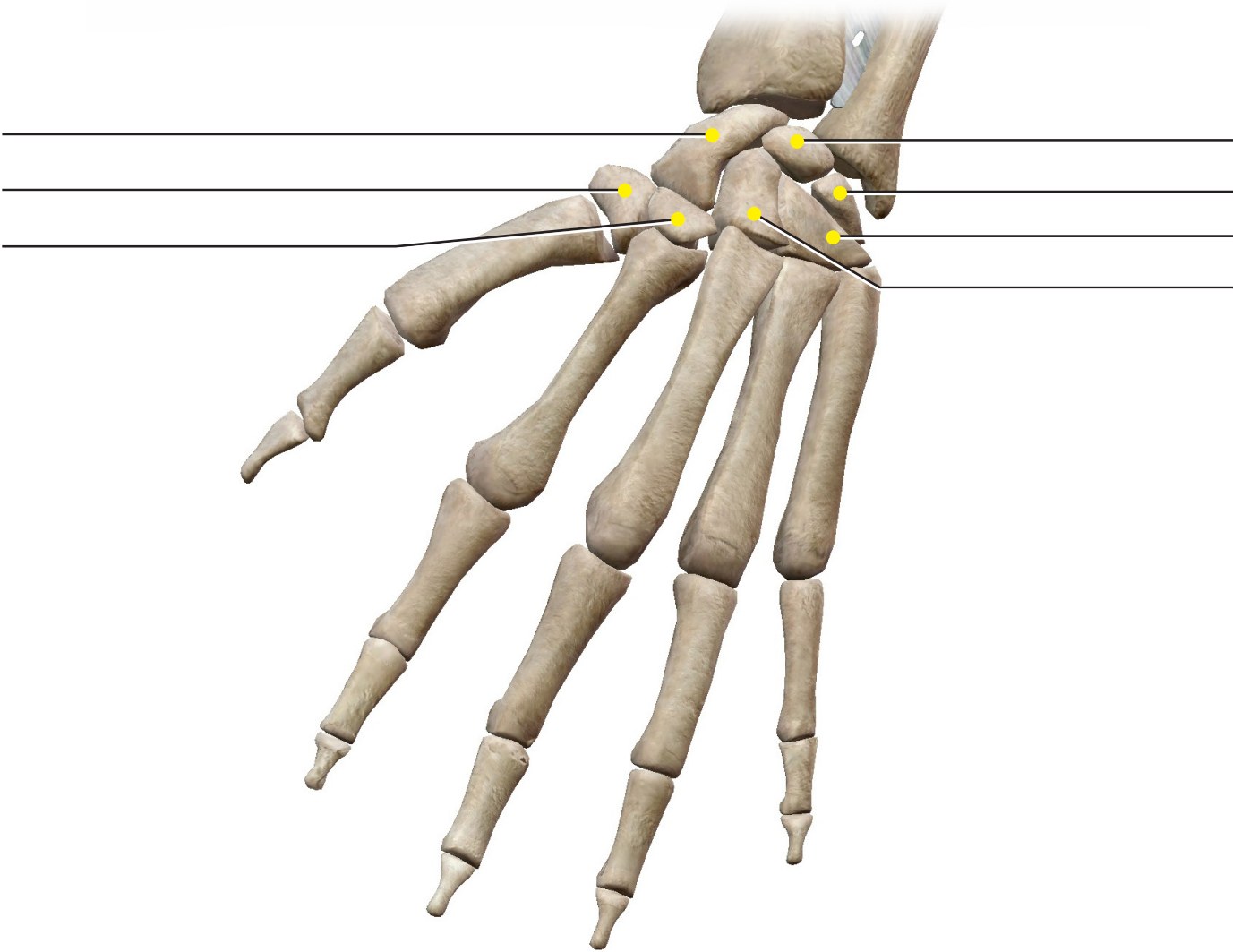
Module 11.10 Ulna Landmarks



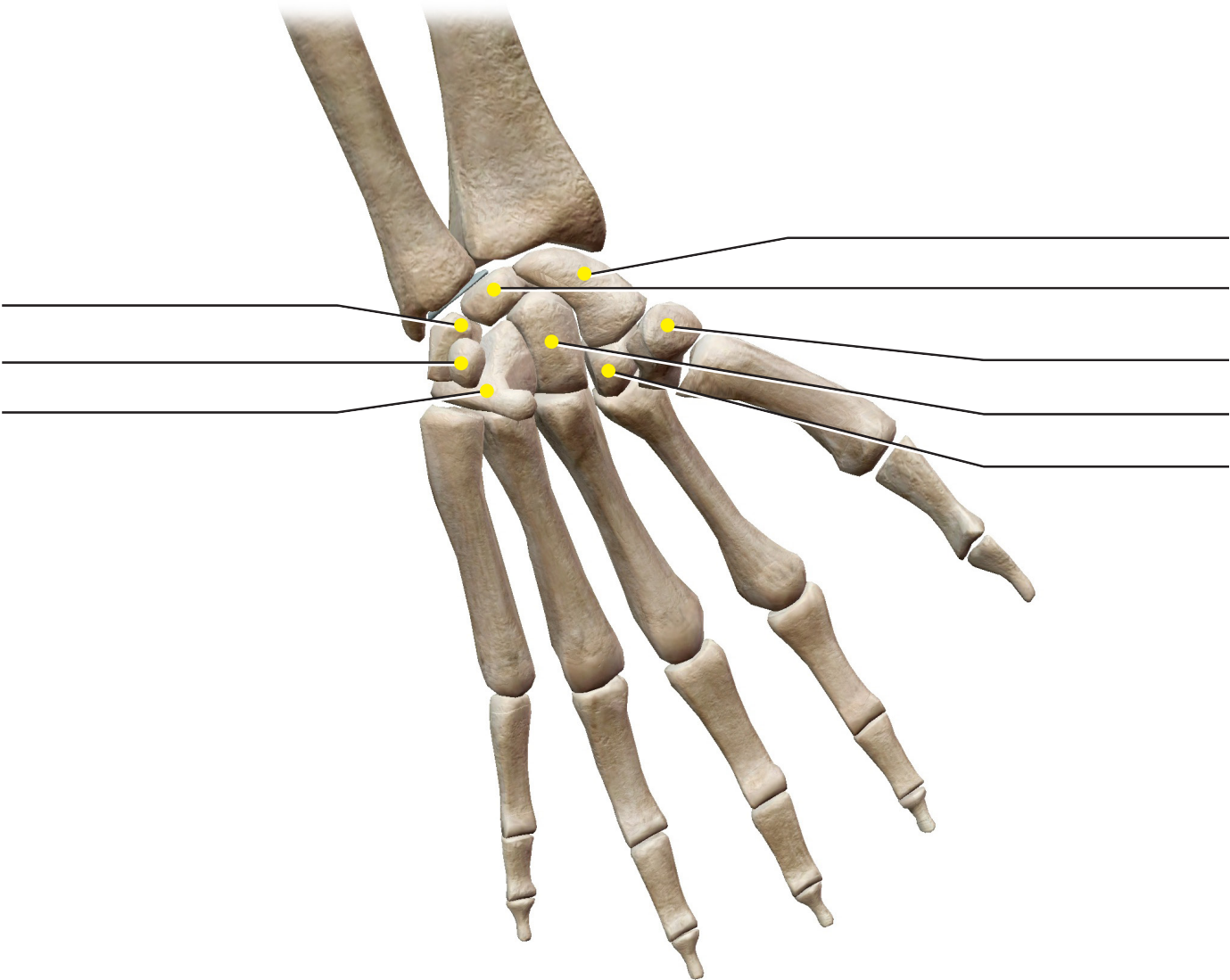
Module 11.11 Carpus (Wrist) I



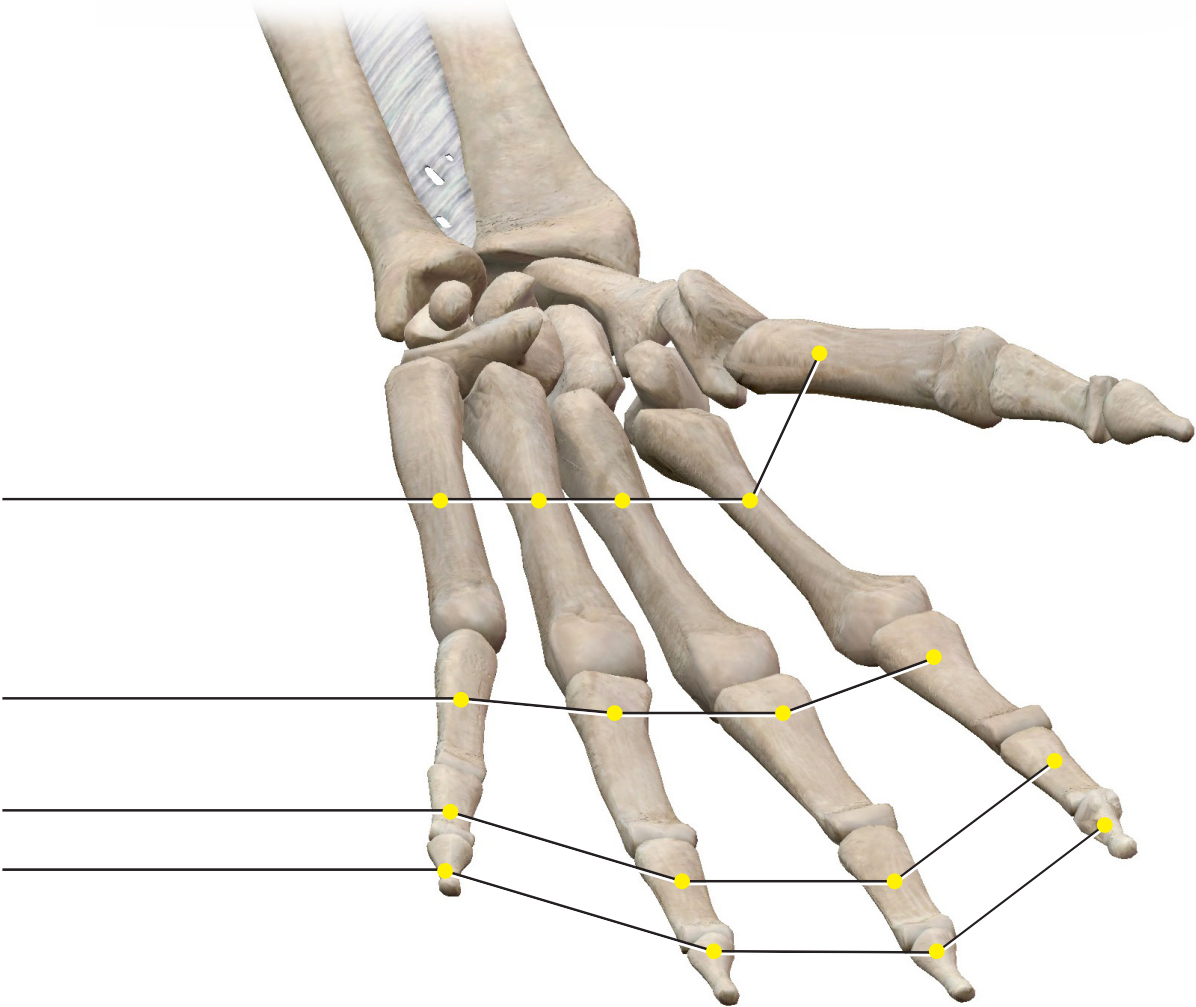
Module 11.12 Carpus (Wrist) II (Posterior)



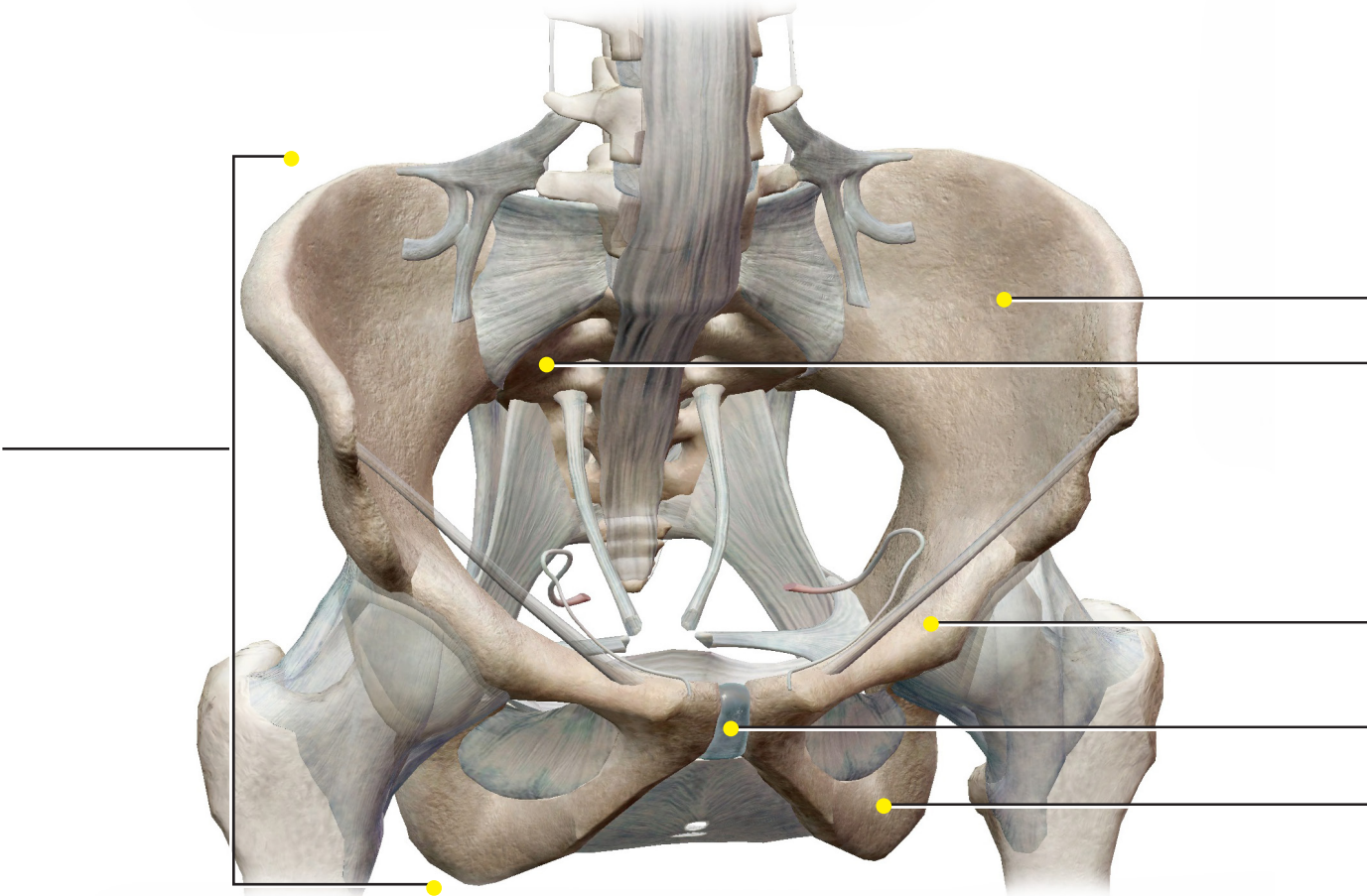
Module 11.12 Carpus (Wrist) II (Anterior)



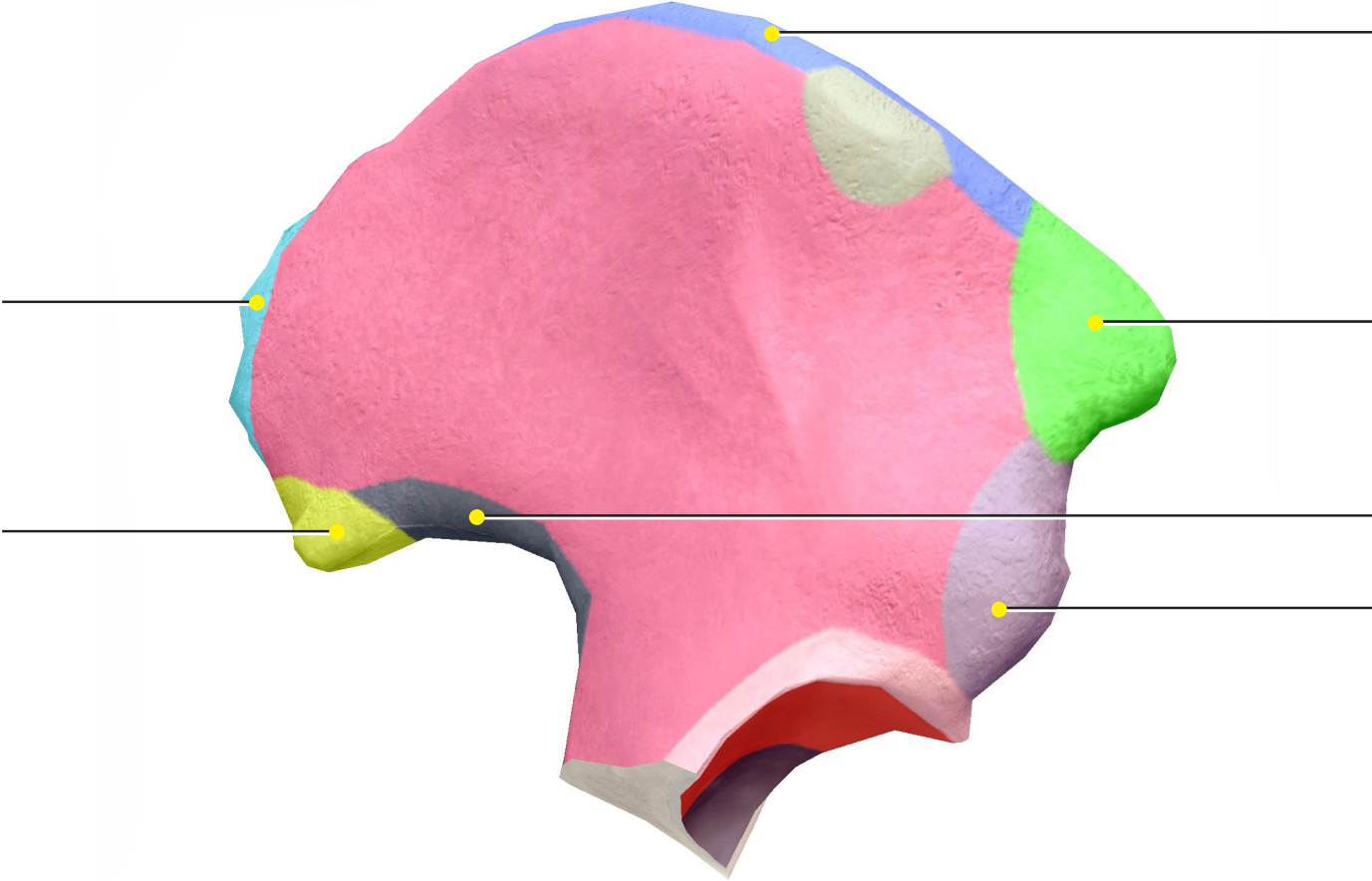
Module 11.14 Hand



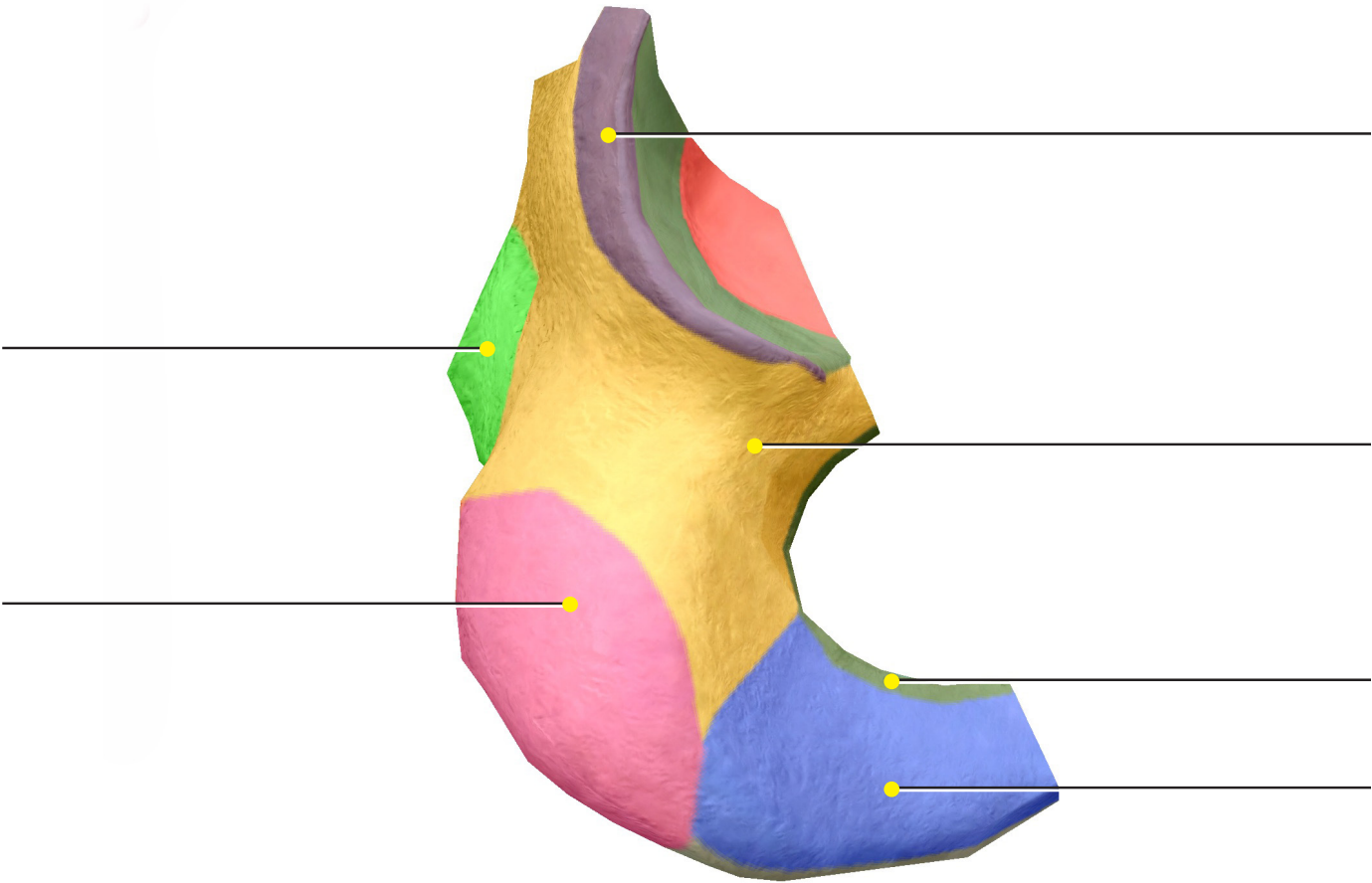
Module 11.15 Pelvic (Hip) Girdle



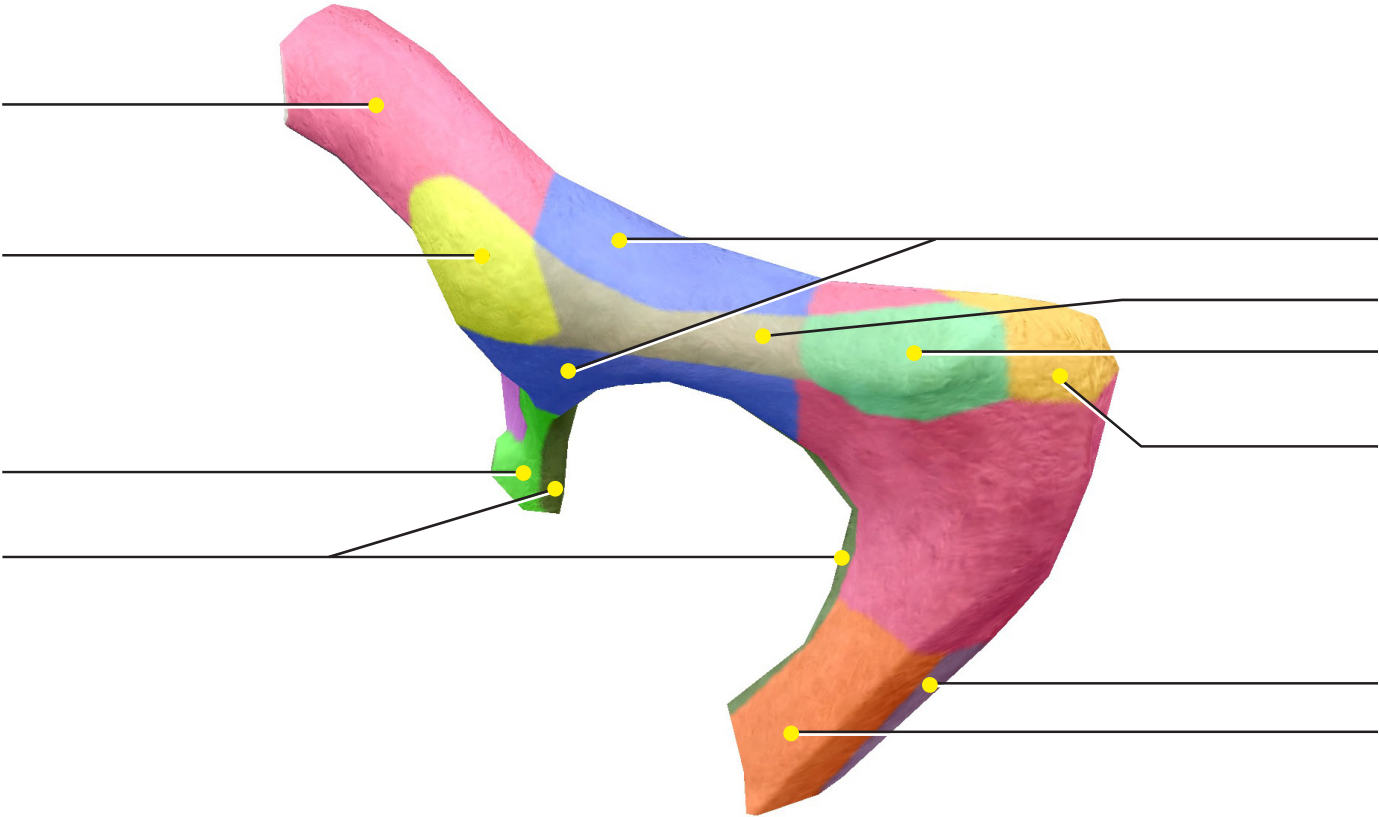
Module 11.16 Ilium Landmarks



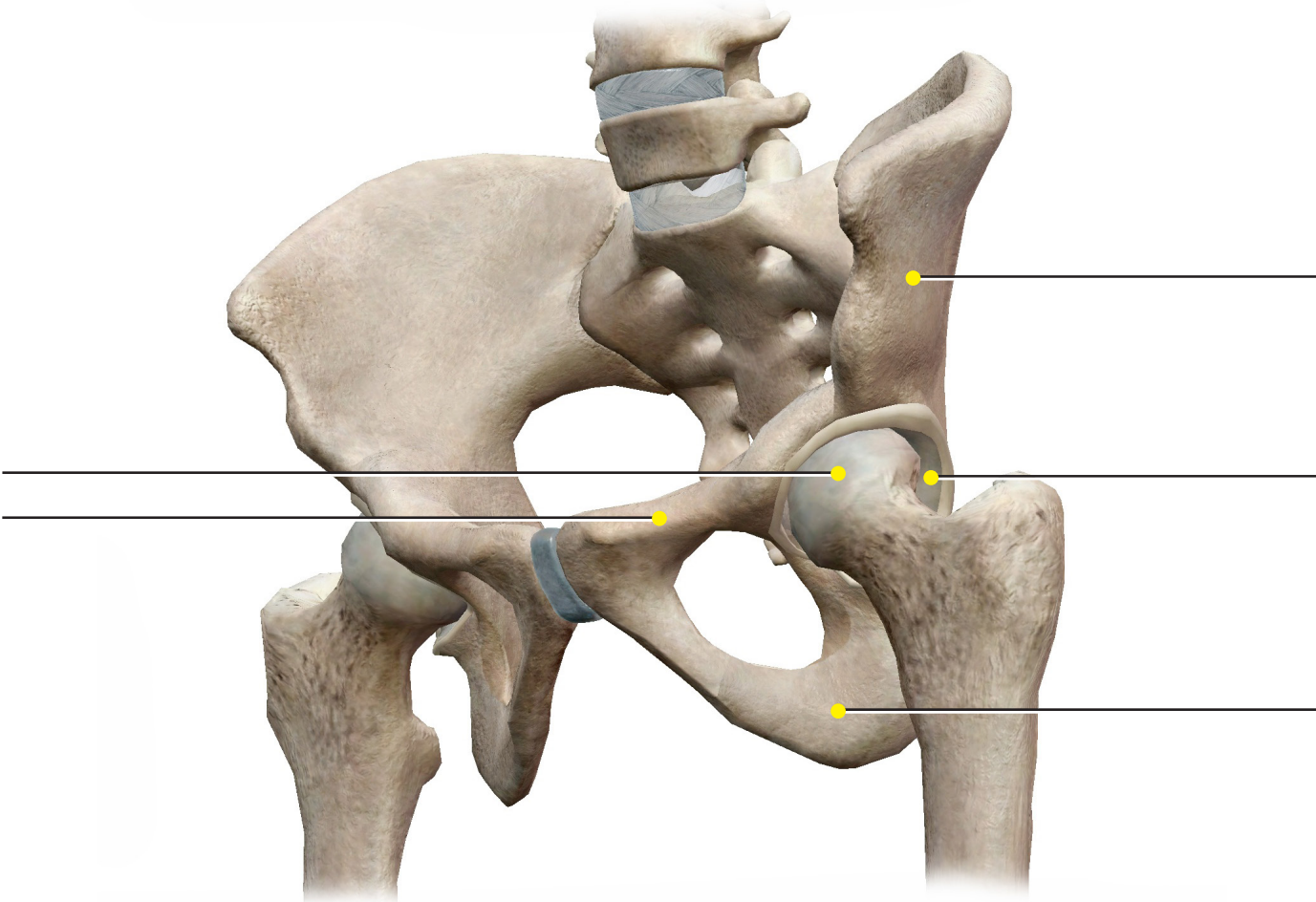
Module 11.17 Ischium Landmarks



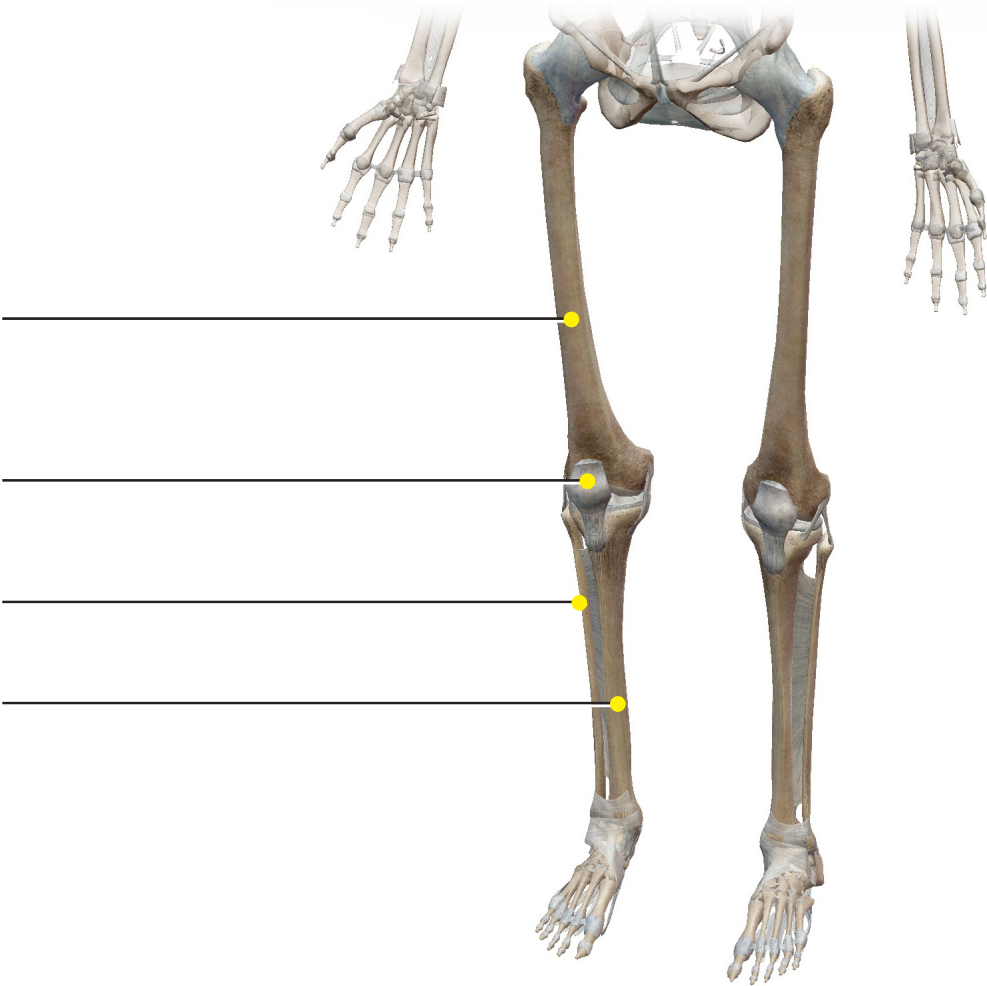
Module 11.18 Pubis Landmarks



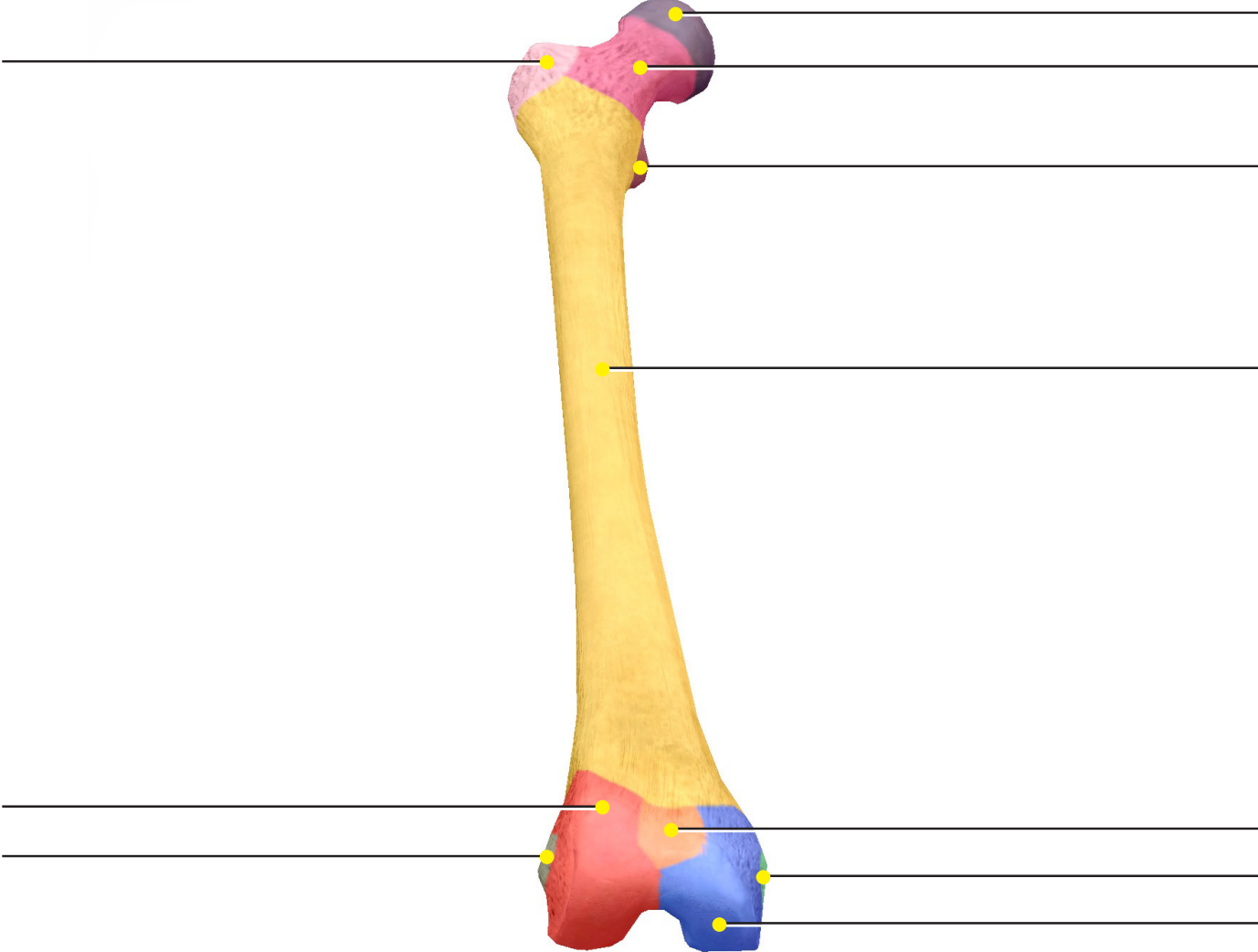
Module 11.15 Pelvic (Hip) Girdle



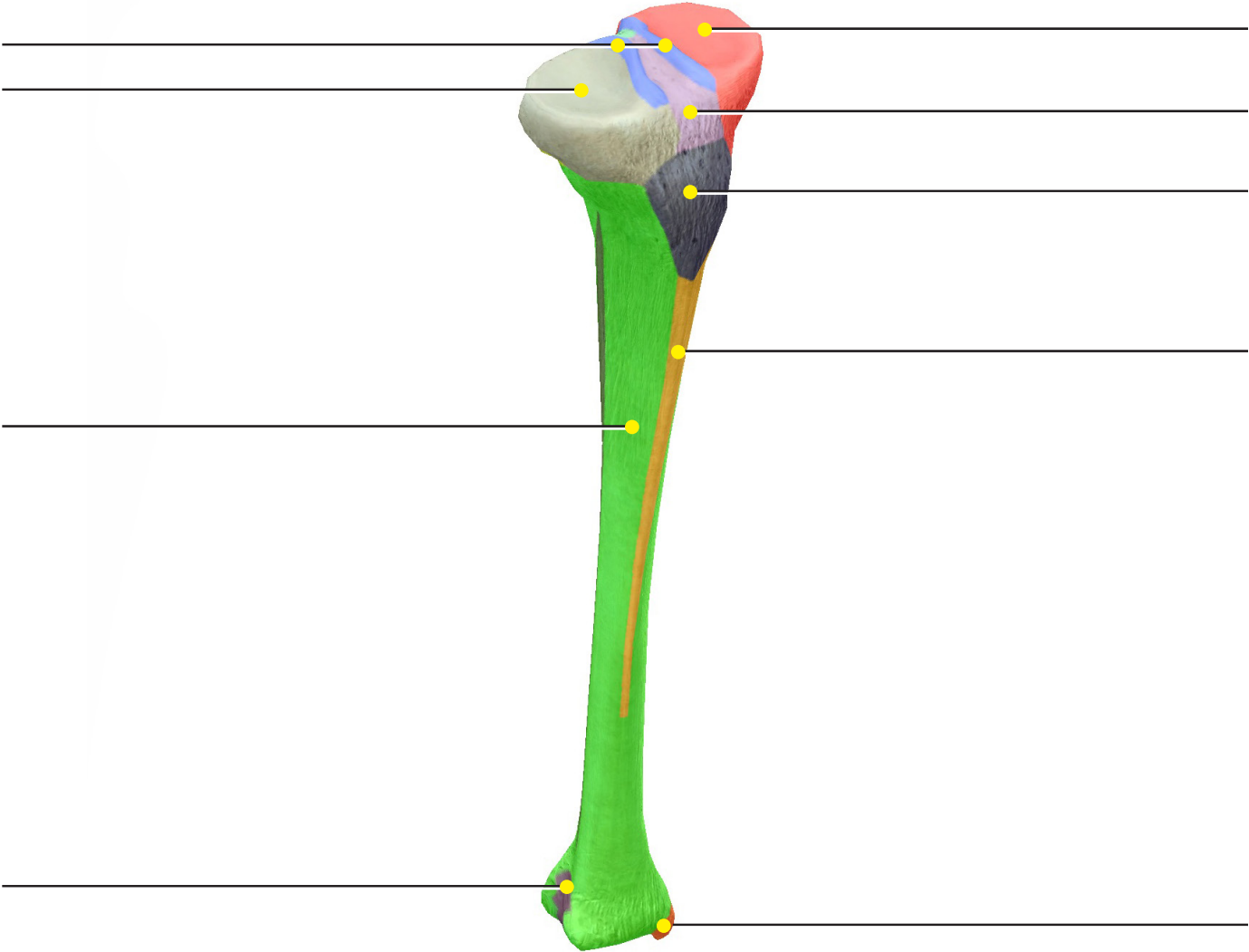
Module 11.20 Lower Limb



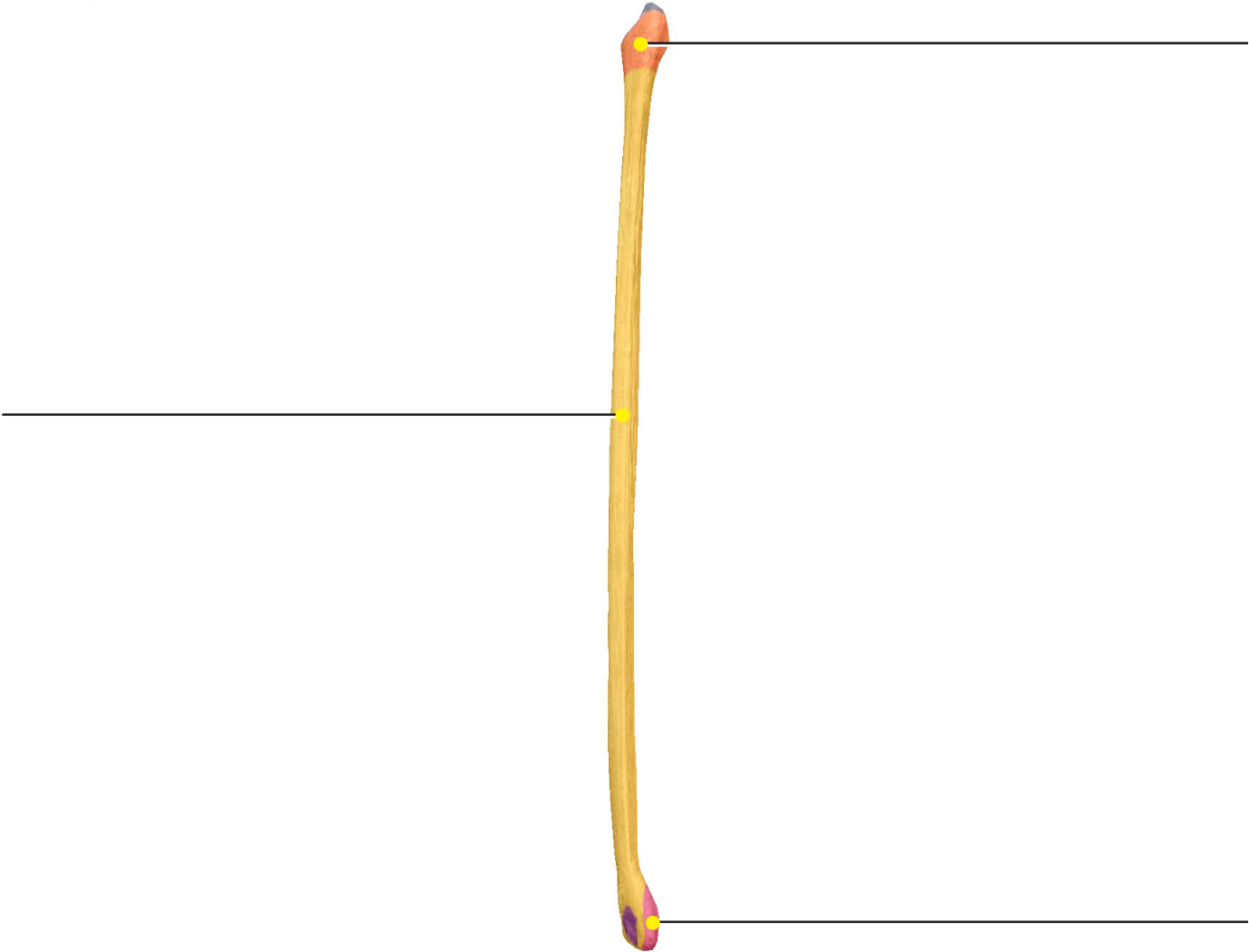
Module 11.22 Femur Landmarks



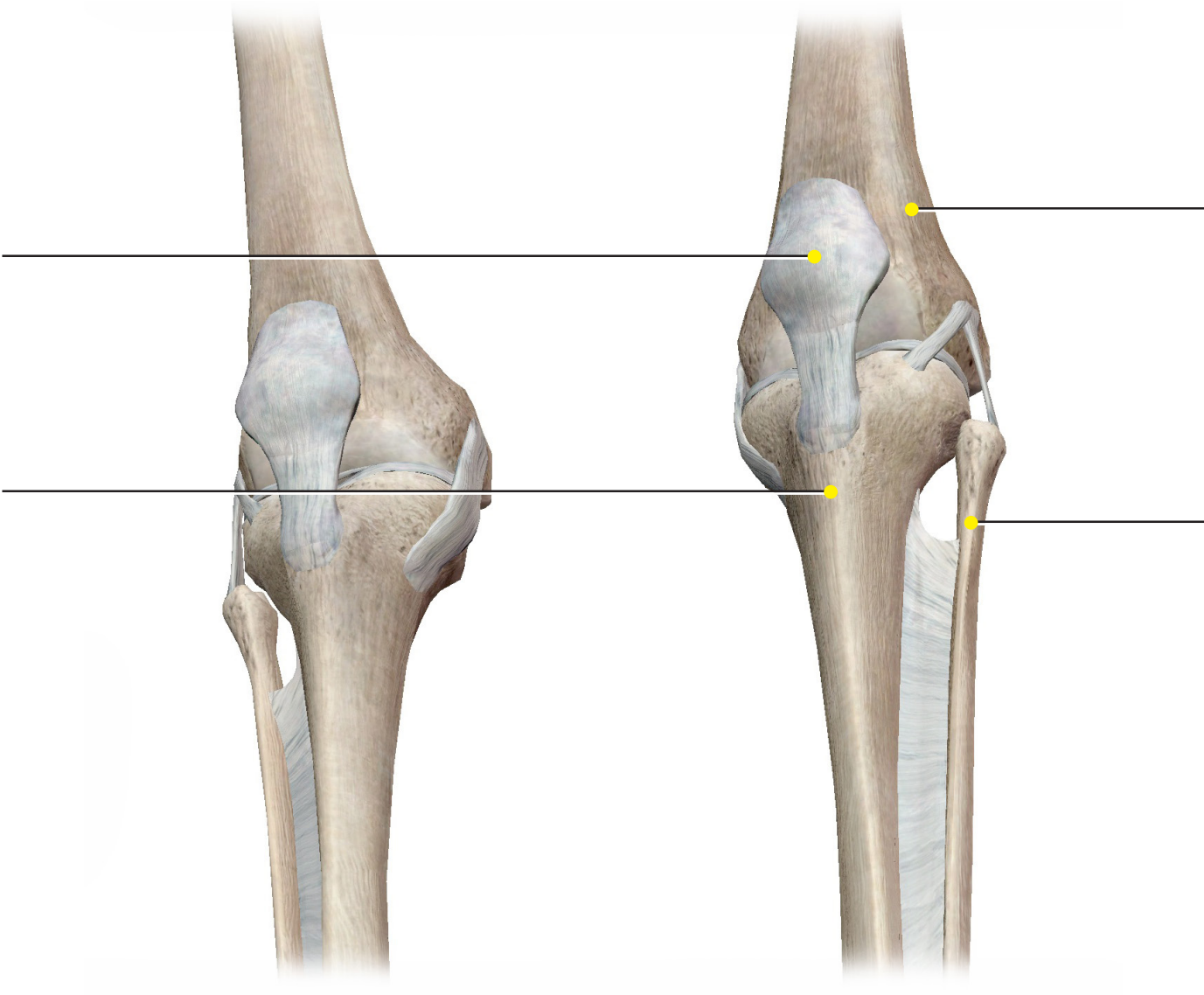
Module 11.23 Tibia Landmarks



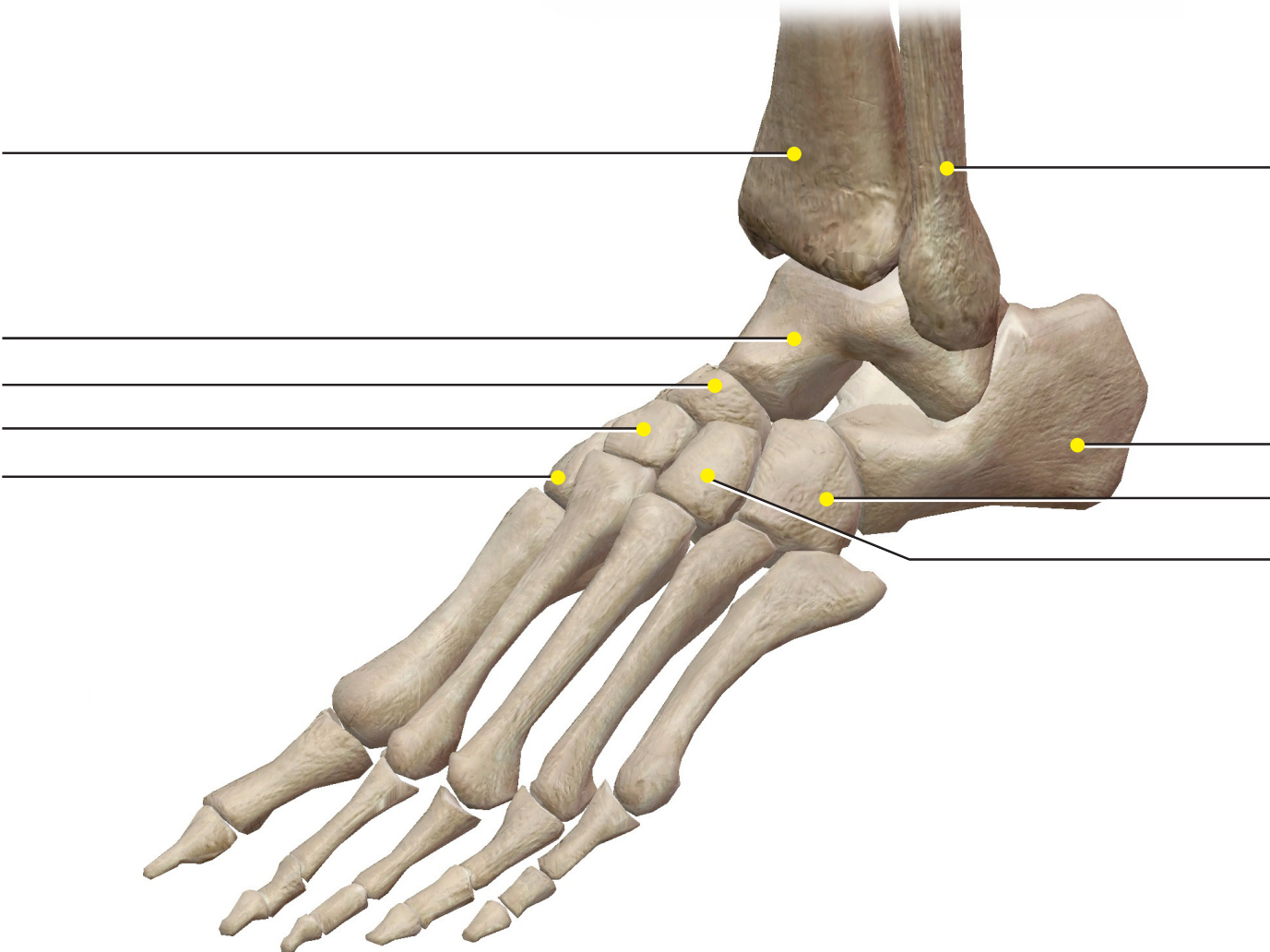
Module 11.24 Fibula Landmarks



Module 11.21 Thigh and Leg



Module 11.25 Tarsus



Module 11.27 Foot

